

Coexistence of Inflammatory Bowel Disease and Gastrointestinal Stromal Tumor: A Case Report

P Nikolaos, G Constantinos, R Demetra, P Christos, F Angeliki

Citation

P Nikolaos, G Constantinos, R Demetra, P Christos, F Angeliki. *Coexistence of Inflammatory Bowel Disease and Gastrointestinal Stromal Tumor: A Case Report*. The Internet Journal of Internal Medicine. 2003 Volume 4 Number 2.

Abstract

A 62-year-old female patient presented with fever and bloody diarrhea of 8 weeks duration. Clinical and laboratory findings indicated small bowel obstruction. Exploratory laparotomy revealed a gastrointestinal stromal tumor (GIST) of the terminal ileum. Postoperatively the colonoscopy revealed endoscopic and histologic findings of ulcerative colitis (UC).

The association of inflammatory bowel disease (IBD) and gastrointestinal adenocarcinoma is well known. Other primary intestinal tumors have rarely been reported and their relation to IBD is under consideration. Still, a rare coincidence cannot be excluded. This is the first case in the literature of a patient with UC and GIST.

INTRODUCTION

It is well known that patients with chronic IBD have a higher incidence of adenocarcinoma than the general population [1,2,3,4,5]. Other primary intestinal tumors observed in these patients are: lymphoma [6,7], carcinoids [8,9] and GIST, which are extremely rare; in fact only 4 cases have been brought to our knowledge, concerning Crohn disease and small bowel sarcoma [10,11,12,13]. Generally, all these tumors occurred in patients with a long history of IBD.

GIST accounts for 0,1–3% of gastrointestinal tumors and 10% of the small bowel tumors. Gastrointestinal autonomic nerve tumor (GANT) is a very uncommon type of GIST, which was first described by Herrera et al in 1984 [25]. Distinction of GANT from other stromal tumors is not possible only by imaging studies, and needs specific ultrastructural and immunohistochemical techniques.

We describe a patient with UC and clinical symptoms of bowel obstruction due to coexistence of GIST with neural differentiation of the terminal ileum. Since no case of GIST in association with UC has previously been reported, we believe that the case is worth reporting.

CASE REPORT

A non-smoker, 62-year-old female was admitted to our department with abdominal pain, 3-4 bloody diarrheas per day, weight loss, fatigue and fever of 8 weeks duration. Abdominal pain deteriorated, bloody diarrheas increased to 10-15 per day, and several vomits occurred, in the last 5

days. She mentioned appendectomy 7 years ago.

On admission she was febrile (38°C), cachectic with a pulse rate of 80/min and blood pressure 120/80 mmHg. Cardiopulmonary findings revealed no abnormalities and no lymph nodes were palpated. Abdominal examination revealed signs of incomplete bowel obstruction.

Initial laboratory studies showed: Anemia (Hb 7,2g/dl, Ht 22,4%, MCV 88fl), leukocytosis (WBC 21,4K/uL) with neutrophilia (88%), thrombocytosis (PLT 633 K/uL) and an elevated ESR (127mm/h). Alkaline phosphatase 300U/L (normal values 90-270U/L), LDH 397U/L (n.v 89-220U/L), SGOT 70U/L (n.v 9-48U/L), SGPT 24U/L (n.v 5-49U/L), γ-GT 12U/L, BUN 73mg/dl (n.v 10-50mg/dl), serum creatinine 1,2mg/dl (n.v 0,6-1,3mg/dl), bilirubin 0,8mg/dl, serum protein 5,5g/dl (n.v 6-8,3g/dl), albumin 3g/dl (n.v 3,5-5,3g/dl), potassium 2,9mmol/L, sodium 141mmol/L, calcium 7,9mg/dl, CRP 3,2mg/dl (n.v <0,8mg/dl), PT 12,4", APTT 38,7", INR 0,95, fibrinogen 757mg/dl (n.v 200-400mg/dl). Urinalysis revealed 10-15 WBCs and urine culture revealed E.Coli >100000cfu/ml. Mayer stool test was positive (3 times), stool analysis revealed plenty of WBCs and no ova or parasites, stool cultures and blood cultures were all negative (3 times); C.difficile toxin negative; Widal test negative; PPD (purified protein derivative) skin test negative; ECG: LAH; CXR normal; Abdomen x-ray showed fluid levels of the small bowel.

Gastroscopy revealed hiatal hernia. Barium enema

examination indicated a filling defect at the ileocecal valve compatible with small bowel obstruction. Abdominal CT scan identified wall thickening of the descending colon and fluid levels of the small bowel.

Obstructive symptoms persisted, the patient's general condition deteriorated and an exploratory laparotomy was performed. Adhesive bands and a tumor of 2,2cm in diameter, 50cm from the ileocecal valve at the terminal ileum were found. A complete surgical resection of the tumor with the adjacent mesentery and adhesive bands followed.

Histopathology revealed that the tumor diffusely infiltrated all layers of the bowel. The mitotic activity was 0 mitosis per 10 high-power fields (0/10HPF).

Immunohistochemically, tumor cells had a positive reaction to vimentin, protein

S-100 (fig. 1) and CD117 (polyclonal c-kit antibody) (fig. 2). No reaction was found with muscle-specific actin (SMA), desmin and keratin LMW. The tumor was classified as GIST with neural differentiation because of the vimentin and protein

S-100 expression, but no electron microscopic analysis performed to establish the diagnosis of GANT, which is a rare type of GIST [14,15,16,17,18]. Because of its size, and the absence of mitotic activity or metastasis, the tumor was classified as low risk. [18,19,20].

Figure 1

Figure 1: GIST: S-100 protein expression by tumor cell (ABC X 200).

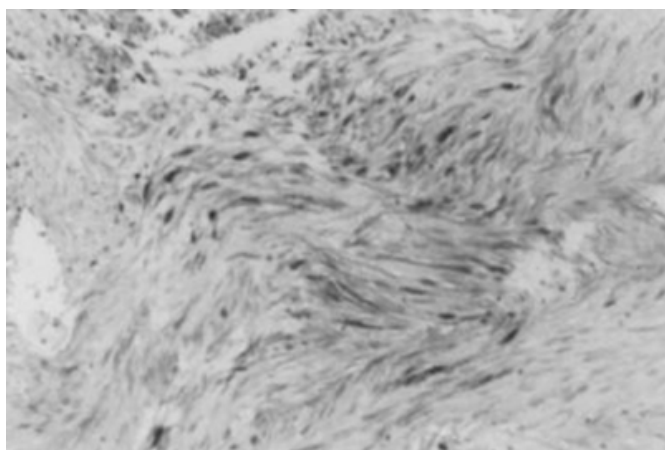
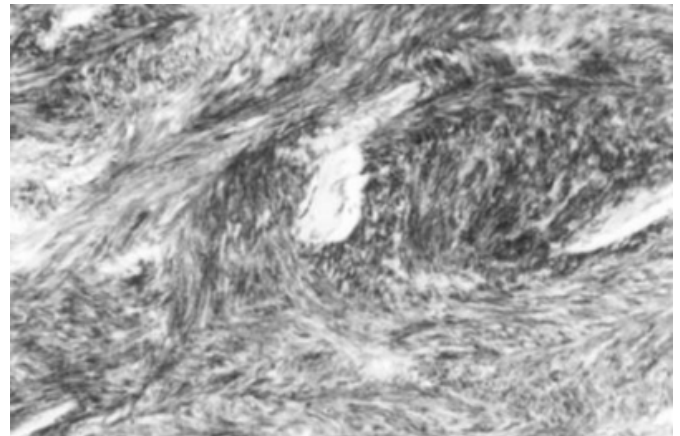


Figure 2

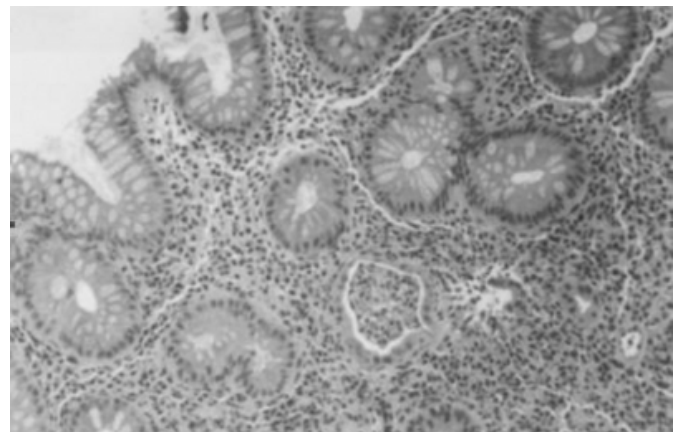
Figure 2: GIST: c-kit (CD117) expression by tumor cells (ABC X 200).



Fever and bloody diarrheas persisted until the 7th postoperative day. Colonoscopy up to the ascending colon demonstrated pancolitis, with loss of mucosal vascularity, diffuse erythema, friability of the mucosa, superficial ulcers and exudates consisting of mucus, blood and pus, in a continuous pattern. Three biopsies during endoscopic examination from the affected areas were compatible with UC (fig. 3). Physical, laboratory and endoscopy findings were, also, compatible with UC.

Figure 3

Figure 3: Biopsy of large intestine: Histological finding compatible with ulcerative colitis [H+E X 200].



Treatment was started with glucocorticoids, metronidazole and later sulfasalazine. The patient responded to the above treatment and laboratory findings returned to normal values. She was discharged 10 days later, without symptoms on sulfasalazine 1,2 gr/d treatment.

Since the tumor was classified as low risk no systemic chemotherapy was given.

The patient is free of symptoms 24 months after discharge.

DISCUSSION

Patients with chronic IBD have a higher incidence of adenocarcinoma than the general population, especially those who have pancolitis and those with disease of long duration. For patients with pancolitis, the risk of cancer has been estimated to be 40% at 25 years [1,2]. GIST account for approximately 0,1 to 3% of all gastrointestinal neoplasms, with 150 new cases per year diagnosed in the United States from which 37,5% are GANT [22]. Revising data on literature indicated that the mean age of patients is 58,5 years [23]. GIST are mostly located at the stomach (53%), the small intestine (33%), rectum (5%), esophagus (5%) and colon (4%). The most frequent diagnostic test is spiral CT and endoscopic ultrasound. The most frequent clinical manifestations are gastrointestinal bleeding, a palpable mass and mild abdominal pain. Bowel obstruction is rarely the presenting sign, and usually follows the onset of other clinical symptoms. Male sex, tumor size >5cm, mitotic activity >1/10HPF, incomplete resection and liver metastasis have been recognized as significant predictors of poor prognosis. Patients with complete resection had a 54% 5 year survival rate [19, 23, 24]. Treatment of patients with high risk GIST (>5cm and/or >2HPF) includes in addition to resection, chemotherapy with STI-571 [19, 21].

Small bowel sarcomas (SBS), including GIST/GANT, have rarely been reported in association with IBD. To our knowledge 4 other cases of GIST have been described in association with IBD (Crohn's disease) involving the same intestinal segment [10,11,12,13]. In most of these cases, patients had a long history of Crohn's disease prior to the development of malignancy. Our patient's age and the anatomic location of the tumor were as in previous reports, but the diagnosis of stromal tumor was established shortly after the onset of clinical symptoms of UC and without previous history of IBD. This short interval between the onset of IBD symptoms and the presence of this tumor has been described in one [12] of the 4 other cases mentioned before. The finding of the tumor and adhesive bands were unexpected for us. Both of them may be considered as the cause of obstruction. Our case was classified as GIST and represents, to our knowledge, the first report in coexistence with UC. Histologic examination for UC usually shows an inflammatory infiltrate consistent with acute colitis with polymorphonuclear cells and background findings of chronic inflammation, like cryptitis and crypt abscesses. None of these features is specific for UC. In our patient, endoscopic

findings, as well as, history and clinical evolution under specific treatment, confirmed the diagnosis of UC. In our case the tumor was located 50cm from the ileocecal valve while UC affected the colon. Consequently, although a causal connection between these two diseases cannot be excluded, a mere coexistence is more than possible.

However, this report should remind that patients with IBD are at increased risk for developing neoplasia and this coexistence makes the diagnosis of the tumor very difficult because many of the initial signs of the neoplasm such as bleeding, are hard to evaluate in the setting of colitis.

CORRESPONDENCE TO

M. Alexadrou 28, Korydallos, Athens, Greece, zip code: 181-20. (N. Papadopoulos) E-Mail:npnck7@ath.forthnet.gr

References

1. Ransoff DF: Colon cancer in ulcerative colitis. *Gastroenterology* 1998; 94:1089.
2. Ekblom A, Helmick C, Zack M, Adami H: Ulcerative colitis and colorectal cancer. *N Engl J Med* 1990; 323:1228.
3. Sugita A, Sachar DB, Bodian C, Ribeiro MB, Aufses AH, Greenstein AS: Colorectal cancer in ulcerative Colitis: Influence of anatomic extent and age at onset in colitis-cancer interval. *Gut* 1991; 32:169.
4. Greenstein AJ, Sugita A, Yamazaki Y: Cancer in inflammatory bowel disease. *Jpn J Surg* 1989; 19:633-644.
5. Lennard-Jones JE, Melville DM, Morson BC, Ritchie JK, Williams CB: Precancer and cancer in extensive ulcerative colitis: Findings among 401 patients over 22 years. *Gut* 1990; 31:800-806.
6. Williamson RCN, Welch CE, Malt RA: Adenocarcinoma and lymphoma of the small intestine. *Ann Surg* 1983; 197:172-177.
7. Sheperd NA, Hall PA, Williams GT, Codling BW, Jones EL, Levison DA, Morson BC: Primary malignant lymphoma of the large intestine complicating chronic inflammatory bowel disease. *Histopathology* 1989; 15:325-337.
8. Wood WJ, Archer R, Schaefer JW, Stephens C, Griffen WO: Coexistence of regional enteritis and carcinoid tumor. *Gastroenterology* 1970; 59:265-269.
9. Kortbeek J, Kelly JK, Presaw RM: Carcinoid tumors and inflammatory bowel disease. *J Surg Oncol* 1992; 49:122-126.
10. Stahl TJ, Schoetz DJ, Roberts PL, Collier JA, Murray JJ, Silverman MC, Veidenheimer MC: Crohn's disease and carcinoma: Increased justification for surveillance? *Dis Colon Rectum* 1992; 35:850-856.
11. Dikman SH, Toker C: Enteroblastoma complicating regional enteritis. *Gastroenterology* 1973; 65:462-466.
12. Pfeffel F, Stiglbauer W, Depisch D, Oberhuber G, Raderer M, Scheithauer W: Coincidence of Crohn's disease and a high-risk gastrointestinal stromal tumor of the terminal ileum. *Digestion* 1999; 60:363-366.
13. Laukhuf F, Tischer KH, Strobel K, Wietholtz H : Crohn's disease and stromal sarcoma of the small bowel- a rare coincidence. *Zeitschrift fur Gastroenterologie* 2002; 40(3):193-6.
14. Erlandson RA, Klimstra DS, Woodruff JM: Subclassification of gastrointestinal stromal tumors based on evaluation by electron microscopy and

- immunohistochemistry. *Ultrastruct Pathol* 1996; 20:373-393.
15. Tazawa K, Tsukada K, Makuuchi H, Tsutsumi Y: An immunohistochemical and clinicopathological study of gastrointestinal stromal tumors. *Pathol Int* 1999; 49: 786-98.
16. Chan JK. Mesenchymal tumors of the gastrointestinal tract: a paradise for acronyms (STUMP, GIST, GANT, and now GI-PACT), implications of c-kit in genesis, and yet another of the many emerging roles of the interstitial cell of Cajal in the pathogenesis of gastrointestinal disease? *Adv Anath Pathol* 1999; 6:19-40.
17. Seidal T, Edvardsson H: Expression of c-kit (CD117) and Ki67 provides information about the possible cell of origin and clinical course of gastrointestinal stromal tumors. *Histopathology* 1999; 34:416-24.
18. Franquemont DW: Differentiation and risk assessment of gastrointestinal stromal tumors. *Am J Clin Pathol* 1995; 103:41-47.
19. Berman JJ, O'Leary TJ: Gastrointestinal stromal tumor work group. *Human Pathology* 2001; 32:578-582.
20. James R Howe, Lucy H Karnell, and Carol Scott-Conner: Small Bowel Sarcoma: analysis of survival from the national cancer database. *Annals of surgical Oncology* 8 (6): 496-508, 2001
21. Joensuu H, Roberts PJ, Sarlomo-Rikala M, Andersson LC, Tervahartiala P, Tuveson D, Silberman SL, Capdeville R, Dimitrijevic S, Druker B, Demetri GD: Brief Report: Effect of the Tyrosine Kinase Inhibitor STI571 in a patient with a metastatic gastrointestinal stromal tumor. *N Engl J Med* 2001; 344:1052-1056.
22. Licht JD, Weissmann LB, Antman K: Gastrointestinal sarcomas. *Semin Oncol* 1988; 15:181-188.
23. Yao KA, Talamonti MS, Langella RL, Schindler NM, Rao S, Small W Jr, Joehl RJ: Primary gastrointestinal sarcomas: analysis of prognostic factors and results of surgical management. *Surg* 2000; 128: 604-612.
24. DeMatteo RP, Lewis JJ, Leung D, Mudan SS, Woodruff JM, Brennan MF: Two hundred gastrointestinal stromal tumors: recurrence patterns and prognostic factors for survival. *Ann Surg* 2000; 231: 51-8.
25. Herrera GA, PintoDM, Grizzle WE, Han SG. Malignant small bowel neoplasm of enteric plexus derivation (plexosarcoma). Light and electron microscopic study confirming the origin of the neoplasm. *Digestive Diseases & Sciences* 1984; 29: 275-84.2.

Author Information

Papadopoulos Nikolaos

Department of Internal Medicine, General Regional Hospital "Sotiria"

Goritsas Constantinos

Department of Internal Medicine, General Regional Hospital "Sotiria"

Rontogianni Demetra

Department of Clinical Pathology, General Regional Hospital "Evangelismos"

Papamihail Christos

Department of Internal Medicine, General Regional Hospital "Sotiria"

Ferti Angeliki

Department of Internal Medicine, General Regional Hospital "Sotiria"