

# Abdomen Quiz

P Chugar

## Citation

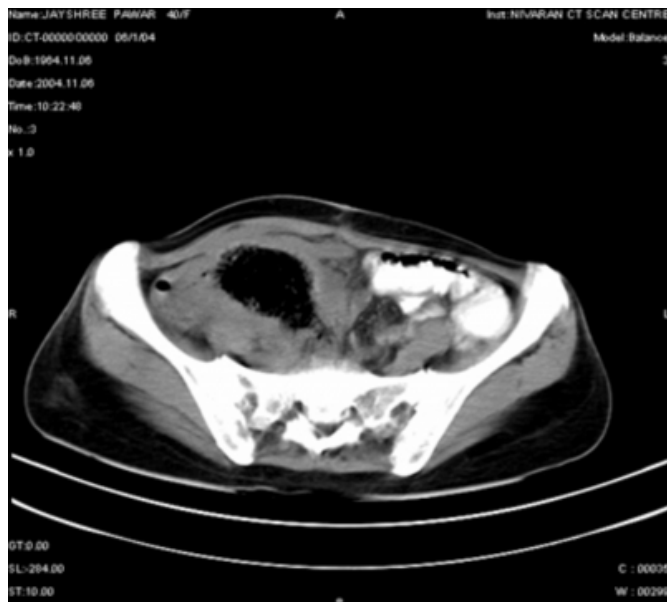
P Chugar. *Abdomen Quiz*. The Internet Journal of Radiology. 2007 Volume 8 Number 2.

## Abstract

38 year old lady presented with history of chronic right iliac fossa pain and vomiting. She was operated for appendicectomy 3 months back.

Image:

**Figure 1**



## DIAGNOSIS

GOSSYPIBIOMA

## DISCUSSION

Gossypiboma is the term applied for a retained surgical sponge. It is derived latin word -gossypium (cotton) and boma (place of concealment).

The presentation is variable. It can vary from acute inflammatory reaction or features of obstruction. If it becomes infected, an abscess may form. A delayed presentation may develop months or years after initial surgery. Adhesions / encapsulations are common. The lesion may present as mass and cause subacute intestinal obstruction.

The typical appearance on sonography is of a bright echogenic structure with cystic areas. The pattern of shadowing changes with direction of beam. On CT, gas trapped the sponge is visible.

Surgical removal is mandatory.

## References

**Author Information**

**Priya Darshan Chugar**

Consultant Radiologist, Nivaran CT Scan/MRI centre