

# Oral Leiomyosarcoma With Bilateral Renal Metastases In A Pregnant Female: A Case Report

P Shukla, P Gupta, D Gupta, M Pant, N Husain, S Bisht

## Citation

P Shukla, P Gupta, D Gupta, M Pant, N Husain, S Bisht. *Oral Leiomyosarcoma With Bilateral Renal Metastases In A Pregnant Female: A Case Report*. The Internet Journal of Oncology. 2008 Volume 6 Number 1.

## Abstract

Leiomyosarcoma account for 5-10% of soft tissue sarcomas<sup>1</sup>. They are principally tumors of adult life and are more common in women than in men. Primary oral leiomyosarcoma is a rare entity with unusual bone location because of paucity of smooth muscle in that site<sup>2</sup>. We report a histologically proven case of leiomyosarcoma of maxilla with bilateral renal metastasis, which were visualized in CT and diagnosed by CT guided fine needle aspiration cytology (FNA).

## INTRODUCTION

Leiomyosarcoma account for 5-10% of soft tissue sarcomas<sup>1</sup>. They are principally tumors of adult life and are more common in women than in men. Primary oral leiomyosarcoma is a rare entity with unusual bone location because of paucity of smooth muscle in that site<sup>2</sup>. We report a histologically proven case of leiomyosarcoma of maxilla with bilateral renal metastasis, which were visualized in CT and diagnosed by CT guided fine needle aspiration cytology (FNA).

## CASE REPORT

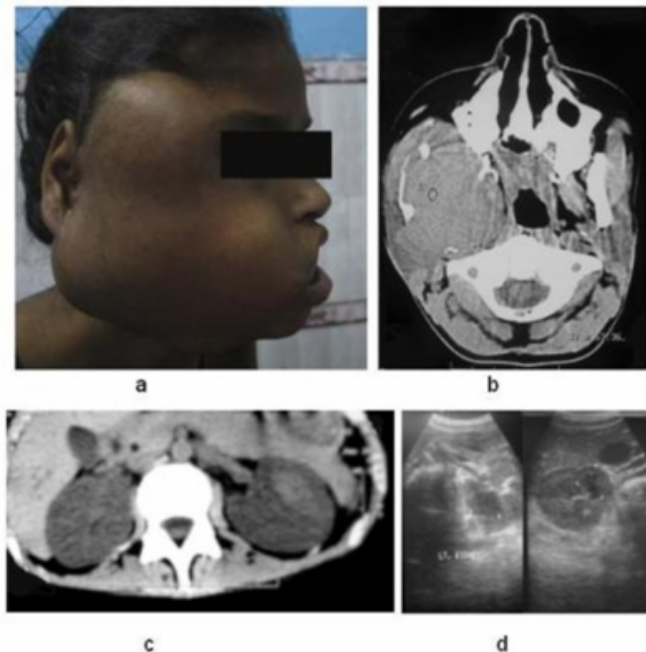
**Clinical History:** A 22-year-old female presented four months following delivery to our outpatient department with a huge maxillary swelling involving the oral cavity and the temporal area (fig 1a). She had first noticed this swelling one-year back when she was pregnant. The lesion grew during her pregnancy and after delivery. On examination, there was a massive swelling involving the entire right face. It was congested, painful, with associated mucus and bloody discharge in the oral cavity. Lymph nodes were not palpable. Clinical systemic examination revealed no other signs. The biochemical and hematological parameters were within normal limits.

**Radioimaging studies:** A computerized tomography (CT) scan of the head showed a large soft tissue lesion centered in the right infratemporal fossa and masseteric space, and extending superiorly to the floor of the middle cranial fossa, inferiorly to the upper border of right submandibular gland, medially to the parapharyngeal space, anteriorly to the

posterior wall of right maxillary sinus which was destroyed, laterally to the masseter and facial soft tissue and posteriorly to the posterior styloid compartment of the right parapharyngeal space (fig.1b). The differential diagnosis was a nerve sheath tumor or a neoplastic soft tissue lesion. The chest X-Ray was normal. An ultrasonography of the abdomen revealed bilateral hypoechoic renal masses (fig.1c). A CT scan of the abdomen showed ill-defined hyperdense lobulated masses in both kidneys (fig1d).

**Figure 1**

Figure 1: (a) Photograph of patient showing extensive lesion on right side of face (b) CT scan face: large extensive soft tissue attenuation lesion with epicentre at the right infratemporal fossa and masseteric space (c) Ultrasound kidney: bilateral hypoechoic renal masses (d) CT abdomen: showing bilateral heterogenous renal masses

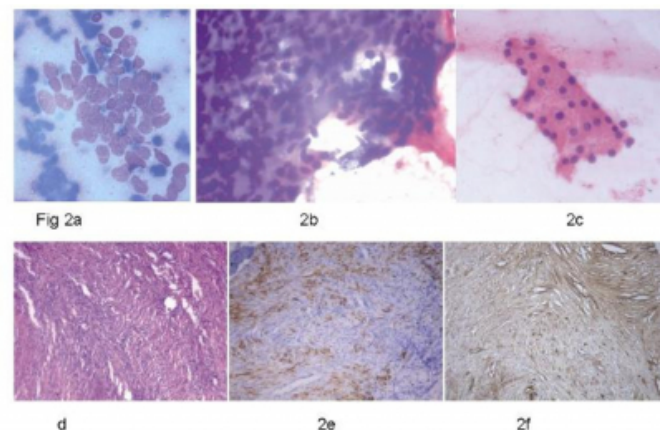


**Pathological Evaluation:** An FNA of the oral lesion showed cellular smears with clusters of short spindle cells with oval nuclei and moderate amount of cytoplasm. The cells showed moderate degree of nuclear pleomorphism (fig2a). The impression was that of a spindle cell sarcoma and an incisional biopsy showed intersecting fascicles of spindle cells cut at right angles to each other (fig 2d). Tumor cells displayed vesicular, oval to elongated nuclei, with occasional prominent nucleoli and eosinophilic cytoplasm. Mitotic activity was present. The histopathological picture was consistent with a spindle cell sarcoma. On immunohistochemical testing (IHC), the tumor diffusely expressed smooth muscle actin (fig 2f) and desmin (fig 2e), confirming the diagnosis of leiomyosarcoma. Neurofilament expression was negative. Because the tumor arose during pregnancy, the presence of estrogen and progesterone receptors was evaluated, but they were not expressed. All primary antibodies were obtained from Dakopatts Denmark and a secondary LSAB-2 kit from Dakopatts Denmark was used for detection with diaminbenzidine as a substrate. CT guided aspirates from the bilateral renal lesions revealed few cellular clusters of bipolar spindle cells with high nucleo-cytoplasmic ratio and moderate degree of nuclear pleomorphism (fig 2b). Clusters of normal renal tubular cells

were also seen (fig 2c). These findings were consistent with the diagnosis of metastatic leiomyosarcoma to the kidneys.

**Figure 2**

Figure 2: (a) Cluster of tumor cells in FNA from maxilla (Giemsa x 525 x digital magnification) (b) Spindled tumor cells in FNA from renal lesion and (c) a cluster of benign renal tubular cells (H& E x 525 x digital magnification) (d) Biopsy showing intersecting fascicles of spindled cells (H & E x 125 x digital magnification) (e) Tumor cells expressing desmin and (f) smooth muscle actin (LSAB x 125 x digital magnification)



**Therapy:** Surgical resection was not possible due to the extensive spread. In view of the fact that the primary tumor was not resectable and renal metastases were present, the patient was treated with chemotherapy. Six courses of doxorubicin 60 mg/m<sup>2</sup> (Day1) and Ifosfamide 2 g/m<sup>2</sup> (Day1-Day3) every 21days are planned. The patient has already received three cycles of this anthracycline-based regimen with evidence of some regression in the size of the lesion.

**DISCUSSION**

The incidence of leiomyosarcomas (LMS) among sarcomas of oral and maxillofacial region was found to be 6.25% by Yamaguchi et al<sup>4</sup> in a study of 32 cases of oral and maxillofacial sarcomas. The peak incidence of oral LMS is in the third then sixth and seventh decades. Females have a higher incidence in the third decade, whereas males have an even age distribution<sup>5</sup>. The diagnosis of soft tissue leiomyosarcoma is based on the morphologic features mainly a spindle cell neoplasm with intersecting bundles, blunt ended nuclei, varying degrees of anaplasia and mitoses. IHC for smooth muscle actin and desmin supports the diagnosis<sup>6</sup>.

Estrogen receptor positivity has also been reported in some leiomyosarcomas, raising the possibility of hormonal responsiveness. In an IHC study of estrogen receptor (ER)

and progesterone receptor (PR) expression in uterine and extrauterine leiomyosarcomas, most uterine LMS co-expressed ER and PR, but most extrauterine LMS did not stain for these antigens. However, a subset of extrauterine LMS was ER and/or PR immunoreactive.<sup>7</sup> In the presented case, the tumor developed and progressed during pregnancy but there was no nuclear staining for estrogen and progesterone receptors. The occurrence of cancer in pregnant women is relatively infrequent. Sarcomas which have been diagnosed during pregnancy include osteosarcoma, rhabdomyosarcoma, liposarcoma, Ewing's Sarcoma, and chondrosarcoma.<sup>8</sup> Uterine LMS and vulvar LMS have been reported during pregnancy, but this is the first case of oral leiomyosarcoma.

Leiomyosarcomas are rare in the maxilla due to minimal smooth muscle in this anatomic region. In several studies of oral LMS, 50% -70% of the cases arose from the jaws.<sup>3,9</sup> Most of the cases appeared to be associated with neurovascular structures of the facial skeleton, as evidenced by the imaging studies.<sup>5</sup> In our case, the clinical examination and imaging results indicated a maxillary origin of the tumor, but the exact origin could not be ascertained due to advanced state of the disease and the unresectability of the tumor at presentation.

Distant metastases are seen in 39% cases of oral LMS and occur mainly in the lungs and rarely in cervical lymph nodes.<sup>3</sup> The case presented above had no metastasis to the lung as evidenced by chest X-ray and had no enlarged lymph nodes. One case of maxillary LMS with spinal metastases was reported in the literature,<sup>10</sup> but none with renal metastases.

Although metastases to the kidney occur in 7-20% of patients with cancer at autopsy,<sup>11</sup> the diagnosis of metastases to the kidney in patients without evidence of a disseminated non renal malignancy is rare. In a review of 100 consecutive patients with non renal malignancies (cancers of the lung, esophagus, head and neck, breast, colon, pancreas, extremity sarcoma, testis, lymphoma, and myelodysplasia) diagnosed with renal masses at presentation or during follow-up, only 19 were metastatic.<sup>12</sup> Other primary neoplasms which may metastasize to the kidney include carcinoma of the stomach, melanoma, and leukaemia. Metastases to the kidneys are frequently small, asymptomatic, and detected only at autopsy. Renal metastases may present as multiple or bilateral small renal masses or, less commonly, as a solitary lesion. Our case presented with bilateral renal masses in the

presence of a non renal malignancy, which was very suggestive of metastases to the kidney. We further confirmed the presence of spindle cell neoplasm in CT guided FNAs from the renal lesions. In conclusion, LMS of the oral cavity is a very rare tumor, that is associated with an aggressive clinical behavior and a poor survival. Treatment should follow the guidelines on extremity sarcoma of the National Comprehensive Cancer Network (NCCN) Clinical Practice Guidelines in Oncology™ at [http://www.nccn.org/professionals/physician\\_gls/PDF/sarcoma.pdf](http://www.nccn.org/professionals/physician_gls/PDF/sarcoma.pdf)

## CORRESPONDENCE TO

Pragya Shukla, M.D. Department of Radiotherapy CSMMU, Lucknow Email: [pragya\\_upadhyay@yahoo.co.in](mailto:pragya_upadhyay@yahoo.co.in) Phone number - +91- 510-2471553

## References

1. L. Barnes, Tumor and tumor-like lesions of the soft tissues. In: L. Barnes, Editor, Surgical pathology of the head and neck, Marcel Dekker, New York (1985), pp. 814-821.
2. C. Cidis Meltzer, Elliot K. Fishman, W. W. Scott Jr (1992) Computed tomography appearance of bone metastases of leiomyosarcoma Skeletal Radiology; 21: 445-447
3. Schenberg ME, Slootweg PJ, Koole R (1993) Leiomyosarcoma of the oral cavity. Report of four cases and review of the literature. J Craniomaxillofacial Surg; 21:342-7.
4. Yamaguchi S, Nagasawa H, Suzuki T et al (2004) Sarcomas of the oral and maxillofacial region: a review of 32 cases in 25 years. Clin Oral Investig. ;8(2): 52-5.
5. Vilos GA, Rapidis AD, Lagogiannis GD et al Leiomyosarcomas of the oral tissues: clinicopathologic analysis of 50 case. J Oral Maxillofac Surg. 2005 Oct; 63(10): 1461-77
6. Christopher D.M. Fletcher, K. Krishnan Unni, Fredrik Mertens (Eds.) World Health Organization Classification of tumors. Pathology and Genetics of Tumors of Soft Tissue and Bone, IARC Press, Lyon 2002. pp 131-134
7. Kelley Todd W.; Borden Ernest C.; Goldblum John R. Estrogen and Progesterone Receptor Expression in Uterine and Extrauterine Leiomyosarcomas: An Immunohistochemical Study. Applied Immunohistochemistry & Molecular Morphology. 12(4): 338-341, December 2004.
8. A. Al-Jubran, M. Abdel Salam, A. El-Weshi et al Bone and soft tissue sarcomas during pregnancy Journal of Clinical Oncology, 2005 ASCO Annual Meeting Proceedings. 23: 9077 2005 American Society of Clinical Oncology
9. Dry SM, Jorengsen JL, Fletcher CD (2000) Leiomyosarcomas of the oral cavity: an unusual topographic subset easily mistaken for nonmesenchymal tumors. Histopathology. 36(3): 210-20
10. Abrams H, Spira R, Goldstein N (1950). Metastases in carcinoma: analysis of 1000 autopsied cases. Cancer; 3: 74-85.
11. Mubasher Ikram, Imtihan Ahmed, Daniyal Ahmed et al June, 2003 Leiomyosarcoma of the maxilla with spinal metastasis: a case report . Ear, Nose & Throat Journal 82: 458-460

12. Ricardo F. Sánchez-Ortiz, Lydia T. Madsen, Carlos E. Bermejo et al (2004) A renal mass in the setting of a

nonrenal malignancy When is a renal tumor biopsy appropriate? Cancer; 101: (10) 2195-2201.

**Author Information**

**Pragya Shukla, MD**

Department of Radiotherapy , CSMMU

**Pronati Gupta, MD**

Pathology SGPGI

**Deepak Gupta, MD**

Dept of Radiotherapy, CSMMU

**Mohan Chand Pant, M.D.**

Dept of Radiotherapy, CSMMU

**Nuzhat Husain, MD**

CSMMU

**Shyam Singh Bisht, MD**

Department of Radiotherapy , King George's Medical University