

# An Unusual Solitary Ileal Polyp Presenting with Gangrenous Intussusception

D Belekar, R Verma

## Citation

D Belekar, R Verma. *An Unusual Solitary Ileal Polyp Presenting with Gangrenous Intussusception*. The Internet Journal of Surgery. 2008 Volume 18 Number 2.

## Abstract

Intussusception is a relatively frequent cause of intestinal obstruction in infancy and early childhood. In 95% of cases the cause remains unknown. In older children there usually is a lead point that causes intussusception; Meckel's diverticulum and hypertrophied Peyer's patches remain some of the commonest causes. A solitary large polyp in the proximal ileum is rare and its presentation as gangrenous intussusception within just 24 hours is still more unusual. We report such an unusual case at our institute.

## CASE REPORT

A 6-year-old Muslim male child presented in the emergency department with severe pain in the abdomen, around the umbilicus, and with multiple episodes of vomiting for one day.

The patient was apparently alright one day before when he first experienced pain around the umbilicus, which gradually increased in intensity and remained persistent later on. There was an appearance of a small lump on the left side of the umbilicus accompanied with multiple episodes of vomiting, greenish-yellow in color. The patient had passed hard stools once in the early morning and had low-grade fever.

There was no similar history in the past with no other major illnesses. There was no history of any local trauma or any operation performed on the child in the past.

On examination, the patient was drowsy but oriented in time, place and person after deep stimulus. He had fever of 38.5°C and his pulse rate was 124 beats per minute. His blood pressure was 100/70mm of Hg.

On abdominal examination, there was a sausage-shaped mass present on the left and superior aspect of the umbilicus measuring 12cm×4cm×3cm with no distension of abdomen elsewhere. The mass was soft in consistency, not moving much with respiration. Bowel sounds were hyper-peristaltic. Per rectal examination showed an empty rectum.

Clinical diagnosis of intussusception was obvious.

Emergency investigations revealed a WBC count of 20,800/cumm, an Hb of 11.3 gm%, Na 139 and K 4.2 mEq/L.

Plain X-ray of the abdomen showed localized air-fluid levels in the left lumbar area with no gas beyond that in the rest of the abdomen. There was no free gas under the diaphragm.

A decision to perform an emergency exploration was taken after adequate resuscitation of the patient.

At exploration, the following findings were noted:

Proximal ileo-ileal intussusception, 15cm in length, which was gangrenous.

A large solitary polyp, 4.5cm in length, was forming the apex which was totally blackened.

Multiple discrete mesenteric lymph nodes.

The appendix was mildly inflamed with a small worm within the lumen.

The rest of the bowel was normal with no worms/polyps elsewhere.

The rest of the viscera were normal.

An attempt to reduce the intussusception was made by pushing back the intussusceptum but it failed. It was totally gangrenous. Eventually, the intussusceptum perforated through the serosa of the intussusciens and then the decision to perform a resection with end-to-end ileo-ileal

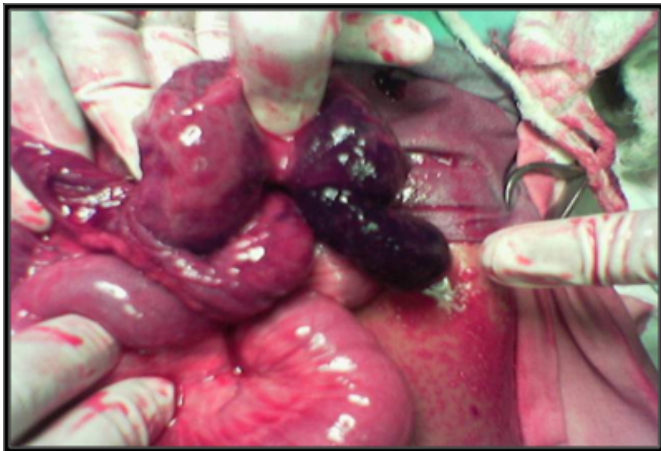anastomosis was taken. Mesenteric lymph node biopsy was taken and appendicectomy was also performed. A corrugated rubber drain was kept near the site of anastomosis.

The postoperative course was uneventful and the patient made a remarkably good recovery. The drain was removed after 72 hours. Oral nutrition was started on the 4<sup>th</sup> postoperative day after appearance of bowel sounds. The patient was discharged after complete suture removal. At follow-up after 2 years, the patient was completely asymptomatic and healthy.

On gross pathological examination, the coiled up intestine measured 20cm in length. The serosa was covered with exudates. On opening, the lumen was filled with altered blood and showed an infracted polyp measuring 6×2.5×1 cm forming the apex of the intussusceptum. The neck of the intussusception showed complete obstruction of the intestinal lumen and the surrounding segment appeared gangrenous. The appendix showed congestion with a faecolith.

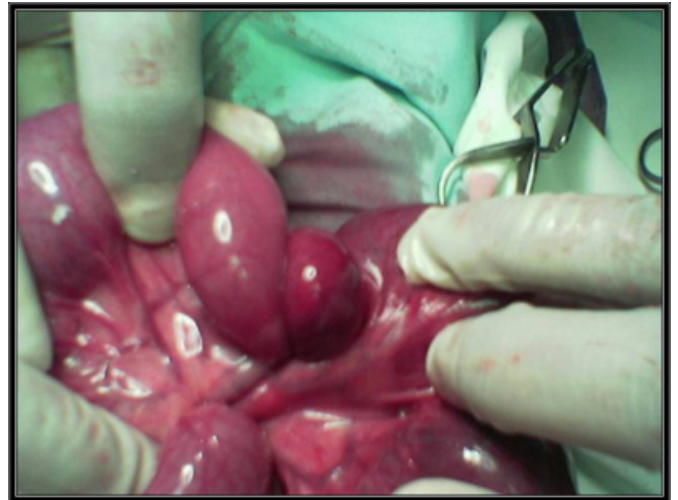
**Figure 1**

Figure 1: Gangrenous lead point: Ileal solitary polyp

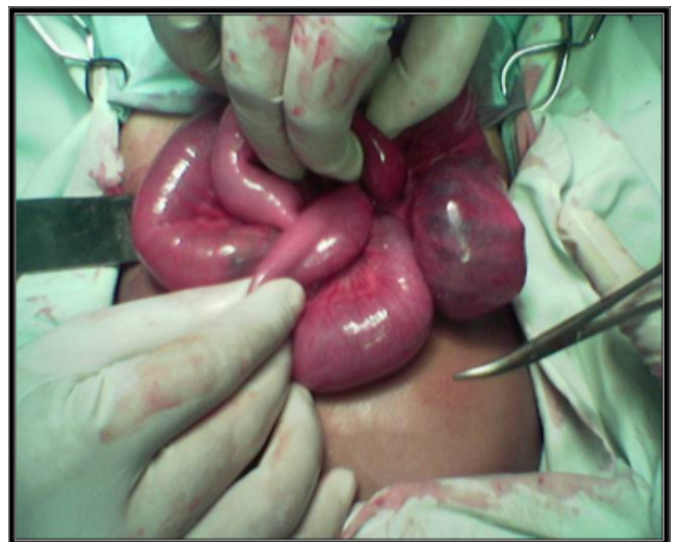


**Figure 2**

Figure 2a and 2b: Ileo-ileal intussusception getting “reduced”

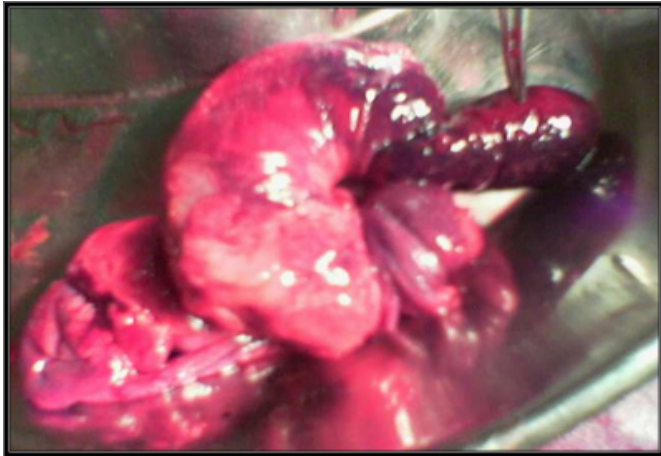

**Figure 3**



**Figure 4**

Figure 3: Resected specimen with ileal polyp



On microscopy, sections from intussusception, intussusciens and polyp showed near-complete transmural infarction with hemorrhage and inflammation. The adjacent mucosa showed changes related to partial ischemia. The subserosa showed congested vessels with oedema and hemorrhage and the mesenteric vessels showed congestion.

Impression: Small-bowel gangrene due to intussusception secondary to a large solitary polyp. The exact nature of the polyp could not be determined due to complete infarction.

Sections from the appendix showed reactive lymphoid hyperplasia with a transversely cut worm (*E. vermicularis*) in the lumen.

**DISCUSSION**

Intussusception can be defined as an invagination of one portion of gut within an immediately adjacent segment, invariably from proximal into distal bowel.

It occurs in two forms: a) acute and b) recurrent, which is very rare. It is encountered most commonly in children with a peak incidence between 3-9 months. Between 70%-95% of cases are idiopathic in nature and are associated with illnesses like gastroenteritis or UTI, in 30% it is hyperplasia of Peyer's patches in the terminal ileum which is a common initiating event. This may occur secondary to weaning. It may also be related to upper respiratory tract infection with pathogens like adenovirus and rotavirus.

In older children, usually there is a lead point, most commonly Meckel's diverticulum, polyp, duplication, Henoch-Schonlein purpura or appendix.

In adults, it is invariably associated with polyp (Peutz-

Jegher's syndrome), submucosal lipoma or tumour, an exception being after long periods of fasting. The colo-colic variety is common in adults. The commonest variety overall is ileo-colic (77%), followed by ileo-ileo-colic (12%), ileo-ileal (5%), colo-colic (2%), multiple (1%), retrograde (0.2%) and others (2.8%).

Clinical features as demonstrated by Sir Hamilton Bailey are classic with a sausage-shaped mass periumbilically with concavity towards the umbilicus, empty right iliac fossa (a sign demonstrated by Jean Dance) and the patient typically passes 'red current' jelly stools due to mucosal bleeding. The abdomen remains non-distended and occasionally the apex may remain palpable on per rectal examination.

Barium enema serves as a diagnostic as well as therapeutic tool. It typically shows the 'claw sign' in the ileo-colic/colo-colic type.

In early stages, when the child is not toxic, non-surgical modes remain the mainstay of treatment. Hydrostatic reduction is effective in 50% of cases with a recurrence rate of 5%. The air-reduction technique was introduced in China and became popular in the USA and Canada, with similar complications of perforation. Color Doppler serves as an important tool to early diagnose bowel viability and degree of ischemia. Ultrasound is also a reliable method of diagnosis with typical features showing a pseudo-kidney sign, target sign or complex hyper-echoic mass sign.

The child needs to be vigorously resuscitated to correct dehydration and electrolyte imbalance with nasogastric decompression and intravenous fluid supplements along with antibiotic cover. Complete obstruction, peritonitis and a child becoming toxic are indications for emergency explorations.

On exploration, the distal portion is milked into proximal bowel; the proximal part is never pulled. If this is not possible, then, by Cope's method, complete adhesiolysis is done around the neck to facilitate reduction. Reduction is stopped if the serosa splits. If the affected area remains non-viable, resection and anastomosis with appendectomy is done. In severe complications, resection and a temporary enterostomy are performed. Recurrence rate after surgery is extremely low with zero mortality.

Our case showed all classic features of intussusception in a 6-year-old male child who was very toxic and febrile at presentation after a duration of only 24 hours. Ileal solitary polyps are rare as polyps are usually found in the jejunum.

Again, the polyp was very large as compared to this small child of 13kg. Unfortunately, the exact nature of the polyp could not be determined as it underwent complete infarction. Early correct diagnosis, vigorous resuscitation and prompt surgical correction prevented death of the child. In a non-toxic child non-operative intervention remains the mainstay. However, we have reported an unusual large solitary polyp presenting with gangrenous intussusception which warranted resection and anastomosis.

### **CORRESPONDENCE TO**

Dr. Dnyanesh M. Belekhar, Associate Professor, Department of General Surgery, K. J. Somaiya Medical College, Hospital and Research Center, Sion, Mumbai 400022.  
Contact no.: Mobile - +919820055482 Email ID:

dnyaneshbelekar@yahoo.co.in

### **References**

1. Ein SH. Leading points in childhood intussusception. *J Pediatr Surg* 1976; 11: 209-211.
2. Weilbaecher D, Bolin J, Hearn D, Ogden W. Intussusception in adults. *Am J Surg.* 1971; 121: 531-535.
3. Azar T, Berger D. Adult intussusception. *Ann Surg* 1997; 226: 143-138.
4. Colon AR, Dipalma JS, Leftridge CA. Intestinal lymphonodular hyperplasia of childhood: patterns of presentation. *J Clin Gastroenterol* 1991; 13: 163-166.
5. Dabral C, Singh N, Singh PA, Misra V. Inflammatory fibroid
6. *Indian J Gastroenterol.* 2003; 22: 101.
7. Eklof OA, Johanson L, Lohr G. Childhood intussusception: hydrostatic reducibility and incidence of leading points in different age groups. *Pediatr Radiol* 1980; 10: 83-86.

**Author Information**

**Dnyanesh Madhukar Belekar, MS, FCPS, DNB, MNAMS, FMAS**

Dept of General Surgery, K. J. Somaiya Medical College, Hospital and Research Center

**Radha A. Verma, MS**

Dept of General Surgery, K. J. Somaiya Medical College, Hospital and Research Center