

# Bilateral Lipoderma In Adult: A Rare Case

V Sharma, P Varma, S Vaidya

## Citation

V Sharma, P Varma, S Vaidya. *Bilateral Lipoderma In Adult: A Rare Case*. The Internet Journal of Ophthalmology and Visual Science. 2005 Volume 4 Number 1.

## Abstract

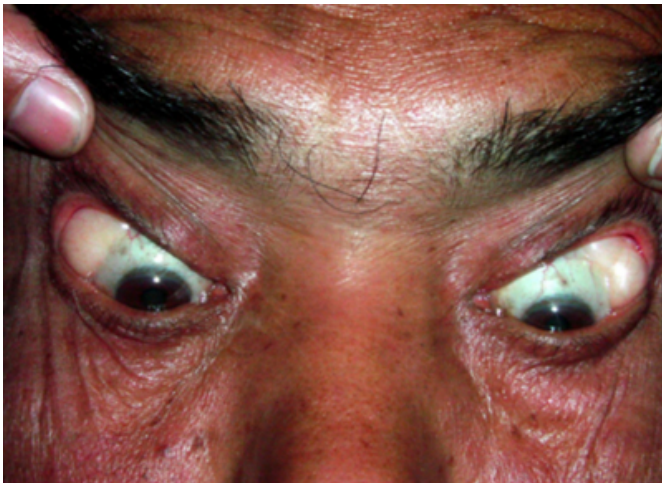
Lipodermatas are within the spectrum of choristomas, which are collections of microscopically normal epithelial cells or dermis-like tissues in abnormal locations (heterotopic tissue).<sup>1</sup> Epithelial, dermal, neural, cartilaginous, smooth muscle, lacrimal, sweat gland, and sebaceous gland tissue in any combination may be present. Three types of eye choristomas are described in the literature: dermolipomas, dermoids, and complex choristomas<sup>2,3</sup>

They are actually not true neoplasm and usually congenital, found at the outer canthus, consists of fibrous tissue and fat in variable proportion and are usually not encapsulated, but it will be found that the fat is continuous with that of the orbit.<sup>4</sup> The main mass may be removed with care if cosmetically unacceptable.<sup>5</sup> Authors have reported a rare case of bilateral dermolipomas in the middle-aged person, which were removed without any postoperative complications.

A 50 years old healthy male presented to us with history of mild pain and irritation in both eyes with visible soft tissue mass in upper outer canthus in both eyes. (Fig.1)

## Figure 1

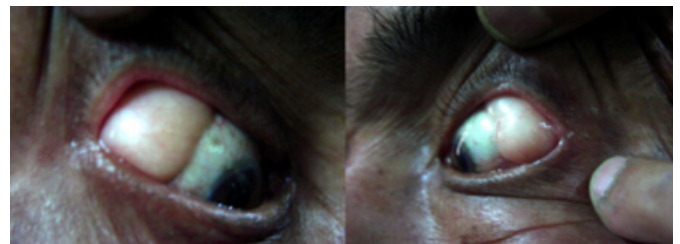
Figure 1: Bilateral swelling in upper-temporal areas



There was no history of trauma or any surgery in past. The swellings were visible without everting eyelids since last 4 years. They were yellowish-pink in colour, soft in consistency, with well defined anterior margin, below conjunctiva; which can be moved over the surface of tumor mass and at same time mass were also not fixed to sclera. They were painless, non-tender, devoid of any signs of inflammation, and equal in sizes in the both eyes. (Fig.2, 3)

## Figure 2

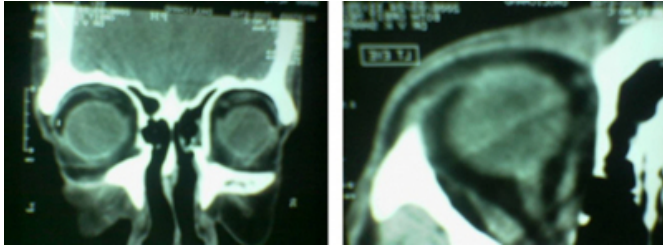
Figures 2 and 3: Right and left eye



Slit lamp examination showed otherwise normal anterior segment. Visual acuity with refractive correction was 6/6 in both eyes. Systemic examination did not reveal any other anatomical or pathological abnormality. He was known diabetic on anti-diabetic drugs since last 5 years. Routine investigation including Hemoglobin, total and differential counts, peripheral smear for immature cells, ESR, chest X-ray, Mountoux test were within normal limits. A clinical diagnosis of lacrimal gland tumor was ruled out as it was below bulbar conjunctiva and adjacent to globe, not fixed to conjunctiva or sclera, although they were in upper outer regions of the eyeball. Posterior margin cannot be visualized or palpated. Ultra-sonography and CT showed ellipsoid mass of 19mm x 8mm in R.E and 21x10 mm in L.E. situated adjacent to globe continuing in orbit without clear demarcation. (Fig. 4,5)

**Figure 3**

Figures 4 and 5: CT views



After controlling blood sugar, excision biopsy of R.E. tumor mass done under local anesthesia, xylocaine 2% with adrenaline injected between conjunctiva and mass; and below the mass. 6 mm conjunctival incision made at the lower border of tumor mass. Tumor was found encapsulated, loosely attached to conjunctiva above and to the sclera below. Special care taken so that not to damage insertions of lateral rectus and superior rectus muscle or lacrimal glands. Posterior limit of the mass cannot be visualized. Mass was pulled up and cut as posteriorly as possible. The remaining mass receded back by its own due to elasticity of tissue. Wound closed by 5- 0 non-absorbable silk suture.

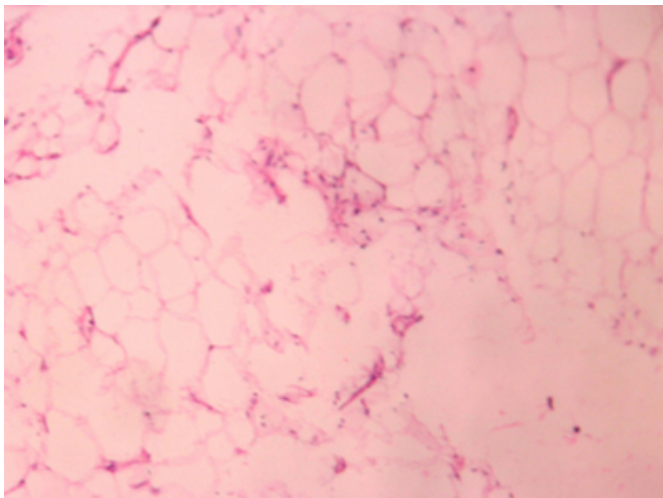
The same procedure repeated in left eye after 2 months.

## RESULTS

Biopsy showed abundant fatty tissues. No other tissue detected (fig.6). Wound healed without any delay and no complications observed like dry eye, ptosis or diplopia. Follow up after 3 months showed no visible swelling with normal eyeball without any restriction of movements

**Figure 4**

Figure 6: Histopathological examinations



## DISCUSSION

Dermolipomas are generally asymptomatic, usually located in the lateral epicanthic region near the insertion of the lateral rectus muscle because they usually arise from the superotemporal conjunctiva. Most patients are bothered more by the cosmetic appearance than by physical symptoms. It may be noticeable as a bulge underneath the upper eyelid or may require eversion of the eyelid to be visualized. On occasion, the mass may put pressure on the globe and produce astigmatism. The differential diagnostic considerations include prolapse of orbital fat, palpebral globes of the lacrimal gland, and lymphoma.

Histologically, dermoids of the conjunctiva contain a dense stroma of collagen and elements of pilosebaceous units, eccrine glands, and fat. By comparison, complex choristomas contain variable combinations of hamartomatous tissues. When there is a significant acinar (i.e., glandular) component, the lesion can appear fleshy and vascular and have multiple raised, translucent papules. These have been referred to as ectopic lacrimal glands.

Dermolipomas are isolated, benign lesions, they may occur in the context of systemic disorders, including mandibulofacial dysostosis (Treacher Collins syndrome or Franceschetti syndrome), Solomon's epidermal nevus syndrome, and encephalocraniocutaneous lipomatosis.<sup>1</sup> Goldenhar's syndrome which puts in associations multiple lesions of the first branchial arc are also noted as a dermoid of the limb, the second associates a conjunctival dermolipoma at one eye with dermoid of the limb at the other eye.<sup>7</sup> Dermolipoma may be adherent to the lacrimal gland,<sup>8</sup> or epibulbar osteoma.<sup>9</sup> Epibulbar osseous choristoma and ectopic lacrimal gland underlying a dermolipoma were also noted.<sup>10</sup> In our case as there was no tissue other than fat, they were dermolipomas. They can be differentiated by orbital fat prolapse,<sup>11</sup> as there were encapsulated and present in both eyes and the patient was not obese with any other congenital anomaly. Orbital fat prolapse causes confusion in the diagnosis but line of treatment is same for both the conditions e.g. surgical removal if producing symptoms or cosmetically non-acceptable.

The surgery of dermolipoma is fraught with dangers<sup>5</sup> and when indicated, should be considered with due care. It too often is followed by damage to the lacrimal secretory system, dry eye syndrome,<sup>12</sup> strabismus, intractable diplopia, blepharoptosis.<sup>13</sup> Since these tumors are benign, the smallest amount of surgery that debulks the tumor and leads

to a cosmetically acceptable result is the best surgery for the patient's satisfaction and for the surgeon's peace of mind. By being aware of these factors, the surgeon can avoid most complications.

## **CORRESPONDENCE TO**

Dr. Virendra Kumar Sharma E-20 Rishi Nagar Ujjain 456  
010 Madhya Pradesh (India) E-mail –  
dr.virendra.k.sharma@gmail.com

## **References**

1. Yehia Y. Mishriki, MD. Bilateral eye tumors of long duration Postgrad Med. 2004 Nov; 116(5): 53-4.
2. Heffler KF. Tumors of the cornea and conjunctiva. Curr Opin Ophthalmol 1995; 6(4): 32-8
3. Oakman JH Jr, Lambert SR, Grossniklaus HE. Corneal dermoid: case report and review of classification. J Pediatr Ophthalmol Strabismus 1993; 30(6): 388-91
4. Parson
5. Beard C. Dermolipoma surgery, or, "an ounce of prevention is worth a pound of cure". Ophthalm Plast Reconstr Surg. 1990; 6(3): 153-7.
6. McNab AA. Subconjunctival fat prolapse. Aust N Z J Ophthalmol 1999; 27(1): 33-6
7. Craitoiu S. [Goldenhar's oculoauricular dysplasia, limbic dermoid and conjunctival dermolipoma] Clinica Oftalmologica Craiova
8. Kamali K, El-Rifai. Dermolipoma adherent to the lacrimal gland. Bull Ophthalmol Soc Egypt. 1975; 68:633-6.
9. Daicker BC, Perren B. Epibulbar osteoma combined with dermolipoma. Ophthalmologica. 1977; 174(1): 58-60.
10. Hered RW, Hiles DA. Epibulbar osseous choristoma and ectopic lacrimal gland underlying a dermolipoma. J Pediatr Ophthalmol Strabismus. 1987 Sep-Oct; 24(5): 255-8.
11. Kim YD, Goldberg RA. Orbital fat prolapse and dermolipoma: two distinct entities. : Korean J Ophthalmol. 1994 Jun;8(1):42-3.
12. Economidis I, Tragakis M, Mangouritsas N, Papademetriou D. Keratoconjunctivitis sicca following excision of a dermolipoma of the lacrimal gland. Ophthalmologica. 1977; 174(1): 58-60.
13. Paris GL, Beard Blepharoptosis following dermolipoma surgery. Ann Ophthalmol. 1973 Jun; 5(6): 697-9.

**Author Information**

**Virendra Kumar Sharma, M.S.**

Associate Professor, Department of Ophthalmology, R.D.Gardi Medical College

**Pushpa Varma, M.S.**

Professor, Department of Ophthalmology, M.G.M.Medical College

**Sudhakar Vaidya, D.L.O., D.N.B.**

Associate Professor, Department of E.N.T., R.D.Gardi Medical College