

Comparative Study of Different Concentration of Trypan Blue for Staining of Capsule in Mature Cataract using RGB Scale in “Adobe Photoshop Image Reader”

H Trivedi, L Trivedi, U Bhammarkar, K Bhalani

Citation

H Trivedi, L Trivedi, U Bhammarkar, K Bhalani. *Comparative Study of Different Concentration of Trypan Blue for Staining of Capsule in Mature Cataract using RGB Scale in “Adobe Photoshop Image Reader”*. The Internet Journal of Ophthalmology and Visual Science. 2009 Volume 8 Number 1.

Abstract

Satisfactory capsulorhexis is essential in modern small incision cataract surgery. Visualization of capsule in mature cataract is difficult so staining of capsule with dye is required. Trypan blue is most commonly used dye. Carcinogenic effect of trypan blue is proved in animal study. Aim of this study was to determine minimum concentration of trypan blue that stains the anterior capsule. Methods: The study was conducted in 50 patients with senile mature cataract. Capsular staining was done with different concentration of trypan blue (Group A 0.06%, Group B 0.03%, Group C 0.015%, Group D 0.0075% and Group E 0.00375%) to enhance visualization of capsule for rhexis in cataract surgery. Comparative study of blueness of dye with different concentration was done by RGB scale values in “Adobe Photoshop image reader” Software (Version-7). Results : Trypan blue stains the capsule satisfactorily in group A, B and C. In group D and E capsular staining was not satisfactory. Conclusion: Concentrations of 0.03% and 0.015% were as effective as 0.06% to stain the capsule. Concentration of 0.0075% and 0.00375% could not stain the capsule.

INTRODUCTION

Anterior capsule staining in mature cataract can be done by using various vital dyes like trypan blue, indocyanine green, and sodium fluorescein^[1] to facilitate capsulorhexis. Sodium fluorescein is not used now. Because of its small molecular size, it is not able to remain confined in the anterior chamber but diffuses to lens and vitreous.^[2] While trypan blue and indocyanine green provides excellent visualization of the capsule, staining with trypan blue was definitely more intense and persistent.^[3] So trypan blue is preferred dye for staining of anterior capsule. Trypan blue was initially available as 0.1% but now it is available in 0.06% concentration. There is a report that even with lower concentration; it can effectively stain the anterior capsule.^[4]

The purpose of this study was to determine the minimum concentration of trypan blue that stains the anterior capsule. Blueness of dye which decides the staining of capsule was quantified with the help of RGB scale (Red, Green, Blue scale) on “Adobe Photoshop Image Reader” software (Version 7.0).

METHODS

This prospective double blind randomized study was carried out in the department of Ophthalmology, Medical College and Sir T. Hospital, Bhavnagar after approval from institutional ethics committee. The study was conducted in 50 patients with senile mature cataract undergoing small incision cataract surgery under peribulbar block. Patients with systemic diseases, any acute ocular inflammation or ocular complication in other eye, all congenital cataracts, glaucoma, traumatic cataract and pregnant patients were excluded from the study. After taking informed written consent, patients were randomized in five different groups according to different concentrations of trypan blue dye used; 0.06% in group A(n=10), 0.03% in group B(n=10), 0.015% in group C(n=10), 0.0075% in group D(n=10) and 0.00375% in group E(n=10).

METHOD OF PREPARATION OF DIFFERENT CONCENTRATION OF TRYPAN BLUE

Trypan blue is available in 0.06% concentration which was used in group A. It was diluted to half by adding equal volume of balanced salt solution (BSS) to make it 0.03% for

group B. Than it was diluted serially to make concentrations of 0.015%, 0.0075% and 0.00375% for group C, group D and group E respectively by adding BSS.

DOSAGE AND ADMINISTRATION

Trypan blue is available in 1ml /vial.

The volume of the dye used for capsular staining was 0.1 ml in all groups. The dye was applied for staining capsule by tuberculin syringe with hydro cannula under classic air bubble technique^[5] and kept in contact with capsule for 40 seconds.

Patients were operated by same surgeon using same microscope and illumination. Video recording was done with same video camera. Surgical procedure was transported through SV video port of microscope to computer with facility of TV tuner card. The required still image was taken and was opened with “Adobe Photoshop Image Reader” software version 7. A 6 mm center circle in stained capsule was cut in opened file and pasted in to a new file. Window menu bar was opened and RGB scale was opened in work space. RGB scale was calculated by the average of 5 readings which were taken from the centre, and from 12, 3, 6 & 9 o’clock position. Comparative study of satisfactory staining of capsule was done by using RGB scale values in “Adobe Photoshop Image Reader” Software (Version-7). In RGB scale, white color means R=255, B=255 and G=255.

Image 1 and 2 shows RGB scale values before and after stain in “Adobe Photoshop Image Reader” Software (Version-7).

Figure 1

Image 1: RGB scale on Adobe Photoshop (Before stain)

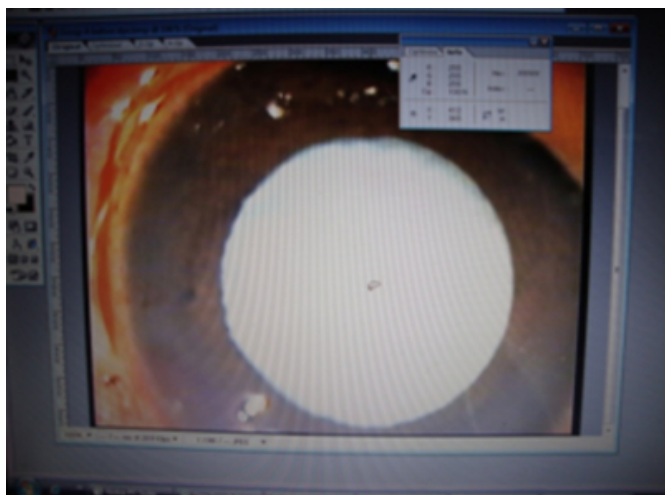
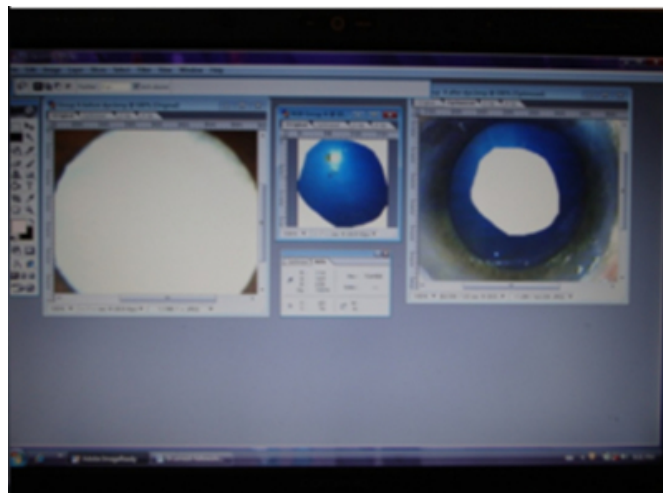


Figure 2

Image 2: RGB scale on Adobe Photoshop (After stain)



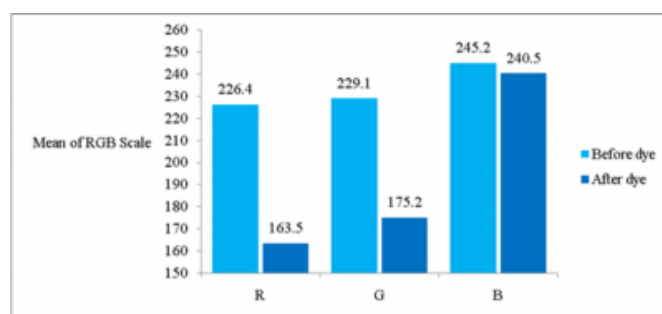
Data collected were subjected to statistical analysis. The difference between the pre and post stain R, G & B value were calculated for each concentration of trypan blue. Then the mean difference (MD) of R and G was compared with MD of B separately for each concentration of trypan blue. The paired t test was used to compare the MDs. P value of <0.05 was considered as statistically significant.

RESULTS

The R and G values were significantly decreased, while B value remained nearly same after staining the capsule in group A. Figure 1

Figure 3

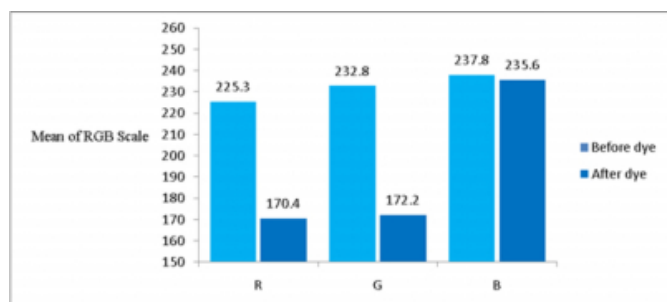
Figure 1: RGB values before and after trypan blue staining in group A



The R and G values were significantly decreased, while B value remained nearly same after staining the capsule in group B. Figure 2

Figure 4

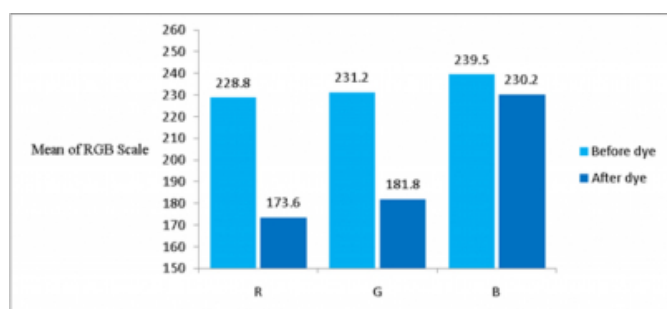
Figure 2: RGB values before and after trypan blue staining in group B



The R and G values were significantly decreased, while B value remained nearly same after staining the capsule in group C. Figure 3

Figure 5

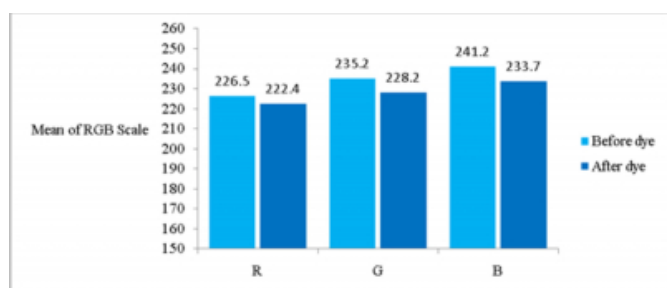
Figure 3: RGB values before and after trypan blue staining in group C



The R, G and B values remained nearly same before and after staining the capsule in group D Figure 4

Figure 6

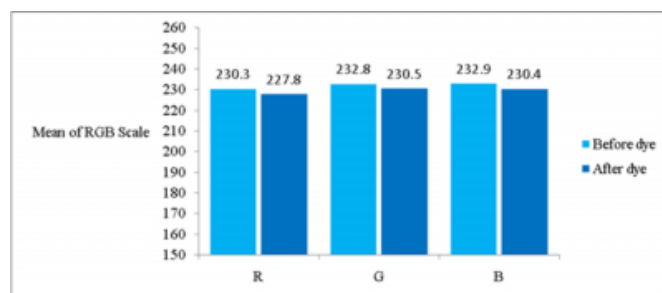
Figure 4: RGB values before and after trypan blue staining in group D



The R, G and B values remained nearly same before and after staining the capsule in group E. Figure 5

Figure 7

Figure 5: RGB values before and after Trypan blue staining in group E



The difference between before and after stain values of R, G and B were calculated and then mean of the differences (MD) in R, G and B were calculated for each concentration. Then the MD of R and G was compared with MD of B separately for each concentration of trypan blue. Table 1

Figure 8

Table 1: Comparison of R and G with B in all the groups

Groups	R(MD)	G(MD)	B(MD)	MD in R&MD in B	MD in G&MD in B
Group A Concen. 0.06%	62.90	53.90	4.70	P < 0.05%	P < 0.05%
Group B Concen. 0.03%	54.90	60.60	2.20	P < 0.05%	P < 0.05%
Group C Concen. 0.015%	55.20	49.40	9.30	P < 0.05%	P < 0.05%
Group D Concen. 0.035%	2.50	2.30	2.50	P > 0.05%	P > 0.05%
Group E Concen. 0.075%	4.10	7.00	7.50	P > 0.05%	P > 0.05%

There was statistically significant difference ($p < 0.05\%$) when MD of R and MD of G was compared with MD of B in groups A, B and C which indicate that capsular staining was satisfactory.

There was no statistical significant difference ($p > 0.05\%$) when MD of R and MD of G was compared with MD of B in groups D and E which indicate that capsular staining was not satisfactory.

DISCUSSION

Trypan blue is used to stain anterior capsule for successful capsulorhexis in mature cataract,^[6] cataract surgery in corneal scars or edema, dense anterior cortical spokes, a mature brown nucleus, vitreous hemorrhage and asteroid hyaloids and dye-aided anterior and posterior capsulorhexis in pediatric cataracts.^[7-8] It is also useful for teaching phaco technique because staining helps residents to find and grasp

the anterior capsular flap; it is particularly valuable for any surgeon learning new phaco techniques such as phaco flip or phaco chop. In the later method, a stained capsulorhexis edge helps the transitioning surgeon to avoid overly distending it with the chopper's shaft or misplacing the horizontal chopper's tip peripherally, outside the capsular bag.^[9-10]

Though trypan blue is widely used in ophthalmology, some study showed that it has carcinogenic properties^[11] and induces apoptosis in human retinal pigment epithelial cell at a higher concentration.^[12] Staining of hydrophilic acrylic intraocular lens with trypan blue has been reported in literature.^[13] Trypan blue was toxic in vitro to corneal endothelium and corneal fibroblasts at higher concentrations and notably longer exposure time.^[14]

Initially trypan blue was available in 0.1% concentration, but now-a-days it is available and used as 0.06% concentration. A study showed that even lower concentration can stain the capsule.^[3] Hence, we wished to determine minimum concentration of trypan blue which stains the capsule in mature cataract.

This study showed that in group A, B and C; R and G value decreased more compared to B after staining and MD of R and G before and after stain was statistically significant compared to MD of B value ($p < 0.05\%$). As blueness was not much altered in comparison of red and green, staining of capsule was satisfactory in all the three groups. In group D and E; R, G and B value remains almost same before and after staining so MD of R and G before and after stain was not statistically significant compared to MD of B value ($p > 0.05\%$). So capsule remains nearly white and visualization of capsule was not possible which indicates concentration of 0.0075% or lower could not stain the capsule satisfactorily.

We could not find all the patients with white mature cataract (R, G and B value 255) due to awareness of people and timely detection of cataract.

CONCLUSION

We conclude that trypan blue in concentration of 0.03% and 0.015% is as effective as 0.06% for staining the capsule. In view of the animal studies showing carcinogenicity of trypan blue with higher concentration and long term results in human being are awaited, we recommend 0.015% of trypan blue as the optimal concentration for staining the capsule in mature cataract.

References

1. Y. Chang, S. Tseng, S. Tseng. Comparison of dyes for cataract surgery. Part 2: Efficacy of capsule staining in a rabbit model. *J Cataract Refract Surg.* 2005;3 (4):799-804.
2. Fritz W. Fluorescein blue light-assisted capsulorhexis for mature or hyper mature cataract. *J Cataract Refract Surg.* 1998;24:19-20.
3. Shingo Satofuka, Kunihiro Nakamura, Kazuno Negishi et al. Time course of lens capsule staining using trypan blue and indocyanine green: In vitro study in porcine eyes. 2004;30:8,1751-1754.
4. Yetik H, Devranoglu K, Ozkan S. Determining the lowest trypan blue concentration that satisfactorily stains the anterior capsule. *J Cataract Ref Surg* 2002;28:988-91.
5. Horiguchi M, Miyake K, Ohta I, Ito Y. Staining of the lens capsule for circular continuous capsulorhexis in eyes with white cataract. *Arch Ophthalmol.* 1998; 116:535-537.
6. Melles GRJ, de Waard PWT, Pameijer JH, Beekhuis WH. Trypan blue capsule staining to visualize the capsulorhexis in cataract surgery. *J Cataract Refract Surg.* 1999;25:7-9.
7. Wakabayashi T, Yamamoto N. Posterior capsule staining and posterior continuous curvilinear capsulorhexis in congenital cataract. *J Cataract Refract Surg.* 2002; 28:2042-2044.
8. Saini JS, Jain AK, Sukhija J, et al. Anterior and posterior capsulorhexis in pediatric cataract surgery with or without trypan blue dye: randomized prospective clinical study. *J Cataract Refract Surg.* 2003;29:1733-1737.
9. Werner L, Pandey SK, Escobar-Gomez M, et al. Dye-enhanced cataract surgery. Part 2: learning critical steps of phacoemulsification. *J Cataract Refract Surg* 2000;26:1060-1065.
10. Dada T, Ray M, Bhartiya P, Vajpayee RB. Trypan-blue-assisted capsulorhexis for trainee phacoemulsification surgeons. *J Cataract Refract Surg* 2002;28:575-576.
11. Kozłowska H, Drewa G, Grzanka A. Effect of trypan blue on activity of lysosomal enzymes, tumor growth and cell ultra structure in B16 melanotic melanoma in mice. *Neoplasma* 1995;42:173-8.
12. Rezai KA, Farrokh-Siar L, Gasyna EM, Ernest JT. trypan blue induces apoptosis in human retinal pigment epithelial cells. *Am J Ophthalmol.* 2004;138:492-5.
13. Werner L. Permanent blue discoloration of a hydrogel intraocular lens by intraoperative trypan blue. *J Cat Ref Surg* 2002;28:1279-86.
14. Bart T. H., Van Dooren, W. Houdijn Beekhuis, Elisabeth Pels. Biocompatibility of Trypan Blue with Human Corneal Cells. *Arch ophthalmol.* 2004;122:736-742.

Author Information

Harish Ratilal Trivedi, M.S.

Associate professor, Department of Ophthalmology, Government Medical College

Lopa Pravinchandra Trivedi, M.D.

Assistant professor, Department of Anaesthesiology, Government Medical College

Umesh D. Bhammarkar

3rd year resident, Department of Ophthalmology, Government Medical College

Kailesh Dahyabhai Bhalani, M.D

Assistant professor, Department of Preventive and Social Medicine, Government Medical College