

# Acute Cranial Epidural Hematoma Related To Breech Delivery In A Neonate With Congenital Anomaly

H Suslu, I Gulec, M Bozbuga

## Citation

H Suslu, I Gulec, M Bozbuga. *Acute Cranial Epidural Hematoma Related To Breech Delivery In A Neonate With Congenital Anomaly*. The Internet Journal of Neurosurgery. 2005 Volume 3 Number 2.

## Abstract

**Background:** Cranial epidural hematomas of neonate due to birth trauma are relatively common lesions. Due to breech delivery in neonate with congenital anomaly is extremely rare, and only one case has been reported in the literature. We present here a case of acute epidural hematoma that was related to breech delivery in a neonate infant with Chiari II and meningomyelocele along with the review of the previously published cases.

**Case:** Our case is a full term-male neonate born with breech delivery. Meningomyelocele in thoracic region was discovered at birth. Cranial computed tomography scan done 6 hours following the breech delivery and showed ventriculomegaly and right parietal epidural hematoma. Evacuation of the epidural hematoma and repair of meningomyelocele have performed 7 h after the birth. The patient got excitus because of sepsis two weeks after the birth.

**Conclusion:** Due to birth trauma different natured cranial pathologies may grow up in the neonate. Among these pathologies epidural hematoma includes only a little part. Especially in neonates having congenital anomaly and having had a traumatic birth like breech delivery, cranial lesions should be memorized, appropriate diagnosis and treatment should be applied promptly.

## INTRODUCTION

Birth injuries are associated with mechanical forces producing hemorrhage, oedema, tissue disruption or alteration of during the intrapartum period. A range of injuries to the scalp, skull or brain may be seen in babies following normal or assisted vaginal delivery. Maternal and fetal factors which increase the risk of cranial trauma include cephalopelvic disproportion, malpresentation, large gestational weight of the baby and delivery by forceps or vacuum extraction. The most common malpresentation was breech delivery that often brought birth trauma together.

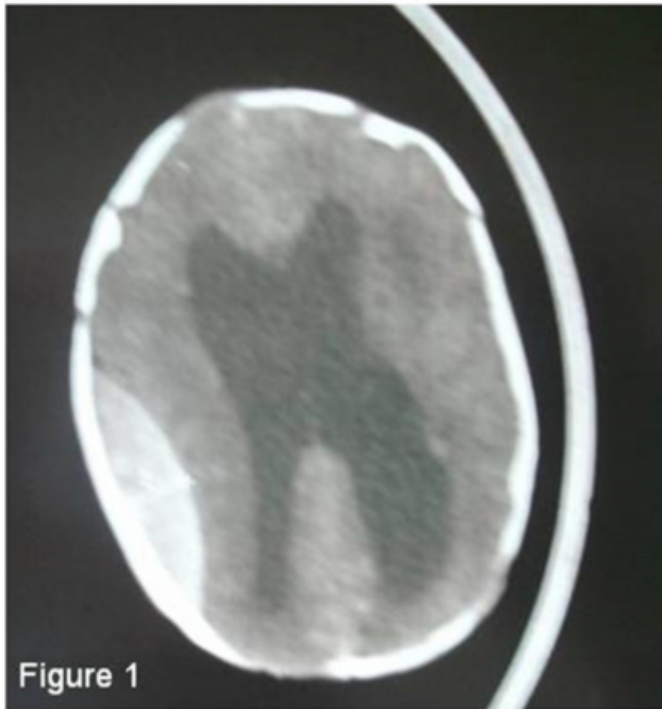
Epidural hematoma (EDH) is a rare cranial pathology in neonate and accounting for % 0.06- 2 of neonate intracranial hemorrhage.<sup>1,2</sup> The most common cause of EDH in neonate is bleeding due to birth trauma.<sup>3</sup> We present here a case of acute EDH that was related to breech delivery in a newborn infant with Chiari II and meningomyelocele (MM). Up to now in the literature only one case which developed EDH due to breech delivery in neonate with hydrocephalus (HCP) and MM has been reported<sup>4</sup> and our patient is the second case with breech delivery and congenital anomaly.

## CASE REPORT

Hispanic male infant was born to a 36 year-old gravida 5, para 1 mother via breech delivery. Mother had not done the routine examinations during her pregnancy that's why there is not any information whether the fetus had congenital anomaly before the birth. He was a full term baby. He weighed 2500 gr. and a head circumference of 35 cm at birth. Neurological examination was demonstrated paraplegia, club foot and absence deep tendon and anal reflex. Anterior fontanel had full and taut. Pupils were equal and reacted to light. MM in thoracic region was discovered at birth. Cerebrospinal fluid had leaked from the MM. Cranial computed tomography (CT) scan was done 6 hours following the breech delivery and showed ventriculomegaly and right parietal EDH which was compressing right lateral ventricle (Fig 1).

**Figure 1**

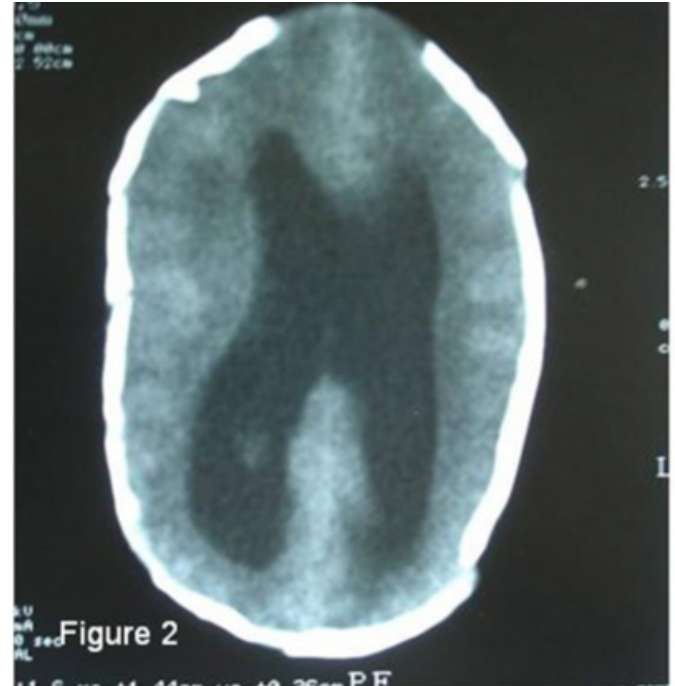
Figure 1: CT scan shows ventriculomegaly and EDH located in the right parietal region.



There was not skull fracture and cephalhematoma. We confirmed Chiari II malformation and thoracic MM by magnetic resonance imaging (MRI) on the 7 hours after his birth (Fig 2).

**Figure 2**

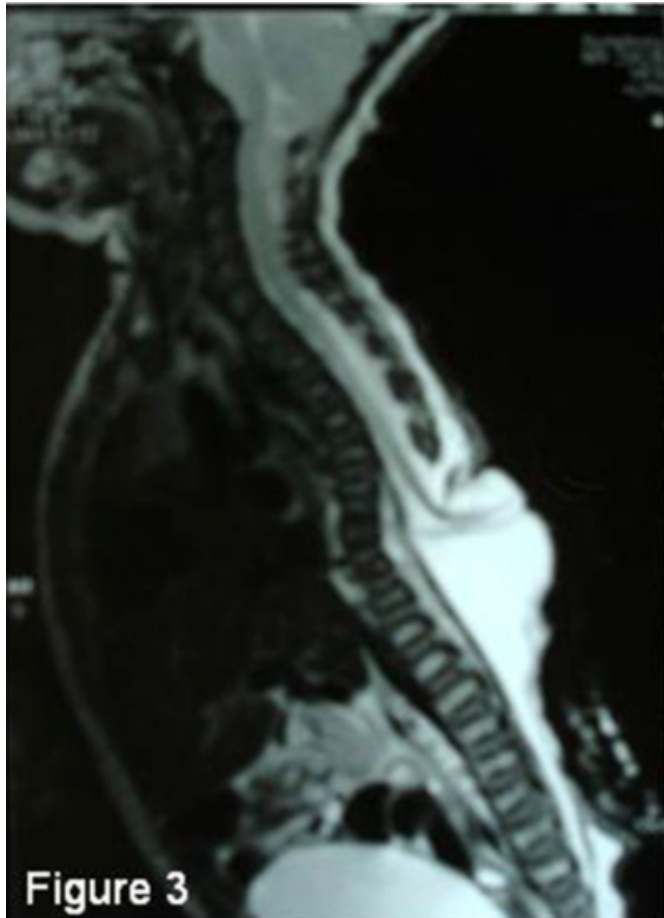
Figure 2: postoperative CT scan shows that hematoma was completely evacuated.



All other laboratory findings, including coagulation test results were normal. We performed evacuation of the EDH and repair of MM on the 9 hours after birth. Coagulated blood remained in the epidural space. During the operation, skull fracture and cephalhematoma was not found and, any active bleeding site was not confirmed. The hematoma was completely evacuated and did not recur after operation. After the operation anterior fontanel relaxed. There was not any wound problem in the MM region. Yet, on the fifth day high fever and sepsis was observed and laboratory findings suggested disseminated intravascular coagulation (DIC). The neonate died on the tenth day after the birth.

**Figure 3**

Figure 3: Sagittal T-weighted MRI. The MRI shows Chiari II malformation and thoracic meningocele.



## DISCUSSION

The neonatal head is subject to significant compressive forces as it passes through the birth canal. A small degree of hemorrhage into the layers of the falx of the cerebellum or the cerebellar tentorium is a common finding following vaginal delivery; but, large, clinically symptomatic hematomas are quite rare.<sup>5,6</sup> The most common intracranial lesion diagnosed clinically from delivery in neonate was subdural hemorrhage (%73), followed by subarachnoid (20%) and intracerebral (20%) hemorrhage; intraventricular hemorrhage, epidural hemorrhage and skull fractures were less common.<sup>7</sup>

Neonate's EDH may be resulting from arterial or venous. The rarity of EDH in neonates as compared with children or adults may be explained by the absence of the middle meningeal artery groove which makes the middle meningeal artery less susceptible to injury and by the tight attachment between the dural membrane and periosteum and the poor development of the dura mater vessels in neonates which

makes the formation of EDH unlikely.<sup>8,9,10</sup> During the surgical evacuation there are some cases whose middle meningeal artery had active bleeding and was coagulated during the operation. Oppositely, in some surgical and autopsy series, it has been showed that the existing EDH was related to the venous bleeding.<sup>11,12</sup> When there is a fracture, venous bleeding from the diploe will accumulate intra- and extracranially, forming both extradural and subperiosteal hematomas, or EDH is a result of laceration of the superior sagittal or transvers sinus secondary to compressive forces applied to the neonate's head as it passes through the birth canal.<sup>1,3,6</sup>

It is not generally met deterioration in neonate with EDH clinically. In the following examinations, the enlargement of the neonate's head circumference or tenseness in the anterior fontanel may be a sign of increased intracranial pressure. Because of the expansibility of the skull and the compliance of the brain of neonates, EDH may initially go undetected.

The clinical characteristics of neonatal EDH occurring during delivery in literature is rare. Generally there was no sex predominance in EDH of neonate.<sup>13</sup> But in the neonates in whom EDH grows up because of breech delivery, male dominance is seen.<sup>4,8,11</sup> The average birth weight was 3400g and the average head circumference was 36.5 cm.<sup>13</sup> Usually association skull fracture and cephalhematoma were observed in cases. Injury can be located anywhere in the cranium but most commonly in the parietal and frontal regions.<sup>8,13</sup> EDH may occur an associated skull fracture in 50% to 66% of cases.<sup>8,13</sup> Cephalhematoma is often accompanied by liquid EDH and is seen in nearly %16.6-75 of the cases.<sup>2,8,13</sup>

Instrumented vaginal delivery (forceps and vacuum) was most reason of EDH in neonate, but breech and cesarean section (C-section) delivery is rare reason. Only four cases of EDHs following breech delivery have been reported.

<sup>4,8,11</sup> EDH is rare in neonate with congenital anomaly and congenital anomaly exists only in 6 reported EDH cases of neonates (Table 1) HCP, MM, Chiari II malformation, cranial encephalocele are the congenital anomalies that accompanies EDH.<sup>2,4,13,14,15</sup> The possibility of finding EDH of neonate and HCP together is %15.<sup>13</sup> In the cases in which HCP is found, the probability of head circumference's being big too much, so neonatal head is imposed to more compression force during the birth trauma.<sup>13</sup> Among the reported EDH of neonates only one case was breech delivery with HCP and MM, and the patient died after surgery.<sup>8</sup> Our

case reported breech delivery with Chiari II and MM and is the second case in related literature.

## Figure 4

Table 1: The neonates who had breech delivery and congenital anomaly up to now in literature are listed above. (M: male, F: female, C-section: cesarean section, FT: frontotemporal, PF: frontoparietal, P: parietal, T: temporal, SDH: subdural hemorrhage, IVH: intraventricular hemorrhage, SAH: subarachnoid hemorrhage, HCP: hydrocephalus, MM: meningomyelocele)

Reference	Sex	Delivery	Site	Skull fracture	Cephal hematoma	Therapy	Result	Other lesion
(11)	M	Breech	FT	(+)	none	none	died	SDH, IVH
(4)	M	Breech	PF	(-)	none	none	died	SAH
(8)	M	Breech	P	(-)	(+)	removal	died	HCP, MM
(15)	M	Breech	P	(-)	(+)	none	good	IVH, ICH
(15)	M	Vaginal	T	(+)	(+)	Removal	good	Chiari II, HCP, frontal encephalocel
(2)	None	none	P	(+)	none	none	good	Chiari II, HCP
(14)	M	C-section	P	(-)	(+)	removal	good	Chiari II, HCP, MM
(13)	M	C-section	F	(-)	(+)	Disk trephine removal	Moderate neurological deficit	HCP
	F	Instrumented vaginal	P	(+)	(-)		Severe neurological deficit	HCP
Our case	M	Breech	P	(-)	(-)	removal	died	Chiari II, HCP, MM

Treatment of EDHs in neonate is surgical or nonsurgical. Most hematomas are self-limiting and do not require any therapeutic intervention. A small EDH can be treated conservatively with serial surveillance computed tomographic scans. <sup>2,8</sup>A conservative approach was chosen in patients with a small, isolated hematoma (less than 1 cm thick and less than 4 cm long in anteroposterior plan) with no clinical deterioration. <sup>13</sup>Nonsurgical treatment modalities is aspiration through the cranial fracture, percutaneous epidural trapping, ultrasound-guided needle aspiration. <sup>1,8,13</sup>In the fracture-consisting cases because there may be relation between EDH cephalhematoma, needle aspiration may be effective. <sup>8,16,17</sup> If this is not successful, a craniotomy is necessary. The main indications for craniotomy were based on the thickness of the brain, increase of head circumference in the following examinations, tenseness of anterior fontanel and an eventual associated depressed cranial fracture or HCP. <sup>9,13,14</sup>

Most cases' having been treated appropriately has produced good outcomes. In the %66 of the cases which had medical or surgical treatment during a long-term-following, had a normal neurological and psychomotor examination. But moderate-severe neurological deficits or psychomotor disability rate is %25, severe neurological or psychomotor disability rate is %9; congenital anomaly and seizures effect

the long-term-followings negatively. <sup>4,8,11,13</sup>Breech delivery is a factor that effects the outcome negatively and the rate of mortalite is %75 in EDH of breech delivery neonate. <sup>4,8,11</sup>

Our case is interesting in some ways. First reason is the growing of cranial EDH due to the breech delivery, second one is that the neonate has congenital anomaly. Physical examination after the duration of birth and anterior fontanel tenseness intracranial pressure increase should be warning about the head trauma. But extradural hematoma may be come across without the existence of cephalhematoma or cranial fracture. In the examination after birth it is thought that in our patient who has MM, the reason for anterior fontanel tenseness is HCP and so in the cranial CT scan, EDH is diagnosed as incidental. After the operation the tenseness in the anterior fontanel decreased and fontanel relaxed. In our case despite HCP, head circumference is on tolerable limits. But with the coming of the breech delivery during the birth which causes trauma, a hematoma may have developed. In our case, congenital anomaly and breech delivery are seen together and this is what increases the risk of EDH.

## References

1. Hovind K: Traumatic birth injuries. In Raimondi AJ, Choux M, Di Rocco CD (eds): Head Injuries in the Newborn and Infant. New York, Springer-Verlag 1986;87-109.
2. Lam A, Cruz G, Johnson I. Extradural hematoma in neonates. J Ultrasound Med 1991; 10: 205-209.
3. Leggate JR, Lopez Ramos N, Genitani L, et al: Extradural hematoma in infants. Br J Neurosurgery 1989;3: 533-539.
4. Andoh Y, Wakai S, Inoh S, Ochiai C, Nagai M. Extradural hematoma in neonates- report of two cases. Nerv Syst Child ( Kobe ) 1988; 13:177-182.
5. Leblanc R, O'Gorman A: Neonatal intracranial hemorrhage: A clinical and serial computerized tomographic study. J Neurosurg 1980; 53:642-651.
6. Raimondi AJ: Posttraumatic cerebral vascular injuries. In Raimondi AJ, Choux M, Di Rocco CD (eds): Head Injuries in the Newborn and Infant. New York, Springer-Verlag 1986; 233-239.
7. Pollina J, Dias MS, Li V, Kachurek D, Arbesman M. Cranial birth injuries in term newborn infants. Pediatric Neurosurg 2001; 35:113-119.
8. Negishi H, Lee Y, Itoh K, Suzuki J, Nishino M, Takada S, Yamasaki S. Nonsurgical management of epidural hematoma in neonates. Pediatr Neurol 1989; 5:253-256.
9. Gama CH, Fenichel GM. Epidural hematoma of the newborn due to birth trauma. Pediatr Neurol 1985;1:52-53.
10. Vachharajani A, Mathur A. Ultrasound-guided needle aspiration of cranial epidural hematoma in a neonate treating a rare complication of vacuum extraction. Am J Perinatal 2002;19:401-404.
11. Takagi T, Nagai R, Wakabayashi S: Extradural hemorrhage in the newborn as a result of birth trauma. Child's Brain 1978; 4: 306-318.
12. Merry GS, Stuart G. Extradural hematoma in the neonate. Case report. J Neurosurg 1979; 51:713-714.
13. Heyman R, Heckly A, Magagi J, Pladys P, Hamlat A:

Intracranial epidural hematoma in newborn infants: clinical study of 15 cases. *Neurosurgery* 2005; 57:924-929.

14. Akiyama Y, Moritake K, Maruyama N, Takamura M, Yamasaki T. Acute epidural hematoma related to cesarean section in a neonate with Chiari II malformation. *Child's Nerv Syst* 2001; 17:290-293.

15. Anegawa S, Hayashi T, Torigoe R, Hashimoto T. Meningomyelocele associated with cranium bifidum: rare coexistence of two major malformations. *Child's Nerv Syst*

1993; 9:278-281.

16. Aoki N: Epidural hematoma communicating with cephalohematoma in a neonate. *Neurosurgery* 1983; 13: 55-57.

17. Aoki N: Epidural hematoma in the newborn infants. Therapeutic consequences from the correlation between hematoma content and computed tomography features: A review *Acta Neurochir (Wien)* 1990; 106: 65-67.

**Author Information**

**Hikmet Turan Suslu, M.D.**

2nd Neurosurgery Clinic, Lütfi Kırdar Kartal Education and Research Hospital

**Ilker Gulec, M.D.**

2nd Neurosurgery Clinic, Lütfi Kırdar Kartal Education and Research Hospital

**Mustafa Bozbuga, M.D., Ph.D.**

2nd Neurosurgery Clinic, Lütfi Kırdar Kartal Education and Research Hospital