

Metastatic Choriocarcinoma Masquerading As An Intracerebral Arteriovenous Malformation Bleed

P Shrestha, U Devkota, R Panth

Citation

P Shrestha, U Devkota, R Panth. *Metastatic Choriocarcinoma Masquerading As An Intracerebral Arteriovenous Malformation Bleed*. The Internet Journal of Neurosurgery. 2009 Volume 7 Number 2.

Abstract

Choriocarcinoma is a highly malignant rare tumor known to metastasize to the brain. We describe a case of a twenty-two year old unmarried female who did not have past history of pregnancy presenting to us with intra-cerebral haemorrhage with angiographic findings suggestive of arteriovenous malformation (AVM). Histology of the high parietal lesion confirmed it to be a choriocarcinoma. Bleeding in a metastatic choriocarcinoma should therefore be considered in the differential diagnosis of intra-cerebral bleeding in females of child bearing age.

INTRODUCTION

Choriocarcinoma (gestational / non gestational) comprises the malignant spectrum of trophoblastic diseases. Gestational choriocarcinoma is a rare but one of the most malignant growths arising from the body of the uterus which occurs after approximately 1:50,000 term pregnancies and 1 in 30 hydatidiform moles.¹ Non gestational choriocarcinoma is an even rare entity which occurs as a part of mixed germ cell tumors in the ovaries in prepubertal girls and the testes in males. Primary intracranial choriocarcinoma have also been reported to occur in the pineal and the parasellar regions.² Choriocarcinoma is a vascular tumor with high incidence of metastases, the most common being lungs, brain and liver and rarely gastrointestinal tract, kidney, spleen, genital tract and the lymph nodes.¹ Other malignancies reported to metastasize to brain are bronchial carcinoma, melanoma and renal cell carcinoma.³ Central Nervous System (CNS) metastases from gestational choriocarcinoma have been reported to range from 3 to 28%⁴ but that from non gestational choriocarcinoma has not been reviewed. The CNS metastases of the choriocarcinoma have been reported to present as parenchymal haemorrhage, subarachnoid hemorrhage from rupture of neoplastic aneurysms, carotid cavernous fistula, infarct due to tumor embolus, subdural hematoma and also as an arteriovenous malformation bleed.^{5,6}

CASE REPORT

A twenty-two year-old unmarried female presented to the casualty with a four-hour history of sudden, severe headache

associated with vomiting and generalized seizure. There was no significant past medical history. On arrival, her heart rate was 62 beats per minute and the blood pressure was stable at 103/70 millimeters of mercury. Neurologically, she was extending to pain with fixed dilated pupil on the right and 3 millimeter sluggishly reacting pupil on the left. Loading dose of phenytoin and mannitol were started and the patient was immediately intubated, put on a ventilator and taken to the radiology suite. Emergency computed tomography scan revealed a right posterior-parietal bleed of around thirty milliliters, with perilesional edema and a midline shift of around one centimeter. (Fig.1) Cerebral angiogram that immediately followed showed a tangle of blood vessels being fed by the right anterior cerebral artery suggestive of an arteriovenous malformation (AVM). (Fig. 2) Her chest X-ray was unremarkable.

Patient was immediately taken to the operation theatre. Clinical assessment immediately before proceeding with craniotomy revealed that she had by then had bilateral fixed dilated pupils. However, as the pupillary dilation was very recent, the team proceeded with surgery. Via a right parietal craniotomy, the hematoma was evacuated and a suspicious, solid, vascular lesion in the postero-lateral wall of the hematoma cavity, presumed to be the nidus of the AVM was excised. The brain was rather tense, and post operatively, the patient was continued on elective ventilation and osmotic diuretics. Unfortunately, the pupillary size did not regress; she did not have any neurologic recovery and eventually succumbed the following day. On religious and cultural

grounds, an autopsy was decided against by the family.

Histopathological examination revealed tumor fragments associated with extensive necrohaemorrhage. There were sheets of two varieties of cells, one multinucleated tumor cells with huge, hyperchromatic nuclei and the other atypical large mononuclear cells with prominent nucleoli. They were diagnosed as syncytiotrophoblasts and cytotrophoblasts respectively and a diagnosis of choriocarcinoma was made.(Fig. 3)

Figure 1

Figure 1.

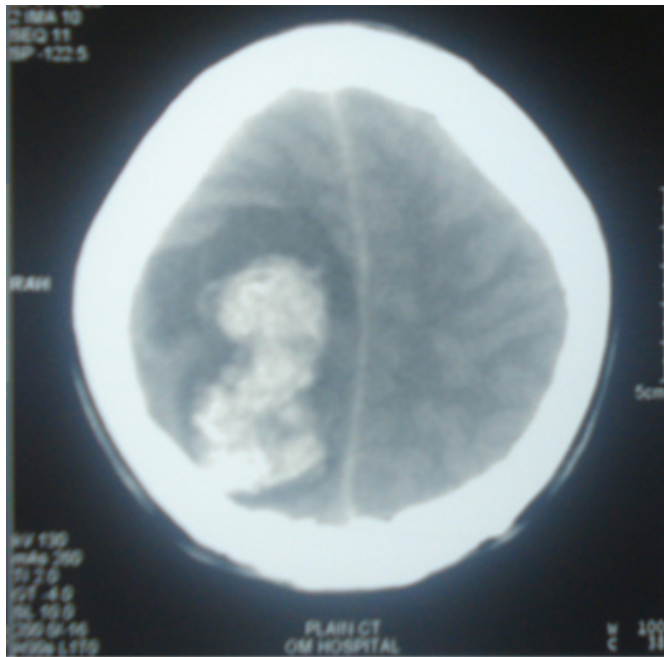


Figure 2

Figure 2.

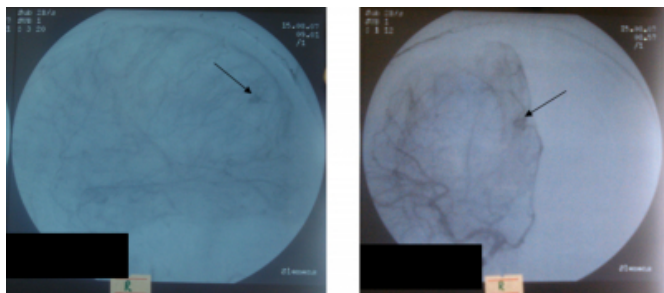
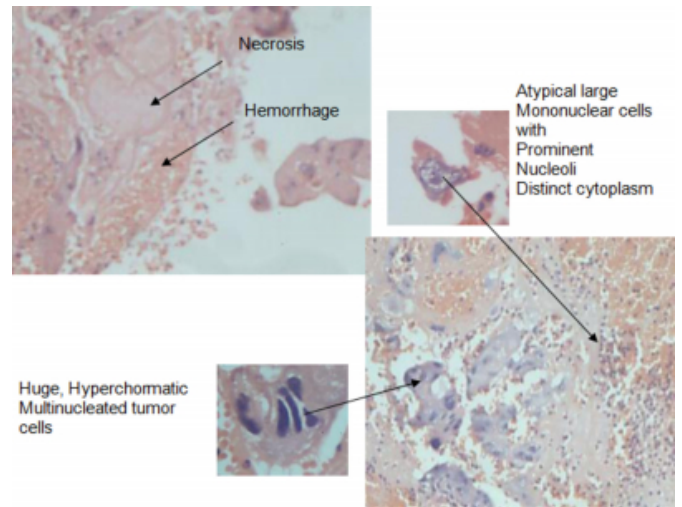


Figure 3

Figure 3.



DISCUSSION

The marital status and obstetric history in this case are suggestive of a non-gestational choriocarcinoma; but gestational choriocarcinoma cannot be ruled out in the absence of accurate history to rule out a possible spontaneous or induced abortion in the past and diagnostic investigations as ultrasonography of the abdomen to locate the primary. In a retrospective analysis of ten cases of cerebral metastatic choriocarcinoma, history of pregnancy/abortion was present only in five cases.⁷ Primary intracranial is unlikely here as other criteria associated with this condition as precocious puberty, hypopituitarism were absent.² The site of the bleed and the location in the angiogram are also not suggestive.

Early diagnosis of a case of choriocarcinoma is very important as 100% cure rate in the low-risk group with Methotrexate alone and 90% cure rate with combined chemotherapy with Etoposide, Methotrexate, Actinomycin, Cyclophosphamide and Oncovin (EMA-CO) in the high-risk group have been reported.⁸ Of the many criteria in the WHO prognosis scoring system for gestational trophoblastic diseases, brain metastasis alone increases the likelihood of the patient falling in the high risk group.¹ Intrathecal administration of methotrexate achieves high concentration in the CSF but simultaneous intravenous methotrexate is also essential for penetration into tumors deep in the brain.^{1,8}

Clinicians need to be aware that intracranial metastases of choriocarcinoma can present with intracranial and subarachnoid haemorrhages, seizures, focal neurologic deficits and even headache, in women who have been

pregnant. A serum: cerebrospinal fluid (CSF) β -HCG ratio of less than 60:1 is a sensitive indicator of CNS metastasis, and in Charing Cross Hospital, this screening test could detect CNS metastasis in 15 patients before the development of signs and symptoms.⁴ Serial CSF β -HCG can be useful to rule out progressive disease from contamination with blood from the haemorrhage, as the decreased serum: CSF β -HCG ratio would normalize in serial studies if it were due to the latter.

Investigation for the primary is also essential regarding the treatment modality as non-gestational choriocarcinoma is rarely seen in pure form, and is a part of mixed germ cell tumor, which require radiotherapy whereas gestational choriocarcinoma occur in pure form and respond remarkable well to chemotherapy. Secondaries of gestational choriocarcinoma can be detected by positron emission tomography (PET) scan.⁹

CONCLUSION

Though choriocarcinoma is a rare malignancy, it should be considered as a differential diagnosis when a female in the reproductive age group presents with intracranial haemorrhage, more so when she gives history of hydatidiform mole in prior pregnancies. Decreased serum: CSF β -HCG ratio further suggests intracranial choriocarcinoma. Early diagnosis of the condition can lead to remarkable outcome with timely institution of proper chemotherapy⁴ hence clinicians need to have a high level of

suspicion in women who have been pregnant when they present with minor complaints as headache and seizure and severe complaints as intracerebral and subarachnoid haemorrhages.

References

1. Padubidri VG, Daftary SN.ed's. Howkins and Bourne Shaw's Textbook of Gynaecology: 13th ed. Elsevier 2004: 248-59
2. Rosalind P, Bala D, Sharr MM: Primary Intracranial Choriocarcinoma. J Neurology, Neurosurgery, and Psychiatry 1986; 49: 93-95
3. Kondziolka D, Bernstein M, Resch L et al; Significance of haemorrhage in brain tumor. Clinicopathological study. J neurosurg 1987;67:852-857
4. Athanassiou A, Begent RH, Newlands ES, Parker D, Rustin GJ, Bgshawke KD: Central nervous system metastases of choriocarcinoma. 2 years' experience at Charing Cross Hospital. Cancer 1983, 52:1728-1735
5. Brandon RG and Mustafa BK: Spontaneous acute subdural hematoma as an initial presentation of choriocarcinoma: A case report. J Medical Case Reports 2008,2:211
6. Fadli M, Lmejjati M, Amarti A, El Hassani MR, El Abbadi N, Bellakhdar F. Metastatic and haemorrhagic brain arteriovenous fistulae due to a choriocarcinoma. Case report. Neurochirurgie. 2002 Feb; 48(1):39-43
7. Suresh TN, Santosh V, Shastry Kolluri VR, Jayakumar PN, Yasha TC, Mahadeven A, Shankar SK. Intracranial haemorrhage resulting from unsuspected choriocarcinoma metastasis. Neurol India. 2001 Sep;49(3):231-6
8. Newlands ES, Paradinas FJ, Fisher RA: Recent Advances in Gestational Trophoblastic Disease. Hematol Oncol Clin North Am. 1999 Feb; 13 (1):225-44
9. Huang CY, Chen CA, Hsieh CY, Cheng WF. Intracerebral haemorrhage as initial presentation of gestational choriocarcinoma: a case report and literature review. Int J Gynecol Cancer. 2007 Sep-Oct; 17(5):1166-71

Author Information

Pratyush Shrestha

Neurosurgical Resident, National Institute of Neurological and Allied Sciences

Uendra P Devkota, FRCS, FNAMS

Professor, National Institute of Neurological and Allied Sciences

Rajesh Panth, MD

Consultant Pathologist, National Institute of Neurological and Allied Sciences