

Teraogenic Effect Of Beer And Palm Wine On Histology Of Fetal Cerbral Cortex Of Wistar Rats

M Eluwa, C Njoku, T Ekanem, A Akpantah

Citation

M Eluwa, C Njoku, T Ekanem, A Akpantah. *Teraogenic Effect Of Beer And Palm Wine On Histology Of Fetal Cerbral Cortex Of Wistar Rats*. The Internet Journal of Health. 2008 Volume 9 Number 1.

Abstract

Beer and palm wine are two alcoholic beverages that play an important role in local ceremonies and other social life of Nigerians especially in the Southern part of the country. This study was to compare the teratogenic effect of maternal administration of various doses of beer and fermented palm wine on the histological features of the fetal cerebral cortex of wistar rats. The percentage of alcohol in beer was experimentally found to be 6.1%. The estimated alcohol content in five days fermented palm wine was 4.5%. Female rats of proven fertility were caged with sexually matured male rats. The presence of sperm in the vaginal smear obtained the following morning confirmed coitus and the sperm positive day was designated as day zero of pregnancy. Oral doses of 4ml, 8ml of beer and 4ml, 8ml of five days fermented palm wine was administered respectively from 7th to 13th day of gestation. On the 20th day of gestation, the rats were sacrificed and the fetuses removed. The cerebral cortex were removed and fixed in Bouin's fluid, stained with Haematoxylin and Eosin method and examined under the microscope. Histological result showed marked distortion and disappearance of the intermediate zone of the developing cerebral cortex, a merging of the subventricular and intermediate zone and reduction in the cortical and subventricular zones in the treated groups. These observations were more severe in sections from rats whose mothers received 8ml of beer and 8ml of 5days fermented palm wine. Our results suggest that fermented palm wine and beer is teratogenic to the developing cerebral cortex of wistar rats.

INTRODUCTION

Beer and palm wine are alcoholic beverages. Alcoholic beverages have been classified based on the percentage alcoholic content as (a) Brewed, (b) Fermented, (c) Distilled. The brewed beverages which are mainly prepared from malt and hops include beer, ale and stout. Palm wine is milky in appearance and is obtained from the fermentation of sugary sap of various palm species in Nigeria. Palm wine is usually obtained from the sap of *Raphia Vinifera*, *Raphia Hooperi* (*raphia palm*) and *Elaeis Guineensis* (*oil palm*) by methods describe by ¹²³. Beer and palm wine which are alcoholic beverages play an important indispensable role in local ceremonies such as rituals, traditional marriages and other social life in Nigeria. They are consumed by both men and women including pregnant women. Traditionally palm wine is given to women after childbirth to help stimulate the production of milk and to young women in the fattening rooms (Oral communication). Alcohol is a teratogen ⁴. There has been no teratogenic agent yet studied in man which has shown a clear threshold effect, where the substance could be considered safe at a particular level, beyond which its teratogenic effect begins to take hold, and the alcohol is no

exception ⁵. Alcohol is a low molecular substance and is therefore quite capable of crossing the placental barrier and entering the fetus, causing the level of alcohol in the fetus to be approximate to that of the mother ⁹. Adverse health effects that are associated with alcohol exposed pregnancies include miscarriage, premature delivery, low birth weight, sudden infant syndrome, and prenatal alcohol – related conditions such as fetal alcohol syndrome. Fetal alcohol syndrome is one of the leading causes of mental retardation, and is directly attributed to drinking during pregnancy. Fetal alcohol syndrome is characterized by growth retardation, facial dysfunction such as learning abnormalities and lower intelligent Quotient (IQ) as well as behavioural problems ⁷.

Since alcoholic beverages especially palm wine has gained a lot of cultural interest and its consumption rate has been on the increase among the educated and non-educated pregnant women in our society. Most of the educated pregnant women prefer beer because it is more refined than palm wine. The cerebral cortex is most directly responsible for consciousness with essential role in perception, memory, thoughts, mental ability and intellect. This study seeks to

find out if the alcoholic constituents of beer and palm wine may be teratogenic to fetal cerebral cortex of wistar rats.

MATERIALS AND METHODS

Twenty five female wistar rats weighing about 180 – 200g were used in this study. The female rats were divided into five groups labeled A, B, C, D and E, each group consisting of five rats. Group A was the control group, with group B, C, D and E as the experimental groups. Female rats of proven fertility determined by daily vaginal lavage were caged overnight with sexually matured male rats of the same strain. The following morning, the vaginal smear was done to check the presence of sperm in the female tract. The presence of spermatozoa signified day zero of pregnancy. Groups B, C, D and E female rats were given 4ml, 8ml of beer and 4ml, 8ml of five days fermented palm wine on the 7th through 13th day of gestation through an oral route with an aid of orogastric tube. The control group A animals received corresponding volumes of distilled water on the corresponding days of gestation. Pregnancy was terminated on the 20th day of gestation by chloroform inhalation method and the fetuses collected by uterectomy. The fetuses were blotted dry and examined for possible gross malformations. The cerebral cortex of each was dissected out and fixed in Bouin,s fluid for haematoxylin and eosin staining method.

RESULTS

HISTOLOGICAL CHANGES

Histological study of the cerebral cortex using haematoxylin and eosin staining method showed in the control group A, five basic histological zones of the developing cerebral cortex. These zones, from outwards inwards are marginal, cortical, intermediate, subventricular and ventricular zones (Plate 1). Hypoplasia of the cells of the cortical, subventricular and ventricular zones, disruptions of the epithelial lining of marginal zone and reduction in the cortical and subventricular zones were seen in the groups B and C which received 4ml and 8ml of five days fermented palm wine (Plate 2, Plate 3).

In group D animals that were given 4ml beer, there was disappearance of the intermediate zone, distortion of cells of the ventricular zone, hypoplasia of cell and reduction of the cortical zone (Plate 4). There was cell necrosis in the marginal zone, merging of the intermediate and subventricular zone in group E which received 8ml of beer (Plate 5).

Figure 1

Plate 1: Photomicrograph of a fetal cerebral cortex from control rats. The cerebrum showed five basic histological zones. Marginal zone (MZ), cortical zone (CZ), intermediate zone (IZ), subventricular zone (SZ) and ventricular zone (VZ). Mag x 500 (H

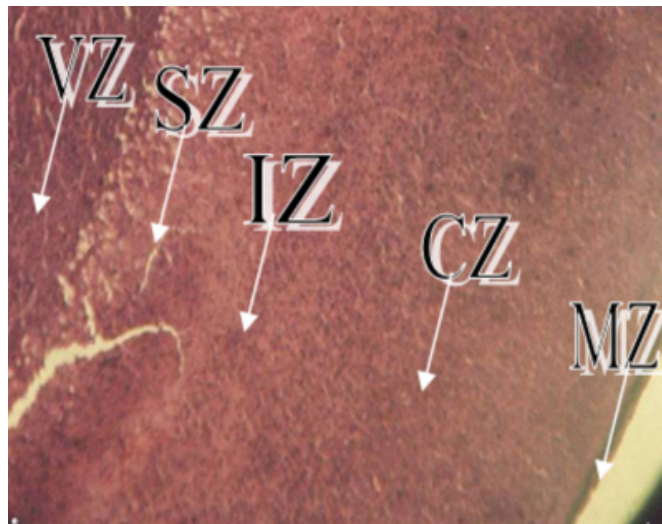


Figure 2

Plate 2: Photomicrograph of a fetal cerebral cortex from rats treated with 4ml of palm wine showing disruption of the marginal zone (DMZ), and hypoplasia of the cortical zone cells (HCZ), and the cells of the intermediate and subventricular zones are less compacted. Mag. x500 (H&E).

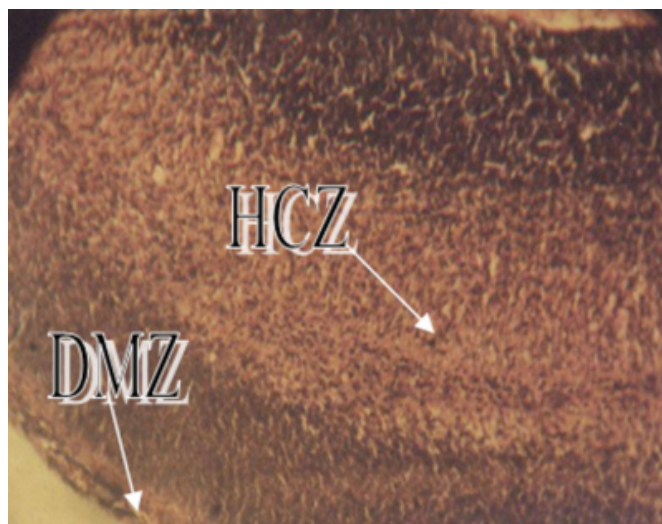


Figure 3

Plate 3: Photomicrograph of the fetal cerebral cortex from rats treated with 8ml of 5days fermented palm wine showing reduction of the cortical (RCZ), subventricular zone (RSVZ), and ventricular zone (RVZ). Mag. x 500 (H&E).

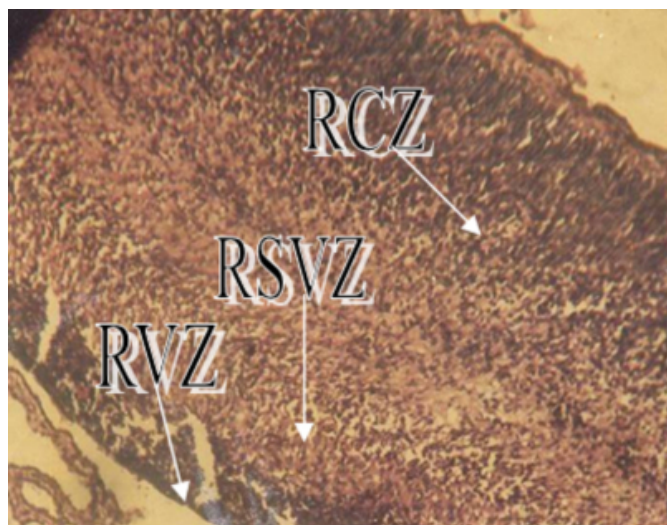



Figure 4

Plate 4: Photomicrograph of the fetal cerebral cortex from rats treated with 4ml of beer showing merging of the intermediate zone (MIZ) and subventricular zone (MSZ). Mag. x500 (H&E).



Figure 5

Plate 5: Photomicrograph of a fetal cerebral cortex from rats treated with 8ml of beer showing disappearance of the intermediate zone (DIZ) and cell necrosis of the marginal zone (NMZ). Mag. x500 (H&E).



DISCUSSION

Following the administration of various doses of star beer and palm wine from 7th through 13th day of gestation, the most critical period of gestation, the section of the cerebral cortex showed reduction in cell population as shown by the reduction in thickness in some zones, disappearance of intermediate zone and disruption of the marginal zone and this was more pronounced in group D and E that received 4ml and 8ml of beer. This changes in histological features may have been due to the detrimental effect of alcoholic content of beer and palm wine on cerebral cortex due to the vulnerability of fetal brain during critical period of gestation to alcohol. The development and functions of the cerebrum were adversely affected. Cells of the cerebral cortex are related to the integration of sensory information and the initiation of voluntary motor responses ⁸.

The findings correlates to the findings by several workers that alcohol has the most detrimental effect on both brain development and function ⁹.

The infant is not only born with a brain smaller in size, but the teratogenic effect of alcohol reduces the number of brain neurons, as well as alter their distribution. This results in mental deficiency of varying degrees, from milder behavioural problems to obvious mental handicap ⁹. The malformation of the nervous system in experimental animals have mostly been reported to occur only when the teratogen is administered at the critical period of fetal development,

mainly, shortly before or during the closure of the neural groove¹⁰. This sensitive period is the time of development during which the nervous system is highly susceptible to the effects of harmful internal and external conditions thereby causing various forms of damage to the system in the neonatal period¹¹.

From this study the reduction in the cerebral cortex layers and the merging and disappearances of some layers may have been due to neuronal damage and loss.¹² stated that the hallmark of the central nervous system damage is FAS/FAE is neuronal damage and loss. The ultra structure of neurons in the sensory and motor cortex showed delayed maturation with dystrophic and destructive changes following prenatal alcohol exposure. Ethanol has been shown to decrease the synaptic density in the molecular layer (layer 1) of the motor cortex of alcohol exposed rats¹³. This part of the brain is responsible for the motor movement in humans. The adverse effects of alcohol may be responsible for motor problems seen in children with FAS¹⁴.

From this study, beer had the most detrimental effect on the cerebral cortex than palm wine. It can be concluded from the result of this study that maternal administration of beer and palm wine from 7th through 13th day of gestation has teratogenic effect on the rats fetal cerebral cortex. Thus the public should be enlightened regarding dangers of alcoholic beverages used during pregnancy and the possible adverse outcome associated with prenatal alcohol exposure. This will go a long way to ensuring that children are guarded against FAS and mental retardation.

References

1. Bassir, O (1968). Some Nigerian wines. West Africa Journal Biol. Appl. Chem. 10: 41 - 45.
2. Faparusi, S. I (1966). A biochemical study of palmwine from different varieties of *Elaeis guineensis*. Ph.D Thesis, University of Ibadan, Nigeria.
3. Okafor, N (1972). The source of the micro-organisms in palmwine. Sym. Nig. Soc. Microbiology. 1: 97.
4. Vorhees CV, Mellnew E (1987). Behavioral teratogenesis; Long term influences on behavior from early exposure to environmental agents. In: Handbook on infant development, 2nd edition, Ed: JD. Osofsky, Pp 913 – 917, New York.
5. Smith, D. W (1979). Alcohol effects in fetus: In: Fetal Drug Syndrome; Effects of Ethanol and Hydantoins. Pediatrics in Review 1, American Academy of Pediatrics
6. Streissguth AP, Barr H. M, Sampson PD, Bookstein FL, Darby BL (1989). Neurobehavioral effects of prenatal alcohol. Part 1, Research Strategy (Review of the Literature). Neurotoxicology and teratology, 11; 461 -476.
7. Centers for Diseases Control and Prevention (CDC). National Center on Birth Defects and Developmental Disabilities, Division of Birth Defects and Developmental Disabilities. Fetal Alcohol Syndrome Prevention Team FAS Fact Facts. Available at <http://www.cdc.gov/ncbddd/fas/faqs.htm>. accessed March 18, 2004.
8. Luiz, C. J and Jose C (2005). Basic Histology Text and Atlas. Eleventh Edition. The McGraw Hill Companies. Appleton & Lange.
9. Streissguth AP (1990). Prenatal alcohol-induced brain damage and long term postnatal , consequences Alc. Clin. Exp Res, 14(5): 648 – 476.
10. Singh, S; Sensharma, G. C and Sangal, A. K (1972). Malformations of the brain induce by cyclophosphamide in rats. Neurology India. Vol. XX No. 3; 152 – 157.
11. Ezurumlu, R. S and Killackey, H. P (1982). Critical and sensitive periods in neurobiology. In: Current topics in Developmental Biology, 1982, Vol. 17, Academic Press, New York, Pp, 207 – 240.
12. Popova, E. N (1989). Ultra structure of neurons of the sensory motor cortex in pregnancy of rats receiving alcohol during pregnancy. Neurosci. Behave. Physiol. 19: 433 – 9.
13. Inomata, K; Nasu, F; Tanaka, H (1987). Decreased density of synaptic formation in the frontal cortex of neonatal rats exposed to ethanol in utero. Int. J. Dev. Neuroscience 5: 455 – 60.
14. Jones, KI; Smith, DW (1973). Recognition of the fetal alcohol syndrome in early infancy. Lancet 7836; 999 – 1001.

Author Information

Mokutima A. Eluwa, M.Sc.

Department of Anatomy, Faculty of Basic Medical Sciences, University of Calabar

C.N. Njoku, B.Sc.

Department of Anatomy, Faculty of Basic Medical Sciences, University of Calabar

Theresa B. Ekanem, Ph.D.

Department of Anatomy, Faculty of Basic Medical Sciences, University of Calabar

Amabe O. Akpantah, Ph.D.

Department of Anatomy, Faculty of Basic Medical Sciences, University of Calabar