

# Theca lutein cyst rupture - an unusual cause of acute abdomen : a case report

P Dasari, K Prabhu, T Chitra

## Citation

P Dasari, K Prabhu, T Chitra. *Theca lutein cyst rupture - an unusual cause of acute abdomen : a case report*. The Internet Journal of Gynecology and Obstetrics. 2009 Volume 13 Number 1.

## Abstract

A 20 year old illiterate woman who had a spontaneous first trimester abortion followed by instrumental evacuation, presented 4 days later with sudden onset of pain and distension of abdomen along with difficulty in breathing. On examination, she was tachypnoeic, icteric with tachycardia. Abdominal examination revealed guarding and rigidity along with free fluid and vague mass in lower abdomen. Gynaecological examination showed purulent discharge through os with boggy in all fornices. USG revealed echogenic fluid with bilateral large ovarian masses containing multiple small cysts. Laparotomy was performed with a provisional diagnosis of ruptured theca lutein cysts after 24 hrs of administration of broad spectrum antibiotics. There were bilateral theca lutein cysts of more than 10X15 cm, the left of which has ruptured and the right on the verge of rupture. Bilateral partial cystectomy was performed and histopathological examination confirmed theca lutein cysts with inflammatory infiltrate.

## INTRODUCTION

The causes of distension of abdomen in the post-abortal period include peritonitis secondary to sepsis, perforation of uterus, intestinal obstruction, paralytic ileus, torsion of a ovarian cyst etc.,. When there is no history suggestive of hydatidiform mole it is difficult to keep in mind the differential diagnosis of theca lutein cyst rupture / torsion. Large theca lutein cysts are uncommon during normal pregnancy and approximately 30 cases are reported in literature so far. It is important to recognise this entity so as to avoid un-necessary radical operations<sup>1</sup>.

Sepsis is one of the complications of instrumentation of uterine cavity especially during pregnancy and trophoblastic disease. Though rupture is one of the complications of large theca lutein cysts, we could find only one case in literature. A case of rupture of theca lutein cyst who presented as post-abortal sepsis is reported here due to its rarity.

## CASE

A 20 year old illiterate woman presented to our Emergency department on 11-11-08 with complaints of sudden distension and abdominal pain and difficulty in breathing of one day duration. She was married for 10 months and her periods are regular. She was diagnosed to have 3 months pregnancy and suffered spontaneous abortion for which she attended a nearby local hospital. She was told to have had incomplete abortion and instrumental evacuation was

performed for the same. She suffered from fever with chills from the next day and had diarrhoea and vomiting for 3 days for which she had over the counter medicines. All these symptoms subsided in 4 days. There was no significant history in the first trimester except that she suffered from hyperemesis gravidarum for which she was treated on out-patient basis with oral medications.

On examination, she was anxious, tachypnoeic, afebrile, icteric with a regular pulse rate of 120/min and BP of 100/60mmHg. There was bilateral pitting pedal edema and no lymphadenopathy. Her respiratory rate was 60/min and there were crepitations in the infra-axillary area on the right side. The air entry was decreased in infraclavicular, infra-axillary and infrascapular regions on the same side. CVS was normal except for tachycardia.

Abdomen was grossly distended uniformly. Tenderness, guarding and rigidity were present in all quadrants. No mass could be made out clearly because of tenderness. Shifting dullness was positive and bowel sounds were well heard. Per speculum examination, revealed purulent discharge through os. On per vaginal examination, cervix was soft and os was closed. Uterus size could not be appreciated and there was boggy and tenderness in all the fornices. A provisional clinical diagnosis of septic abortion Grade III was made and she was investigated.

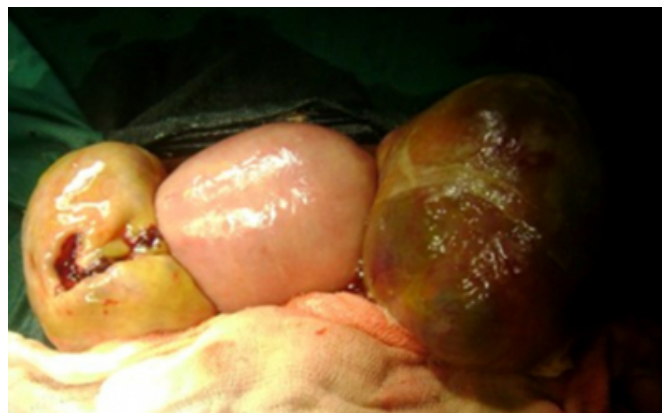
Transabdominal ultrasound showed large amount of free fluid in abdomen and pelvis. Liver was normal but gall bladder was enlarged and appeared oedematous. There was right sided minimal pleural effusion. There were ill – defined membranous structures seen in the hepatic and renal fossae. Uterus appeared bulky with empty cavity. There was a well defined hyperechoic mass of 11.4 X 7 cm with multiple small thick walled cysts to the right of uterus. Similar mass of 11 X 5.8 cm, containing multiple cysts and septations was seen in POD. A clinical diagnosis of rupture theca lutein cysts was made at this juncture and she was questioned about passage of any vesicles suggestive of hydatidiform mole. However, she was not certain about the nature of products she expelled at home and she was not given any discharge record in the hospital where she underwent evacuation of the uterus.

Her haemogram showed Hb of 6 gm% with a TLC count of 45,000/mm<sup>3</sup> and DLC showed 63 % neutrophils, 4% lymphocytes 4% metamyelocytes and 24% stab forms. Platelet count was 2,79,000/ mm<sup>3</sup> and FDP was negative. Her blood urea was 63 mg% and Serum creatinine was 1.2 mg %. LFT showed bilirubin of 10 mg % direct being 7mg%, ALT 33U/L, Alkaline Phosphatase 170 U/L, GGT 79 U/L Prothrombin time INR was 2.34. X- ray chest P/A revealed right lower lobe pneumonia with minimal pleural effusion.

Emergency laparotomy was carried out under GA after 24 hrs of administration of broad spectrum antibiotics. There was 2 litres of straw coloured fluid in abdomen and pelvis with yellowish, necrotic membranous structures within it. Uterus was soft congested and enlarged to 14 weeks size and there was no evidence of perforation. Both tubes appeared congested. Both ovaries were replaced by yellow coloured multiloculated masses containing small thick walled cysts of >10 X 15 cm (Fig 1A & IB). No normal ovarian tissue could be seen. There were two areas of breach in the capsule on the left side from which the serous fluid was oozing. Some of the cysts were haemorrhagic.

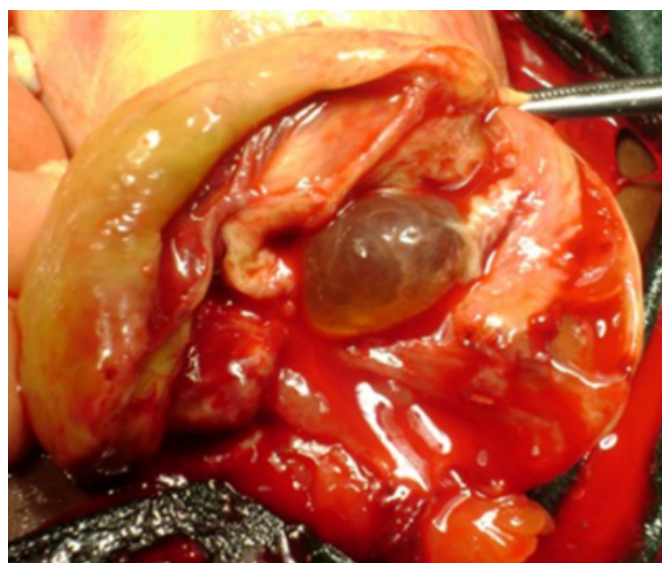**Figure 1**

Fig. 1 A. Shows enlarged uterus in the centre and bilateral theca lutein cysts. The cyst on the left shows a breach in the capsule and the right cyst with thin haemorrhagic area suggestive of impending rupture



**Figure 2**

Fig.1 B. Shows cortex of theca lutein cyst along with a small thick walled cyst in the centre of the cortex (One among the multiple cysts contained in the ovary)



All other viscera were normal except the gall bladder which was enlarged. A final diagnosis of Theca lutein cyst rupture was made and bilateral partial cystectomy was done as the other cyst also appeared to be on the verge of rupture. Abdomen was closed after saline wash and after inserting a drain in to pelvis. She was kept in ICU under controlled ventilation as she was unable to maintain saturation at room air. She had hypotension in the immediate post-operative period and was maintained haemodynamically with Nor-adrenaline infusion. She was extubated after 24 hrs. She received 8 units of FFP, 4 pre-operatively and 4 post-operatively and one unit of packed cells during the intra-

operative period. Injection Ceftriaxone, metronidazole and amikacin were the antibiotics she received perioperatively which were continued after the culture reports. Sputum c/s showed *Klebsiella pneumonia* which was sensitive to amikacin. Urine culture, blood culture, peritoneal fluid cultures were negative. Cervical swab culture revealed *Escherichia coli* which was sensitive to amikacin. But she developed high spikes of fever from the second post-operative day and a repeat X-ray chest revealed persistent pleural effusion with a pneumonic patch. Diagnostic pleural tap revealed pus which on culture did not grow any organism. AFB staining and culture subsequently were negative. Her general condition gradually improved and LFT became normal on 7<sup>th</sup> post-operative day. Drain was removed after one week and sutures on eleventh post-operative day after wound healing. CT thorax performed after 2 weeks because of persistent temperature showed empyema and consolidation involving region of right lower lobe with surrounding pleural membrane thickening.

Serum  $\beta$  HCG done 3 weeks after surgery was 2,789.6 mIU/ml. Repeat  $\beta$  HCG after 2 weeks showed a decrease of more than 50% of the above value i.e., it was 1,286.6 mIU/ml. The histopathological examination was reported as theca lutein cysts with inflammatory exudate and neutrophilic infiltration.

The patient ultimately became afebrile after 3 weeks after admission and was discharged after a month after performing a USG which showed uterus to be normal size with endometrial thickness of 7.8 mm and right ovary measuring 4.2 X 2.2 cm and left ovary measuring 4.6 X 2.5cm.

On follow-up at 3 months she was normal with  $\beta$  HCG of 6.8 mIU/ml. She was advised to come for further follow up and use condom as contraception to avoid pregnancy at least for one year.

## **DISCUSSION**

When theca lutein cysts are diagnosed, trophoblastic disease must be ruled out as large theca lutein cysts are uncommon with normal pregnancy. Complications are rare and include rupture and torsion<sup>2</sup>. Theca lutein cysts occur in 25-30% of patients with Hydatidiform mole and are bilateral and largest when HCG production is greatest (12-24 weeks of gestation) and may persist 2-3 months after evacuation of mole. They may twist and haemorrhage causing areas of solid echogenicity seen within the cysts<sup>3</sup>. The present case gave history of 3 months of amenorrhea and had cysts of

large size. When the cysts are large they can cause pressure symptoms and abdominal pain and result in torsion, haemorrhage and rupture and hence they can be managed by percutaneous USG guided aspiration to achieve symptomatic relief<sup>4</sup>.

Bilateral theca lutein cysts as large as 10 cm at an early period of gestation of non-molar pregnancy was reported by O'Loughlin J and Brookes. The patient presented at 8 weeks of pregnancy with bilateral theca lutein cysts with ascites and pleural effusion which rapidly increased necessitating laparotomy and drainage and resection of cysts to decrease the respiratory embarrassment. As in our case, they also could not find any normal ovarian tissue in the masses and they dissected cortex off the cysts (as was shown in our fig.IB) and reconstructed the ovaries<sup>5</sup>.

The differential diagnosis of this condition includes pregnancy luteoma, granulosa cell tumour and ovarian cystadenoma etc., and it is sufficient to observe the patient in the absence of complications for the regression of the cysts which usually occurs within a few weeks of termination of pregnancy<sup>1</sup>. In a large series of patients with hydatidiform mole the association of bilateral theca lutein cysts showed increased incidence of postmolar trophoblastic disease, severe complications of hydatidiform mole and their regression did not depend entirely on the changes of  $\beta$  HCG level<sup>6</sup>. In the present case, the cysts though large regressed gradually and attained almost normal size in 3 months. We could find a case of rupture of theca lutein cyst during first trimester which was diagnosed by Ultrasonic Doppler in the year 1967<sup>7</sup> that resulted in successful pregnancy outcome.

## **CONCLUSION**

This present case illustrates post-abortion sepsis causing inflammation of theca lutein cysts resulting in rupture and septicaemia in the form of pneumonia and effusion even though blood culture was negative. Performing an ultrasound prior to dilatation and evacuation and sending the material for histopathological examination are important for the diagnosis. Prophylactic/therapeutic antibiotics are useful to prevent the complications of sepsis.

## **References**

1. Bakri YN, Bakhawain M, Hugosson C. Massive theca-lutein cysts, virilisation and hypothyroidism associated with normal pregnancy. *Acta Obstet Scand* 1994; 73:153-155.
2. Pernoll ML, Benson RC. The ovary and Oviducts. In Benson and Pernoll's *Hand book of Obstetrics and Gynaecology*. 10th ed Pub by McGraw Hill

Professional.2001:651-680.

3. DeLange M, Tann-Sinn PA, Grube GL. Gestational Trophoblastic disease. In Diagnostic Medical Sonography : Obstetrics and Gynecology ed by Berman MC, Cohen HL. Pub by Lippincot Williams and Wilkins,1997;507-515.

4. Sheafor DH, Freed KS, Nelson RC. Technique and role of Ultrasound guided aspiration of theca lutein cysts. Emergency Radiology.1999; 6 (2):110-112.

5. O'Loughlin J, Brookes CM. Massive multiple Theca Lutein Cysts complicating Non-molar pregnancy. Aust NZ J Obstet Gynaecol. 1987; 27: 166-168.

6. Montz FJ. The natural history of theca lutein cysts. Obstet Gynecol. 1988; 72 (2): 247-51.

7. Kesler KF, Callagan DA. Rupture of theca lutein cyst during first trimester. Ultrasonic Doppler diagnosis and successful outcome. Obstet Gynecol. 1967; 29 (6): 834-837.

**Author Information**

**Papa Dasari, MD.,DGO.**

Prof, Dept of OBGY, JIPMER.

**Karthiga Prabhu, MD.**

Senior resident, Dept of OBGY. JIPMER.

**T. Chitra, DGO, Dip NB**

Senior resident, JIPMER