

# Bilateral Quadriceps Tendon Rupture. Not Always Traumatic?: A Case Report

S Ganesan, C Jeer

## Citation

S Ganesan, C Jeer. *Bilateral Quadriceps Tendon Rupture. Not Always Traumatic?: A Case Report*. The Internet Journal of Orthopedic Surgery. 2005 Volume 3 Number 1.

## Abstract

Simultaneous bilateral quadriceps tendon rupture is an uncommon injury, barely reported in the literature. Reportedly up to 50% of spontaneous quadriceps ruptures are misdiagnosed at first, resulting in poor outcome. We report a case of spontaneous bilateral quadriceps rupture and review the literature and briefly discuss about the various associations and the management strategy.

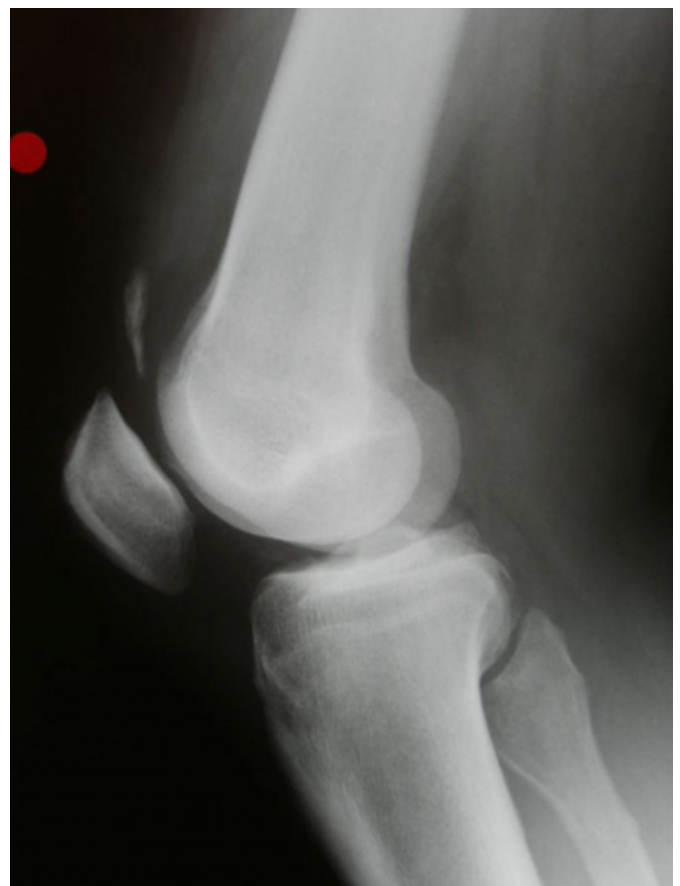## INTRODUCTION

Unilateral quadriceps tendon rupture is a common injury and has been well reported <sup>15</sup>. However bilateral ruptures of the quadriceps tendon occur infrequently and usually occurs in patients older than 40 years, and is either due to fall from the stairs or spontaneously while walking <sup>17</sup>. Spontaneous bilateral ruptures are highly correlated with systemic diseases <sup>11</sup>, but also have been reported in healthy individuals without predisposing factors.

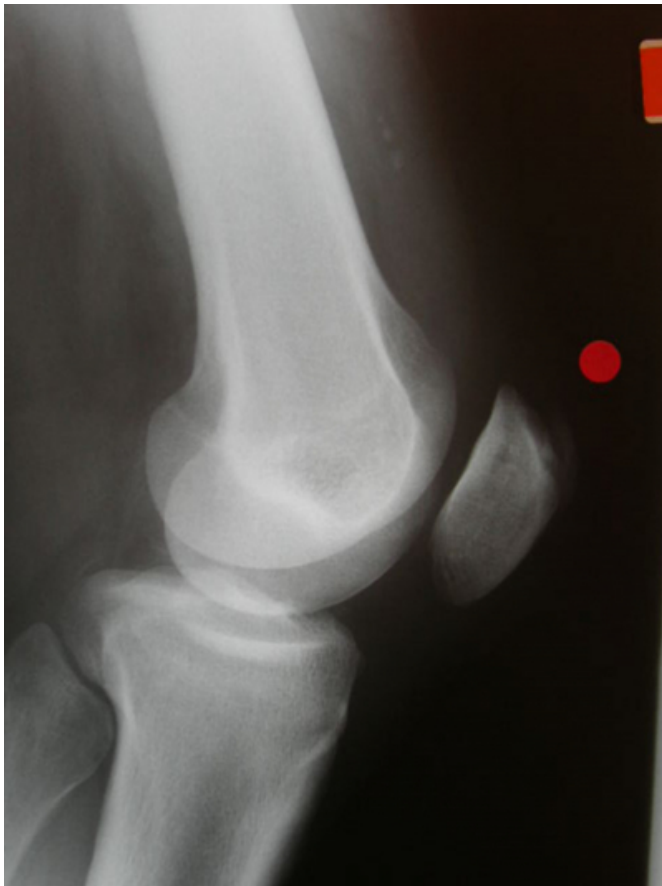## CASE REPORT

65 years old man presented with painful knee and inability to weight bear on both sides after he stumbled down the stairs. He was morbidly obese (BMI-40) with no significant past medical history. Examination revealed swelling and ecchymoses around both the knees, with palpable gap in the suprapatellar region and inability to straight leg rise on both the sides. X - ray revealed loss of continuity of soft tissue shadow of the suprapatellar tendon and flake of calcification within the substance of the quadriceps tendon. (Figure 1&2).

Figure 1

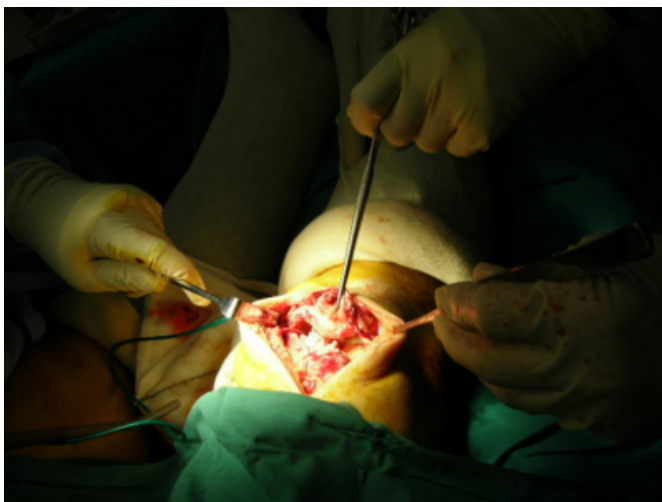


**Figure 2**



A clinical diagnosis of bilateral quadriceps tendon rupture was made and the patient was taken for surgery. Both the tendons were found to be disrupted at the tendo osseous junction (Figure 3) and were repaired with PDS sutures with drill holes placed in the patella. And the limbs were immobilized in cylinder cast for six weeks.

**Figure 3**



## DISCUSSION

Simultaneous bilateral quadriceps tendon rupture is an uncommon injury that is frequently misdiagnosed. There have been reports of cases being initially treated as ministroke<sup>16</sup>. The triad<sup>12</sup> of history of fall, inability to actively extend the knee and palpable supra patellar gap is highly suggestive of quadriceps tendon rupture. The reviewed literature recommends early repair and therefore early diagnosis is crucial.

Quadriceps tendon rupture usually occurs with rapid contraction of the quadriceps muscle with the foot fixed in the ground and knee partially flexed. This usually occurs with fall down the stairs or spontaneously while walking.

McMaster<sup>11</sup> showed that normal tendons in rabbit do not rupture under stress. Harkness demonstrated that approximately 30kg/mm<sup>2</sup> of longitudinal stress may be applied to normal quadriceps tendon prior to failure. But most of the ruptures occur after relatively minor trauma. Therefore tendon rupture necessarily has to occur through the pathologic area of the tendon.

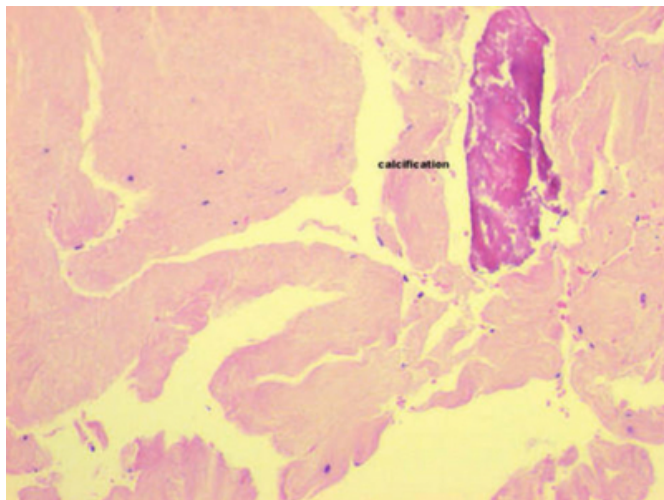
Many conditions have been reported to contribute to degeneration of the quadriceps tendon. Risk factors of the quadriceps rupture include hyperparathyroidism<sup>7,13,14</sup>, chronic renal failure<sup>4,6,9,18,19</sup>, gout<sup>19</sup>, obesity, leukaemia, rheumatoid arthritis, Diabetes mellitus<sup>1</sup>, systemic lupus erythematus, infection, metabolic diseases, steroid abuse<sup>3,28</sup>, tumours, immobilization.

The underlying patho- physiology that leads to rupture varies with the disease process. Most of the cases reported are associated with chronic renal failure. The patho- physiology behind this is poorly understood. Various theories have been put forward. It is thought that chronic academia leads to degeneration of tendon<sup>4</sup>. It is also believed that uraemia affects the structure of the protein polysaccharide complex<sup>2</sup>. And it may be also due to secondary hyperparathyroidism. It is also associated with patients on long-term dialysis probably due to amyloidosis.

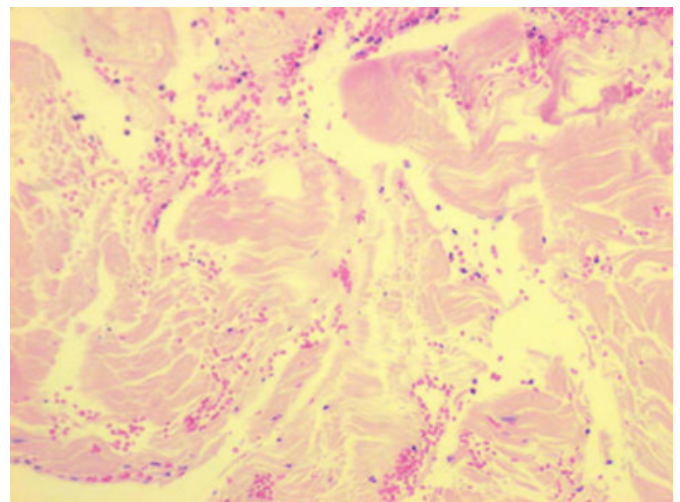
Diabetes mellitus can cause arteriosclerotic changes in tendon vessel, fibrinoid necrosis of tendon is seen in chronic synovitis. Hyperparathyroidism cause dystrophic calcification and subperiosteal new bone formation at the tendon insertion. Obesity causes fatty degeneration of tendons. Steroids alter the structure of collagen. So patient with this injury should be evaluated for underlying medical condition especially renal or endocrine cause.

Kannus and Joza<sup>5</sup> examined histological changes in 891 ruptured tendons. About 97% of the pathologic changes were degenerative. The degenerative changes included hypoxic degenerative tendinopathy, mucoid degeneration, tendolipomatosis and calcifying tendinopathy. In the quadriceps tendon, tendolipomatosis was the most common cause of degeneration. No signs of inflammatory cells were noticed in the specimens. In 62% of the ruptured tendons pathologic changes of the tendon blood supply were seen including vessel narrowing and thrombosis. These findings led the investigators to suggest that nutrition and decreased blood flow, resulting in local hypoxia and impaired metabolic activity are the key factors in tendon degeneration. Peterson and colleague has described about the blood supply to quadriceps tendon. The superficial layers are well vascularised. However in the deep layer there is an oval 30×15 mm avascular area which likely plays a significant role in tendon degeneration. The histological change in our patient has been reported as areas of degeneration and patchy calcification with absence of inflammatory cells and nothing suggestive of Malignancy (Figures 4 ,5)

**Figure 4**



**Figure 5**



### CONCLUSION

In patients who have had a fall or who have spontaneous knee pain along with inability to actively extend the knee, quadriceps rupture should be suspected as earlier surgical intervention provides the best result and the patient also should be evaluated for the underlying medical condition as the rupture may be the first sign of the underlying diseases

### CORRESPONDENCE TO

Senthil Kumar Ganesan, 509, Rusell court, Belfast, BT9 6JX.  
drskmsortho@rediffmail.com

### References

1. Bhole R, Jhonson J: Bilateral simultaneous rupture of the quadriceps tendons in a diabetic patient. *South Med J* 1985; 78:486
2. Bhole R, Flynn J, Marbury T: quadriceps tendon ruptures in uraemia. *Clin orthop* 1985; 195:200-206
3. David HG, Green JT, Grant AJ, et al: Simultaneous bilateral quadriceps rupture: a complication of anabolic steroid abuse. *Bone Joint Surgery Br* 1995; 77:159-160
4. De Franco P, Varghese J, Brown W, et al: Secondary hyperparathyroidism and not beta 2-microglobulin amyloid, as a cause of spontaneous tendon rupture in patients on chronic dialysis. *Am J kidney Dis* 1994; 24:951-955
5. Kannus P, Jozsa L: Histopathological changes preceding spontaneous rupture of a tendon. a controlled study of 891 patients. *J Bone Joint surg Am* 1991 Dec; 73(10):1507-25
6. Lauerman WC, Smith BG, Kenmore PI: Spontaneous bilateral rupture of the extensor mechanism of the knee in two patients on chronic ambulatory peritoneal dialysis. *Orthopaedics* 1987; 10:589-591
7. Lavalley C, Aparicio LA, Moreno J, et al: Bilateral avulsion of quadriceps tendon in primary hyperparathyroidism. *J Rheumatol* 1985; 12:596-598
8. Liow RY, Tavares S: bilateral spontaneous rupture of the quadriceps tendon associated with anabolic steroids. *Br J Sports Med* 1995 Jun; 29(2):77-9
9. Lombardi L, Cleri D, Epstein E: Bilateral spontaneous quadriceps rupture in a patient with renal failure. *Orthopaedics* 1995; 18:187-191

10. Lotem M ,Berheim J, Conforty B: Spontaneous rupture of tendons, a complication of hemodialysed patients treated for renal failure.Nephron 1978;21:201-208
11. Mc Master P: Tendon and muscle ruptures. Clinical and experimental studies on the causes and location of subcutaneous ruptures. J bone and joint Surg 1933;15:705-722
12. Murugeshkumar k, Shah,MD,MPH,Boston,Mass: Simultaneous bilateral rupture of Quadriceps tendons: Analysis of risk factors and associations Southern Medical Journal. August 2002 Vol 95,No 8 860-866
13. Preston E :Avulsion of both quadriceps tendon in hyperparathyroidism.JAMA1972;221:406-407
14. Preston F,Adicoff A: Hyperparathyroidism with avulsion of three major tendons:report of a case. N Engl journal Med 1962; 266:968-970
15. Rougraff BT,Reeck CC,Essenmacher J: Complete quadriceps tendon ruptures. Orthopaedics 1996;19:509-514
16. Sagiv P,Gepstein R, Amdur B,et al: Bilateral spontaneous rupture of the quadriceps tendon misdiagnosed as a "neurological condition" .J Am geriatric soc 1989;37:750-752
17. stephens B.Anderson G Jr: Simultaneous bilateral quadriceps tendon rupture: a case
18. Stern R, Harwin S: Spontaneous and simultaneous rupture of both quadriceps report and sublect review.J Emer Med 1987;5:481-485 tendons. Clin Orthop1980; 147:188-189
19. Tedd RJ,Norton MR, Thomas WG: Bilateral simultaneous traumatic quadriceps tendon ruptures associated with pseudo gout, Injury 2000;31:467-469

**Author Information**

**Senthil Kumar Ganesan, M.S (Orthopaedic surgery)**

Department of Orthopaedics, Queen Elizabeth the Queen mother hospital

**Chan Jeer, FRCS Orthopaedic surgery**

Department of Orthopaedics, Queen Elizabeth the Queen mother hospital