

Renal Cell Carcinoma Metastasis In Urinary Bladder

H Krishnamoorthy, V Pushpangathan, G Joseph, S Abraham

Citation

H Krishnamoorthy, V Pushpangathan, G Joseph, S Abraham. *Renal Cell Carcinoma Metastasis In Urinary Bladder*. The Internet Journal of Urology. 2002 Volume 1 Number 2.

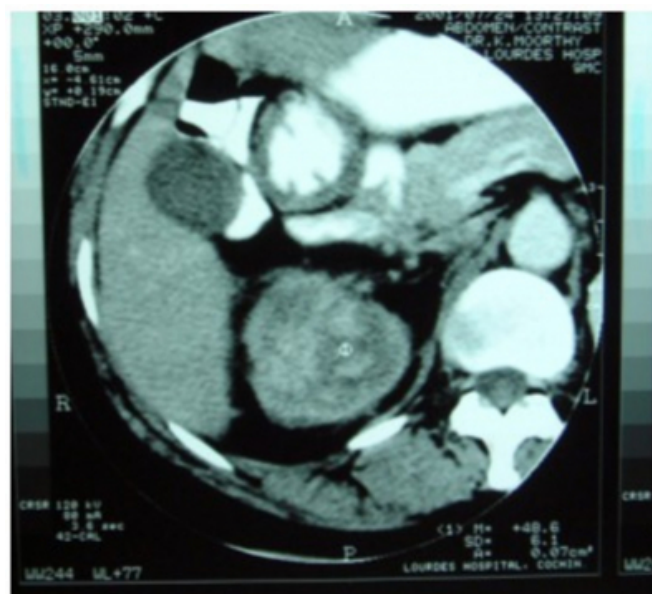
Abstract

Renal cell carcinoma occurring in the urinary bladder is an unusual presentation. We present the report of a case of clear cell variety of renal cell carcinoma presenting as metastasis in the urinary bladder mucosa, six months after radical nephrectomy

CASE REPORT

A 53-year-old lady presented with total painless hematuria and a mass in the region of right kidney. Urine cytology was negative for malignant cells. Ultrasound scan of abdomen showed a mixed echoic mass in the mid-portion of right kidney with involvement of renal pelvis. CT scan of abdomen showed contrast enhancing solid lesion of right kidney (Fig. No.1) with extension to the renal pelvis and upper ureter. There was no evidence of distant metastases. Due to the ureteral extension of the tumour, radical nephroureterectomy with excision of cuff of bladder was done. The histopathology report was clear cell variety of renal cell carcinoma, stage pT3, N0, M0. At 3 months of follow up, Ultrasound and CT scan of abdomen did not show any evidence of local recurrence or distant metastasis. However, there was total painless hematuria at 6 months after surgery. Urine cytology was negative for malignant cells. CT scan abdomen revealed no local recurrence. But there was a solid mass of about 3 cm in the right lateral wall of bladder (Fig. No.2). Cystoscopy showed solid tumour arising from the lateral wall of urinary bladder away from the previous scar. Transurethral resection of tumour was done. The histopathology report was clear cell variety of renal cell carcinoma involving the urinary bladder mucosa. There was no deep muscle infiltration. Post operatively she, was given alpha interferon + 5-Fluorouracil as adjuvant therapy for three months. She has no recurrence after 6 months of further follow up.

Figure 1



Author Information

H. Krishnamoorthy, MS, DNB (Surg), MCH, DNB (Uro), MNAMS
Consultant Urologist, Lourdes Hospital

V. S. Pushpangathan, MS, MCH, DNB (Uro)
Associate Consultant Urologist, Lourdes Hospital

George Joseph, MD
Consultant Radiologist, Lourdes Hospital

Susan Abraham, MD
Consultant Pathologist, Lourdes Hospital