

Restoring Normal Occlusion And Function In A Severely Attrited And Worn Out Dentition - A Case Report

S Garg, S Kumar, N Jindal, S Gupta

Citation

S Garg, S Kumar, N Jindal, S Gupta. *Restoring Normal Occlusion And Function In A Severely Attrited And Worn Out Dentition - A Case Report*. The Internet Journal of Dental Science. 2009 Volume 9 Number 2.

Abstract

Full mouth rehabilitation cases are one of the most difficult cases to manage. They involve not only the replacement of the lost tooth structure but also restoring the lost vertical dimension. Patients generally present with isolated problems in individual tooth, or in isolated teeth in different locations in the oral cavity. Very rarely, patients will present with total wear and tear of all the teeth. This article describes the management of a case with severely attrited and worn out dentition.

INTRODUCTION

Attrition is the loss of tooth structure by mechanical forces from opposing teeth. It initially affects the enamel and, if left unchecked, may proceed to the underlying dentine. Once past the enamel, attrition quickly destroys the softer dentine. Functional habits such as chewing and swallowing, usually put very little force on opposing teeth. Para functional habits, such as clenching and clicking the teeth together nervously, place greater amount of forces on opposing teeth and begin to wear the teeth. As expected, wear usually begins on the incisal or occlusal surfaces. The restorative implications of tooth wear are often complicated by the age of the patient, para functional habits, compromise of conventional fixed restorations and the lack of inter-occlusal space. Dentists are blessed with the ability to change someone's self esteem, confidence and possibly the course of life¹. Patient with tooth wear may require restorative procedures to achieve appropriate function, esthetics and comfort. Occlusal rehabilitation requires a correlation of biological factors, mechanical principles and esthetic requirements with treatment procedures. A combination of new generation materials along with improved clinical procedures work in tandem to produce an esthetic, long lasting and functional outcome, satisfying both the clinician as well as the patient.

CASE REPORT

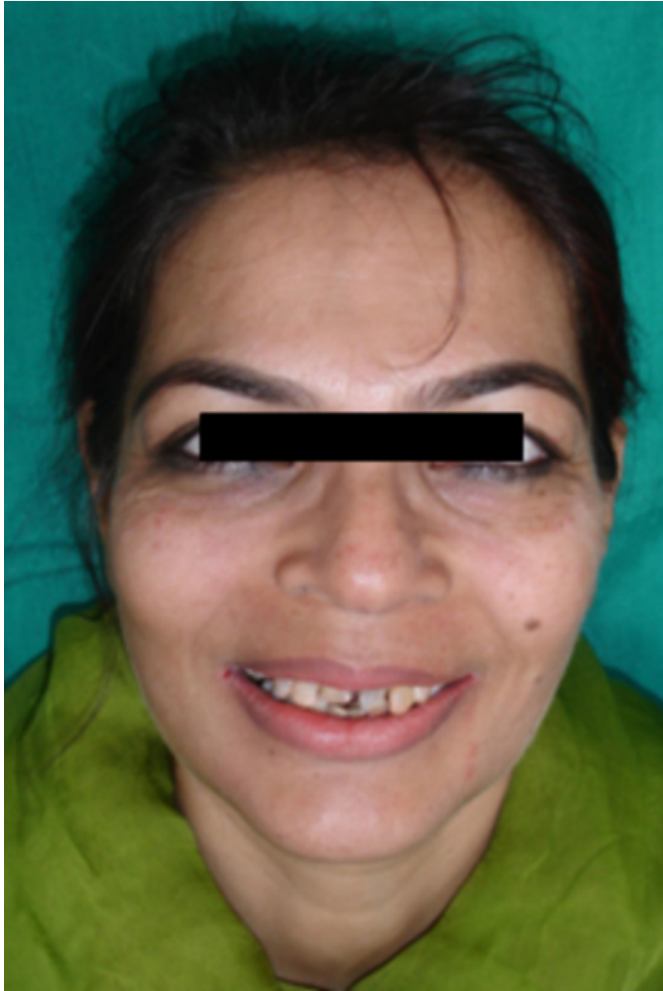A 50 year old female patient reported to Department of Prosthodontics, with the chief complaint of unpleasant smile, generalized sensitivity and difficulty in chewing. The patient denied any symptoms of temporomandibular disorders and

had no medical history.

extra oral examination revealed an unaesthetic smile (Figure I). An intraoral examination revealed severely attrited and discolored dentition with collapsed bite, grossly decayed maxillary left central incisor and missing mandibular right first molar.

Figure 1

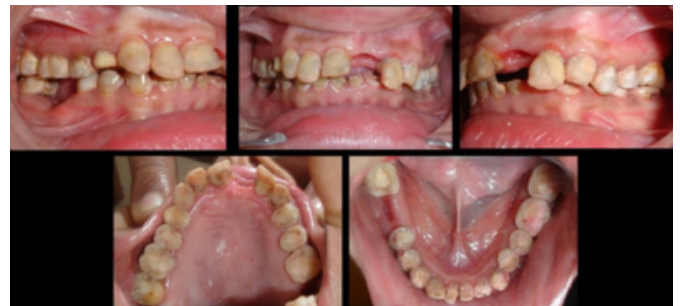Figure I: Pre treatment extra-oral photograph



measured between nose tip and chin tip was 5 - 6 mm, which was greater than the normal value 2 - 4 mm. As there was clinical evaluation of reduced VDO, full mouth rehabilitation with increasing VDO was planned. Diagnostic casts were made, as were face-bow and protrusive records. Casts were mounted in centric relation on a semi-adjustable articulator (Hanau Wide-View Arcon Articulator, Waterpik, Fort Collins, USA) and the articulator was set for condylar and incisal guidance. Because the patient's interocclusal rest space was 2 - 3 mm larger on the premolar area than normal distance, the actual increase were determined 3 mm in the anterior teeth and 1 - 2 mm in the posterior teeth. The splint was designed to offer bilateral contacts of all posterior teeth in centric relation and guides of the anterior teeth in excursive movement. The anterior guidance disoccluded the posterior teeth in all jaw position except centric relation. The adaptation of patient to the increased VDO was evaluated during 1 month trial period (Figure III). The patient was asymptomatic and tolerated the new vertical dimension well.

Figure 2

Figure II: Pre treatment intra-oral photographs after extraction



TREATMENT GOALS

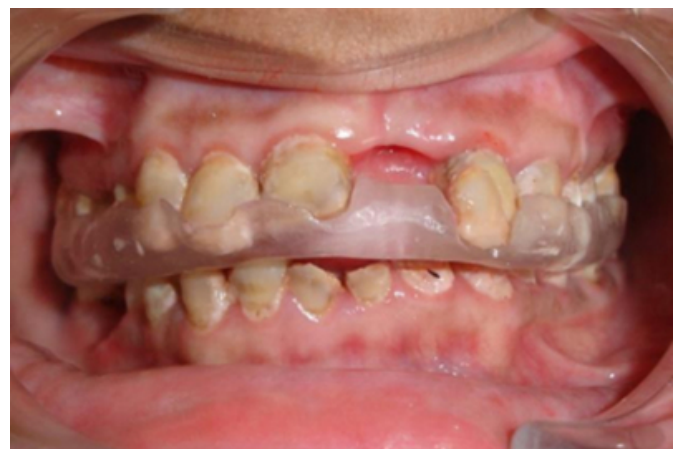- Management of grossly decayed teeth.
- Restoration of the vertical dimension and establishment of centric occlusion.
- Replacement of the missing teeth with fixed prosthesis.
- Full coverage metal ceramic crowns for maxillary and mandibular teeth to restore the entire dentition in esthetic and functional harmony with the stomatognathic system.
- To develop a mutually protected occlusion.

TREATMENT

A thorough oral prophylaxis was carried out. Extraction of grossly decayed maxillary left central incisor was done (Figure II). The patient's interocclusal rest space was

Figure 3

Figure III: Occlusal splint in place

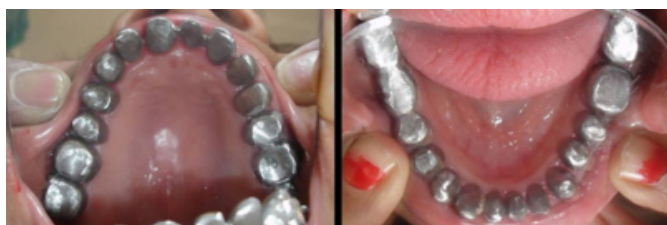


Diagnostic wax-up was done at the established new vertical

to see the final outcomes. The teeth were prepared and provisional crowns were fabricated using a vacuum formed matrix that was produced from the diagnostic wax-up. The provisional fixed restorations were cemented with temporary cement (Provicol (Voco GmbH, Germany), and the patient's adaptation was monitored for further three months. During this period, the patient's condition and functions, such as muscle tenderness, discomfort of TMJ, mastication and speech, were evaluated. Improvement in mastication, speech, and facial esthetics confirmed the patient's tolerance to the new mandibular position with the restored VDO. Final preparation was performed, and definitive impressions were made using polyvinyl-siloxane impression material (ReprosilR; Dentsply Caulk, Dentsply International Inc.). Bite registration was taken using provisional crowns and occlusal registration material by half and half (provisional restorations of one side of the arch was removed and bite was registered on that particular side by maintaining provisional restorations on other side of the arch in occlusion). The final casts were mounted to the semiadjustable articulator with a face bow transfer. Metal frameworks were fabricated (Bellabond plus, Bego, Germany) and were evaluated intraorally to determine the marginal fit (Figure IV).

Figure 4

Figure IV: Metal framework trial



Definite restorations with porcelain fused to metal crowns exhibiting a vital and a natural appearance with proper contour, shade and optimal incisal translucency were designed (DENTSPLY Ceramco, Dentsply International Inc., Germany). Prior to glazing of the ceramic material a trial insertion was performed to enable final occlusal refinement. The patient's natural occlusal scheme (canine-protected occlusion) and anterior guidance were preserved in the definitive restorations to decrease lateral forces on the posterior dentition. The crowns were then completed in the laboratory and cemented with glass ionomer cement (GC, luting & lining cement, GC Corporation, Tokyo, Japan) (Figure V). The patient was highly satisfied with the treatment results (Figure VI). Oral hygiene instructions were reviewed emphasizing the brushing habits and the use of

dental floss.

Figure 5

Figure V: Post treatment intra-oral photographs

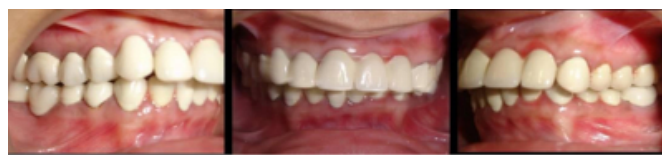
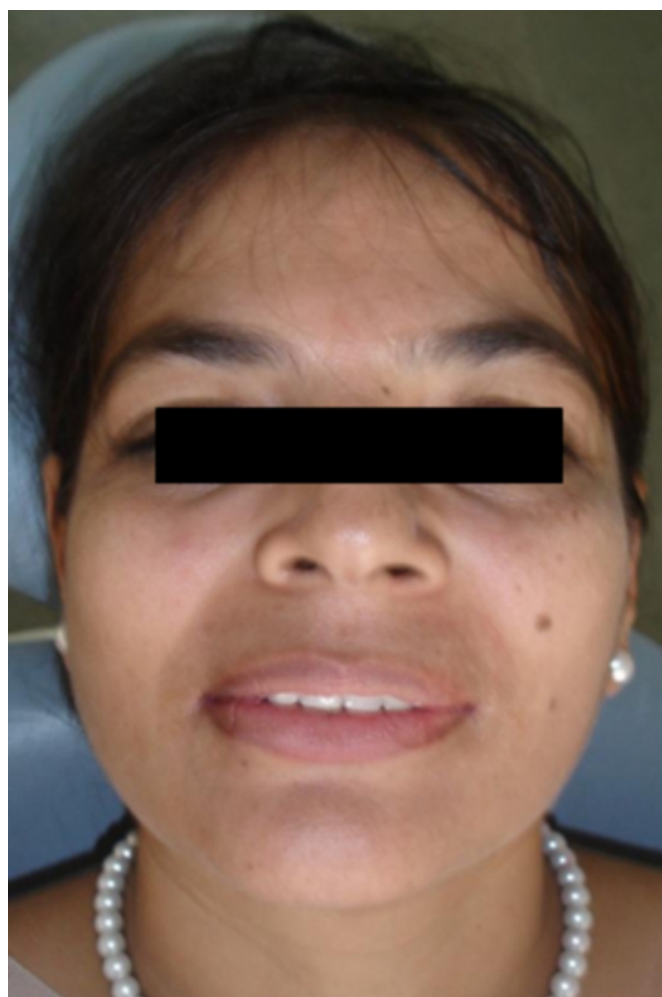
Figure 6

Figure VI: Post treatment extra-oral photograph



DISCUSSION

The etiology of tooth wear is multifactorial. In addition, lack of evidence regarding the long-term outcomes of treatment methods and materials cause difficulty in clinical decision-making. Because of these unclear guidelines, incline towards adhesive dentistry that is more conservative and reversible, is increasing. However several limitations may exist. For instance in the present patient, we could use ceramic laminates to restore esthetics as metal-ceramic crowns require more aggressive removal of tooth structure. But

ceramic laminates fail to raise vertical dimension and restore proper occlusal intercuspation. Also laminates can not withstand high masticatory loads. Therefore, the conventional treatment modality that includes a overlay splint, provisional restoration, careful observation, and metal ceramic crowns was chosen. In literature, the wearing time of overlay splint and provisional crown is various. The trial period of overlay prostheses is between 3 weeks and 5 months, and that of fixed provisional prostheses is 2 - 6 months^{2,3,4}. In this case, the patient was carefully monitored for 1 month to evaluate the adaptation to the removable overlay splints and Also the patient's adaptation to the provisional restoration was monitored for 3 months. The trial period is relatively short, but discomfort, TMJ pain and muscle fatigue were not observed during that period. . Depending on the patient's situation and adaptation ability, the interim period can be modified, and the careful evaluation and monitoring may shorten the overall treatment duration. Canine protected occlusal scheme was adopted as it prevents destructive occlusal forces on posterior teeth⁵.

CONCLUSION

An important aspect of restoring worn out teeth is the protection of remaining tooth structure. Teeth already

weakened by loss of large amount of tooth structure are ill-equipped to withstand occlusal forces⁶. Protection can be best provided by restoring them with the crowns which further restrict their wear and tear^{7,8}. In this patient, enhanced esthetics and improved function was possible because the clinical crowns and root forms were favorable for complete coverage restorations. The post-operative follow up revealed meticulous hygiene maintenance by the patient.

References

1. Binkley CJ, Binkley TK. A practical approach to full mouth rehabilitation. *J Prosthet Dent* 1987; 57:261-5.
2. Jahangiri L, Jang S. Onlay partial denture technique for assessment of adequate occlusal vertical dimension: a clinical report. *J Prosthet Dent*. 2002;87:1-4.
3. Sato S, Hotta TH, Pedrazzi V. Removable occlusal overlay splint in the management of tooth wear: a clinical report. *J Prosthet Dent*. 2000;83:392-395.
4. Brown KE. Reconstruction considerations for severe dental attrition. *J Prosthet Dent*. 1980;44:384-388.
5. D'Amico A. functional occlusion of natural teeth in men. *J Prosthet Dent* 1961; 11: 899-915.
6. Stuart CE. Good occlusion for natural teeth. *J Prosthet Dent* 1964; 14: 716-24.
7. Chase W. Appraisal of full coverage and mouth rehabilitation. *J Prosthet Dent* 1964; 14: 87-90.
8. Claman L, Alfaro MA, Mercado A. An interdisciplinary approach for improved esthetic results in the anterior maxilla. *J Prosthet Dent*. 2003; 89(1):1-5.

Author Information

Sandeep Garg, MDS

Professor, Department of Prosthodontics and Maxillofacial Prosthetics, MM Institute Of Dental Sciences & Research

Sandeep Kumar, MDS

Reader, Department of Prosthodontics and Maxillofacial Prosthetics, Surendera Dental College & Research Institute

Neetu Jindal, MDS

Reader, Department of Conservative Dentistry & Endodontics, Surendera Dental College & Research Institute

Seema Gupta, MDS

Reader, Department of Orthodontics, Surendera Dental College & Research Institute