Evaluation Of Osteoarthritis Of The Knee With Magnetic Resonance Imaging And Correlating It With Radiological Findings In The Indian Population.

V JOSHI, R Singh, N Kohli, U Parashari, A Kumar, V Singh

Citation

V JOSHI, R Singh, N Kohli, U Parashari, A Kumar, V Singh. *Evaluation Of Osteoarthritis Of The Knee With Magnetic Resonance Imaging And Correlating It With Radiological Findings In The Indian Population.*. The Internet Journal of Orthopedic Surgery. 2008 Volume 14 Number 1.

Abstract

AIMS:
To evaluate the role of Magnetic Resonance Imaging in diagnosing osteoarthritis of knee joint and to correlate MR imaging findings of osteoarthritis with that of radio graphically diagnosed osteoarthritis in Indian population.
METHODS AND MATERIAL: One hundred twenty eight patients formed the study group in a prospective fashion. All patients underwent Antero posterior radiography of affected knee in weight bearing extended positions, KL score was determined and subsequently MRI of the knee was performed. Then Magnetic Resonance Imaging (MRI) findings were correlated by radiographic findings.
STATISTICAL ANALYSIS USED: Data were analyzed using statistical software package, STATA 9.2 and the association was considered to be significant if 'P' value was <0.05.
RESULTS:

The tibiofemoral compartment was more frequently and more severely involved in osteoarthritis of knee joint than the patellofemoral compartment and medial tibiofemoral joint was most commonly involved. Majority of MRI findings in tibiofemoral compartment of knee joint and KL score are well correlated.

INTRODUCTION

Worldwide, osteoarthritis is the most common form of arthritis. Osteoarthritis (OA) is a highly prevalent disease, and the prevalence is expected to increase substantially as a greater proportion of the population exceeds 60 years of age[1,2]. The diagnosis of osteoarthritis is based primarily on the history and physical examination, but radiographic findings, including asymmetric joint space narrowing, subchondral sclerosis, osteophyte formation, subluxation and distribution patterns of osteoarthritic changes, can be helpful when the diagnosis is in question. Historically, the primary modality for imaging evaluation of OA has been radiography, although the limitations of radiographic parameters for OA evaluation are well-documented. Because radiographs are a two-dimensional composite of complex three-dimensional structures, the sensitivity for observation of features such as osteophytes, bone eburnation, and other subchondral bone abnormalities on them is limited. Lastly, radiographically observed abnormalities in OA often correlate imperfectly with clinical symptoms [3-6] .This finding reinforces the evolving concept that OA of the knee is a whole-organ disease and that MR imaging is capable of showing the bone and soft-tissue evidence of OA of the knee[7].

Recent focus on the development of disease-modifying therapeutic agents for OA has emphasized the need for imaging techniques capable of depicting relevant early abnormalities of OA over relatively short times. Simultaneously, there is increasing acknowledgment that OA, particularly in the knee, can be regarded as a whole-organ degenerative process [7], with an emphasis on the contribution of multiple articular and periarticular abnormalities in the clinical expression of the disease. Dr. Peterfy, co-founder and Chief Medical Officer of Synarc, was the first to develop whole-organ MRI scoring (WORMS) for the knee. WORMS combines semi-

quantitative assessments of a total of 11 structural features, including the articular cartilage, subarticular marrow-edema, cysts and bone attrition in 8 different locations in the knee; osteophytes along 16 articular margins; the medial and lateral menisci; the anterior and posterior cruciate ligaments; and the medial and lateral collateral ligaments [8]. MRI is an excellent diagnostic modality in osteoarthritis. The superior soft tissue contrast of MRI provides the ability to diagnose cortical bone, articular cartilage and soft tissues abnormalities in the joints that improves early detection of osteoarthritic changes in knee joint.

The study was performed to grade various stages of osteoarthritis by using Kellgren-Lawrence grading scale , to evaluate the osteoarthritis of knee using magnetic resonance imaging , to correlate MR findings of osteoarthritis with that of radiographically diagnosed osteoarthritis .

SUBJECTS AND METHODS

One hundred twenty eight patients have formed the study group in a prospective fashion. All patients underwent Anteroposterior radiography of affected knee in weight bearing extended positions and subsequently MRI of the knee was performed. For the reporting of abnormalities at MR imaging according to compartment, simple counts (numbers and percentages) were estimated. In the analysis of MR imaging findings for the OA of the knee, the single knee (the most symptomatic knee at inclusion in the study) for each subject was analyzed. For subjects in whom both knees equally fit the categorical criteria, the self-described dominant knee was chosen as the examined knee. Patients with knee pain/stiffness/limitation of movement were included and osteoarthritis of knee was diagnosed by clinicoradiological American Rheumatism Association Criteria, viz;

1. Osteophytosis
2. Knee pain
3. Age >40 yrs
4. Joint stiffness<30 minute
5. Crepitus

For diagnosing osteoarthritis presence of 1,2 and one of 3 ,4or 5 is essential.

Exclusion criteria were claustrophobia , non cooperative patients, patients with obvious inflammation, secondary osteoarthritis e.g. trauma, operated knee joint, inflammatory arthritis eg.rheumatoid arthritis, morning stiffness>1 hr in hand joints ,diseased ipsilateral hip joint ,fibromyalgia ,depression ,local wound/ulcer around knee joint or presence of peripheral neuropathy.

RADIOGRAPHIC FINDINGS AND KL SCORE

Radiological grading of severity of osteoarthritis

Radiographic Assessment was done by Anteroposterior radiographs of the knee, obtained in a weight-bearing extended position by using a standard radiographic technique. Scores to all radiographs were assigned by using the Kellgren-Lawrence scoring system [9] .

Figure 1

TABLE 1: KELLGREN-LAWRENCE GRADING SCALE

Grade 0	Normal
Grade 1	Doubtful narrowing of joint space and possible osteophytic lipping
Grade 2	Definite osteophytes, definite narrowing of joint space
Grade 3	Moderate multiple osteophytes, definite narrowing of joints space, some sclerosis and possible deformity of bone contour
Grade 4	Large osteophytes, marked narrowing of joint space, severe sclerosis and definite deformity of bone contour

TECHNIQUE OF MAGNETIC RESONANCE IMAGING IN KNEE OSTEOARTHRITIS

MR imaging of the knee was performed with a 1.5-T MR imager (Signa; GE Medical Systems), by using a quadrature receiver knee coil for signal reception. Since patients with symptomatic knees were examined by using a fairly long acquisition protocol, patients were immobilized by using hook-and- loop straps. MR Imaging were performed by using T2 FSE sequence in axial plane; PD Fat Sup, T1 SE, T2 fr FSE and SPGR sequence in sagittal plane and STIR FSE,T2 GRE & T1 FSE in coronal plane. For STIR and SPGR matrix of 256 x192 was used. For rest of the sequences matrix of 320x224 was used. FOV (field of view) of 18 mm was used in all sequences. Slices were obtained at 4-5 mm thickness with an interscan gap of 0.5-1 m. In SPGR sequence slice thickness was 2mm, with no spacing. Each knee was assessed globally and according to compartment for 12 MR imaging–defined parameters. The compartments in knee joint were medial and lateral articulating surface of femur(MF and LF respectively), medial and lateral articulating surface of tibia(MT and LT respectively), medial and lateral articulating facets of patella (PMF AND PLF respectively) and trochlea of femur (FT).

Defects of cartilage.—Location, severity, and approximate size of defects of cartilage in three compartments (medial femorotibial, lateral femorotibial, patellofemoral compartments) and seven specific surfaces (medial articular surface of tibia, medial articular surface of femur, lateral articular surface of tibia, and lateral articular surface of femur , trochlea and medial and lateral patellar facets) were assessed. Severity scoring was based on the Noyes arthroscopic system, which was modified for MR imaging [10].Cartilage was assigned grades as follows: grade 0, normal; grade I, internal signal intensity alteration only; grade IIA, defect of cartilage of less than 50%; grade IIB, defect of cartilage of 50%–99%; grade IIIA, 100% defect of cartilage with no bone ulceration; or grade IIIB, 100% defect of cartilage with subjacent bone ulceration.

Subchondral trabecular BME.—BME was defined as noncircumscribed areas of abnormally high signal intensity on IW fast spin-echo images obtained with fat saturation in a subchondral location and verified in at least two imaging planes [11,12]. BME lesions were recorded according to site and severity in the following manner: grade 0, normal; grade 1, largest diameter of less than 10 mm; or grade 2, largest diameter of greater than 10 mm.

Figure 2

FIGURE :1 GRADE II BONE MARROW EDEMA IN MEDIAL TIBIAL AND FEMORAL CONDYLES AND GRADE 1 EDEMA IN LATERAL TIBIAL AND FEMORAL CONDYLES

Marginal osteophytes.—Osteophytes were defined as any abnormal bone growth that arose from the margin of the involved compartment. Tibial spine growths were considered as osteophytes in their respective compartments only if there were definite excrescences, as opposed to mere “pointedness” of the tibial spines. Osteophytes in each compartment were assigned grades as follows: grade 0, no osteophytes; grade 1, osteophytes of less than 5 mm; or grade 2, osteophytes of greater than 5 mm [13].

Figure 3

Figure :2 GRADE II OSTEOPHYTE IN MEDIAL FEMORAL CONDYLE AND GRADE 1 OSTEOPHYTE IN LATERAL FEMORAL AND MEDIAL TIBIAL

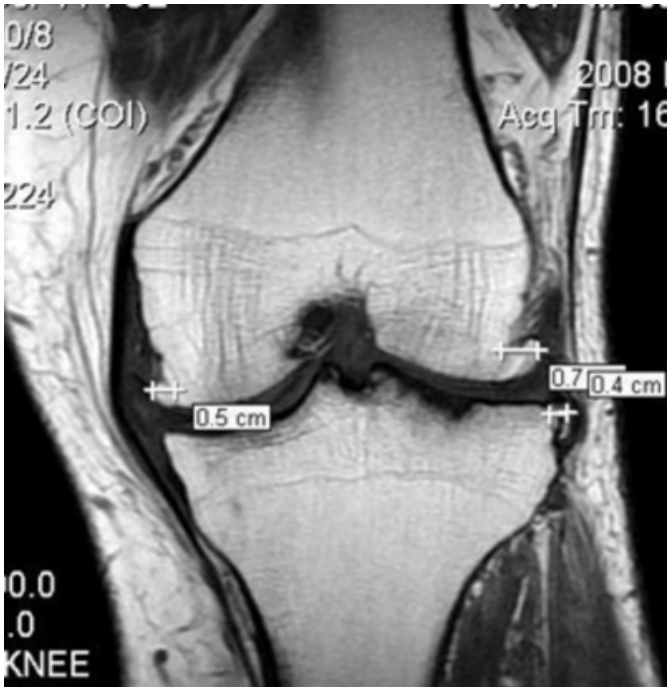

Subchondral cysts.—Subchondral cysts were defined as marginated circular or oval areas of hyperintensity (similar to that of fluid) on IW fast spin-echo images obtained with fat saturation in a subchondral location [14]. Cysts were assigned grades according to compartment as follows: grade 0, normal; grade 1, less than 10 mm in diameter; or grade 2, greater than 10 mm in diameter.

Subchondral sclerosis.—Definite focal thickening of the subchondral bone, consisting of low signal intensity on both IW spin-echo images and IW fast spin-echo images obtained with fat saturation, was classified as sclerosis [15] Sclerosis was assigned grades according to each compartment as follows: grade 0, normal; grade 1, sclerosis with depth extending less than 5 mm; or grade 2, sclerosis with depth extending more than 5 mm.

Joint effusion.—Joint effusion was defined as the presence of greater than expected physiologic amounts of synovial fluid in the lateral or medial patellar recesses that exceeded 10 mm in width [16].Joint effusion was assigned grades as follows: grade 0, normal; grade 1, small effusion; or grade 2, moderate or large effusion.

Baker's cyst/Synovial cysts.—Synovial cysts were fluid-filled collections that arose from the joint, extended between the semimembranosis and semitendinosis tendons and the medial head of the gastrocnemius muscle, or were in a less typical site, if confirmed to be in continuity with the joint [16]. Meniscal cysts, ganglionic cysts, and other nonspecific periarticular cysts were not included in the analysis. Synovial cysts were assigned grades according to a semiquantitative scale as follows: grade 0, normal; grade 1, small; or grade 2, large.

Figure 4

FIGURE: 3 JOINT EFFUSION AND BAKER'S CYST

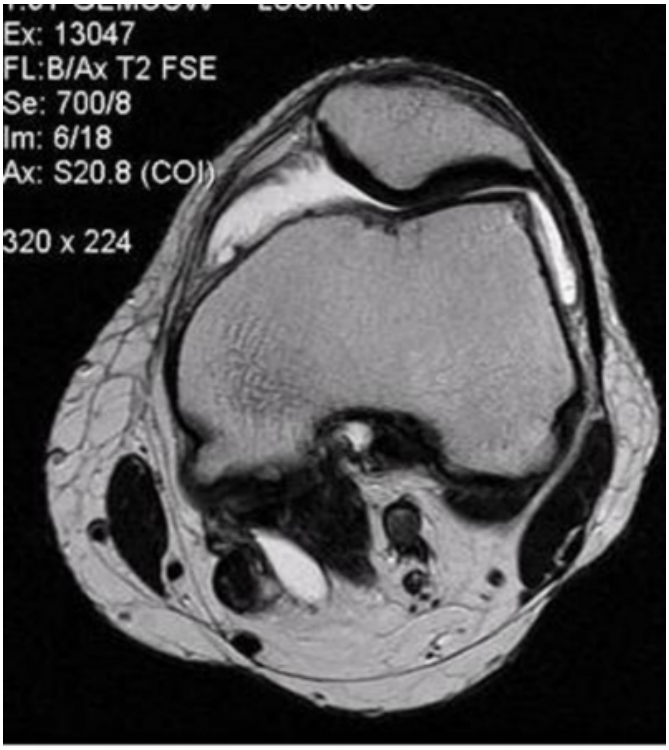

Synovitis.—Synovitis was defined as increased linear striations within the infrapatellar (Hoffa) fat pad and irregular thickening at the margin of the fat pad with the articular cartilage [17,18]. These abnormalities consisted of low signal intensity on IW spin-echo images and intermediate to high signal intensity on IW fast spin-echo images obtained with fat saturation. Synovitis was assigned grades thus: grade 0, normal; grade 1, mild; or grade 2, moderate to marked.

Meniscal abnormalities.—By using accepted MR imaging criteria described in a study of Crues et al [19], intrameniscal abnormalities and frank tears were assigned grades that were recorded as follows: grade 0, normal or globular intrasubstance abnormalities (grade 1 of Crues et al); grade 1, linear intrasubstance meniscal abnormality (grade 2 of Crues et al); grade 2, nondisplaced tear (grade 3 of Crues et

al); or grade 3, displaced, complex, or macerated tears.

Ligamentous abnormalities.—Cruciate ligamentous abnormalities were assigned grades as follows: grade 0, normal; grade 1, increased edema within or surrounding the ligament, with a normal course, and at least some intact fibres present; or grade 2, complete tear, acute or chronic. Collateral ligamentous abnormalities were assigned grades as follows: grade 0, normal ligament; grade 1, substantial periligamentous edema, with the ligament intact; grade 2, partial tear; or grade 3, complete tear.

Osteochondral bodies/loose bodies- Loose bodies can be classified into several categories: Osteocartilaginous, hyaline cartilaginous, fibrous cartilaginous, and other. Osteocartilaginous loose bodies are composed of bone and cartilage and are thus detectable radiographically because of the osseous component. Hyaline cartilaginous loose bodies are radiolucent and are usually caused by trauma, originating from the articular surfaces of the patella or the femoral or tibial condyles. Fibrous cartilaginous loose bodies are also radiolucent, occur less frequently, and result from meniscal fragment.

Subluxation in knee joint.

STATISTICAL METHODS

Sample profile was described in terms of means ± SD and proportion. Chi square(c)^2 statistics was applied to test the association between two categorical variables. Spearman's correlation was reported to estimate the strength of association between KL score and severity of osteoarthritis. . Two sample t-test was applied to test the difference between the mean of two different groups, if data was normally distributed otherwise Mann Whitney test was applied. In case of more than 2 groups, one way Analysis of Variance or Kruskal Walli's test, whichever is applicable, was used. Data were analyzed using statistical software package, STATA 9.2 and the difference was considered to be significant if 'P' value was <0.05.

RESULTS

All the patients presented at an age equal to or more than 40 years. Most of the patients (n=48, 37.50%) were 40-45 years of age. The study population included ninety two females (71.87%) and thirty six males (28.13%) and a higher incidence of osteoarthritis was seen in female population in the age group of 40-45 years Also the peak prevalence of osteoarthritis in our study was at a lower age in females as compared to males.

Our study population was graded by Kellgren-Lawrence scores according to the severity of osteoarthritis as diagnosed on X-ray features. 48 patients (37.50%) of study population were categorized as having a KL score of Grade 2, 60 patients (46.87%) were diagnosed as having a KL score of Grade 3 and 20 patients (15.63%) were diagnosed as having a KL score of Grade 4. The association between various compartment specific MRI findings and KL score have been shown in table .

Figure 5

TABLE 2 INCIDENCE OF VARIOUS COMPARTMENT SPECIFIC MRI FINDINGS AND COMPARISON WITH KL SCORE(STATISTICALLY SIGNIFICANT ASSOCIATION HAS BEEN MARKED BY ASTERIX*)

SITE	TOTAL INCIDENCE	INCIDENCE OF HIGHEST GRADE	ASSOCIATION OF KL SCORE WITH HIGHEST GRADE OF COMPARTMENT SPECIFIC FINDINGS		
			KLSCORE2	KL SCORE 3	KL SCORE 4
MF*	128 (100.00 %)	36(28.12 %)	0(0.00%)	64 (12.50 %)	80(15.62 %)
MT*	116 (90.62 %)	60(46.87 %)	4(3.12%)	36(28.12 %)	20(15.62 %)
LF*	92(68.75 %)	36(28.12 %)	0(0.00%)	24(18.75 %)	12(9.38%)
LT*	88 (71.87 %)	24(18.75 %)	0(0.00%)	12(9.38%)	12(9.38%)
FT*	40 (31.25 %)	4(3.12 %)	0(0.00%)	4(3.12%)	0(0.00%)
PTMF*	104 (81.25 %)	8(6.25 %)	0(0.00%)	8(6.25 %)	0(0.00%)
PTLF*	52 (40.62 %)	12(9.38%)	0(0.00%)	12(9.38%)	0(0.00%)
SUBCHONDRAL CYSTS					
MF	80(62.5 %)	20(15.62 %)	8(6.25 %)	8(6.25 %)	4(3.12%)
MT*	68(53.12 %)	32(25.00 %)	0(0.00%)	20(15.62 %)	12(9.38%)
LF*	32(28.12 %)	8 (6.25 %)	0(0.00%)	4(3.12%)	4(3.12%)
LT*	60(46.87 %)	16(12.50 %)	4(3.12%)	0(0.00%)	12(9.38%)
FT*	36(28.12 %)	8(6.25 %)	0(0.00%)	4(6.25 %)	0(0.00%)
PTMF*	32(25.00%)	4(3.12 %)	0(0.00%)	4(3.12%)	0(0.00%)
PTLF*	60(15.62 %)	8(6.25 %)	0(0.00%)	8(6.25 %)	0(0.00%)
BONE MARROW OEDEMA					
MF*	60(78.12%)	60(46.87 %)	20(15.62 %)	24(18.75 %)	16(12.50 %)
MT*	88(68.75 %)	44(34.37 %)	0(0.00%)	6(18.75 %)	8(15.62 %)
LF*	68(53.12 %)	40(31.25 %)	16(12.50 %)	12(9.38%)	12(9.38%)
LT*	60(46.87 %)	16(12.5 %)	4(3.12%)	0(0.00%)	12(9.38%)
FT*	56(43.75%)	16(12.5 %)	8(6.25 %)	4(3.12%)	4(3.12%)
PTMF*	52(40.62 %)	8(6.25 %)	4(3.12%)	0(0.00%)	4(3.12%)
PTLF*	48(37.5 %)	8(6.25 %)	4(3.12%)	4(3.12%)	0(0.00%)
SUBCHONDRAL SCLEROSIS					
MF	76(59.37%)	12(9.38%)	4(3.12%)	4(3.12%)	4(3.12%)
MT*	96(75.00 %)	20(15.62 %)	8(6.25 %)	8(6.25 %)	4(3.12%)
LF*	4(3.12 %)	0(0.00%)	0(0.00%)	0(0.00%)	0(0.00%)
LT	52(40.62 %)	12(9.38%)	8(6.25 %)	4(3.12%)	0(0.00%)
FT*	8(6.25 %)	4(3.12 %)	0(0.00%)	4(3.12%)	0(0.00%)
PTMF*	16(12.5 %)	4(3.12 %)	0(0.00%)	4(3.12%)	0(0.00%)
PTLF*	28(21.88%)	8(6.25 %)	4(3.12%)	4(3.12%)	0(0.00%)
CARTILAGE DEFECTS					
MF*	124(96.87%)	44(34.38%)	16(6.25 %)	16(12.50 %)	20(15.62 %)
MT*	124(96.87%)	52(40.62 %)	16(12.50 %)	36(18.75 %)	12(9.38%)
LF*	124(96.87%)	24(18.75 %)	8(6.25 %)	8(6.25 %)	8(6.25 %)
LT*	128(100.00%)	24(18.75 %)	0(0.00%)	12(9.38%)	12(9.38%)
FT*	88(71.87 %)	20(15.62 %)	12(9.38%)	4(3.12%)	4(3.12%)
PTMF*	31(96.87%)	20(15.62 %)	0(0.00%)	12(9.38%)	8(6.25 %)
PTLF*	21(65.63%)	4(3.12 %)	0(0.00%)	4(3.12%)	0(0.00%)

There is a high correlation between MR severity of osteophytes ,subchondral cysts, bone marrow edema ,cartilage defects and radiographic findings (P value = 0.000, 0.000.0.000,0.000,0.030,0.001 ,0.000 ; P=0.40, 0.000, 0.000

,0.000,0.014,0.050 ,0.005; P=0.022,0.000,0.000,0.000,0.002,0.006,0.018; P=0.000,0.000,0.000,0.000,0.001,0.000,0.000 respectively for osteophytes, subchondral cysts, bone marrow edema and cartilage defects in medial condyle of femur, medial condyle of tibia ,lateral condyle of femur, lateral condyle of tibia ,femur trochlea, medial and lateral patellar facets respectively). A positive association was also seen between radiographic findings and MRI detected subchondral sclerosis in medial tibial condyle, femur trochlea and medial and lateral articulating facets of patella (P=0.000, 0.046, 0.008 and 0.008 respectively).

The frequency of non compartment specific MR imaging findings has been shown in the

Figure 6

TABLE 3 : INCIDENCES OF NON COMPARTMENT SPECIFIC FINDINGS (STATISTICALLY SIGNIFICANT ASSOCIATION WITH KL SCORE HAS BEEN MARKED BY ASTERIX*)

	GRADE I	GRADE II	GRADE III
MEDIAL MENISCUS INJURY*	40(31.25%)	60(46.88%)	16(12.50)
LATERAL MENISCUS INJURY*	40(31.25%)	58(53.13%)	16(12.50)
MEDIAL COLLATERAL LIGAMENT INJURY*	0 (0.00%)	8 (6.25%)	NA
LATERAL COLLATERAL LIGAMENT INJURY*	4 (3.13%)	8 (6.25%)	NA
ANTERIOR CRUCIATE LIGAMENT INJURY*	28 (21.88%)	4(3.13%)	NA
POSERIOR CRUCIATE LIGAMENT INJURY*	4(31.25%)	4(3.13%)	NA
BAKER CYST *	32(25.00%)	24(18.75%)	NA
SYNOVITIS *	32 (25.00%)	0 (0.00%)	NA

(NA=NOT APPLICABLE)

A significant association with high KL score was found with meniscal and ligamentous injuries(P= 0.000 and 0.000 in medial and lateral meniscal injuries ,P=0.000 and 0.004 in medial and lateral collateral ligament injuries and P=0.032 and 0.001 in anterior and posterior cruciate ligamentous injuries respectively).A significant statistical association was seen between radiographic findings and baker's cysts, joint effusion and synovitis (P=0.000,0.000 ,0.001 and 0.000 respectively. Osteochondral bodies were seen in 15.63%of study population and were significantly associated with KL score (P=0.000).

DISCUSSION

MRI, being a multiplanar diagnostic tool is an excellent modality for evaluation of patients of osteoarthritis of knee joint. It accurately defines the extents of bony and soft tissue changes in knee joint. In this study MRI was compared with a plain radiograph of knee joint and MRI was found to be a much better diagnostic tool for evaluating the changes in bones and soft tissues in osteoarthritis of knee. Few findings from our study are noteworthy. Firstly frequency and severity of MRI changes in various tissues strongly correlated with Kellgren Lawrence grade of osteoarthritis of the knee at radiography. Secondly, MR imaging defined abnormalities were more frequent in tibiofemoral compartment than in the patellofemoral compartment.

In our study the tibiofemoral compartment which was more frequently and more severely involved in osteoarthritis of knee joint than the patellofemoral compartment. In western population, it was the patellofemoral compartment which was more frequently and more severely involved. This difference is due to sitting in squatting posture in Indian population. . Prolonged squatting has been associated with development of osteoarthritis of knee joint in tibiofemoral compartment but only slightly associated with development of osteoarthritis in patellofemoral compartment[20,21,22].

Most frequent site of osteophytosis was medial tibiofemoral joint in our study (100%) while in Curtis W. Hayes et al study patellofemoral compartment was the most frequent site of osteophytes [23] .The incidence of Grade II osteophytes was highest in medial condyle of tibia (46.87%)of the study population. The next most common site where Grade II osteophytes were seen was medial condyle of femur.

The most common site of bone marrow edema in our study was tibiofemoral compartment with the highest incidence in medial condyle of femur (78.12%) while in a previous study the patellofemoral compartment was the most common site showing bone marrow edema.[23]This difference could also be explained by the squatting posture adopted by Indian population

Subchondral cysts were also most commonly found in the tibiofemoral compartment i.e. in medial condyle of femur (62.50%) followed by in medial condyle of tibia(53.12%). Grade II subchondral cysts were most frequently seen in medial condyle of tibia (25%)

Almost all patients in our study showed presence of cartilage

defects, the tibiofemoral compartment being more commonly involved than the patellofemoral compartment. Grade III B cartilage defects were most commonly seen in medial tibial condyle (40.62%) and medial femoral condyle (34 .37%). In contrast, Curtis W. Hayes et al reported maximum number of cartilage defects in patellofemoral compartment and trochlea was the most common location for grade IIIB lesions in their study [23] .

It is noticeable that defects of cartilage of Grade II a or higher and bone marrow edema were evident on MR images, even on those knees which were classified as normal on radiography

In our study subchondral sclerosis and cysts were more commonly seen in tibiofemoral joint than the patellofemoral joint as reported earlier in literature[23] .Medial articulating surface of tibia showed the highest frequency of subchondral sclerosis (75%of study subjects) and also subchondral sclerosis of larger size , followed by medial articulating surface of femur(59.37% of study subjects). Majority of subchondral cysts and subchondral sclerosis were reported by Curtis W. Hayes et al seen in patellofemoral compartment [23]

The incidence of medial and lateral meniscal injuries are almost equal in our study(90.62% and 96.87% respectively)of which 46.87% and 53.13% of patients showed Grade II tears of medial and lateral meniscus respectively. These findings are in accordance with the previous study [23]. Collateral ligament injury was rarely seen in our study. Anterior cruciate ligament and posterior cruciate ligament injury was seen in 25% and 34.37% of cases, respectively Joint effusion of varying grades was seen in 78.13% of cases in our study. Mild grade of synovitis was seen in 25% of patients. Baker's cysts of varying grades were seen in 40.63% of study population. Osteochondral bodies were seen in 15.63% patients. 25 % patients showed presence of subluxation of tibia, lateral subluxation being the most common.

We found a statistically significant correlation between majority of MRI changes of osteoarthritis in tibiofemoral compartment of knee joint and KL score. There is a poor correlation between MRI and KL score for diagnosing changes in the patellofemoral compartment. This could be explained, as lateral or skyline views of the knee were not used in the categorization of the radiographic severity of OA in our subjects, that is why radiographically determined patellofemoral involvement was relatively underdiagnosed.The disparity in sensitivity between MR imaging and standard radiography for detection of abnormalities, especially in the patellofemoral compartment, may partly explain the observation that anatomical changes in OA of the knee long precedes the radiographic evidence of OA of the knee but can be diagnosed by MRI at an early stage. Our data show that there were more frequent and more severe abnormalities detected at MR imaging as the radiographically determined grades of OA of the knee increased.

Increasing Kellgren Lawrence scores were associated with more frequent and more severe defects of cartilage, bone marrow edema, osteophytes, subchondral sclerosis and subchondral cysts in tibiofemoral compartment, joint effusion, osteochondral bodies and presence of meniscal tears. These finding reinforce the evolving concept that OA of the knee is a whole-organ disease and that MR imaging is capable of showing the bone and soft-tissue evidence of OA of the knee at an early stage [23].

References

1. From the Centers for Disease Control and Prevention. Prevalence and impact of arthritis among women—United States, 1989–1991. JAMA 1995;273:1820–1821.
2. Praemer A, Furner S, Rice DP. Musculoskeletal conditions in the United States. Park Ridge, Ill: American Academy of Orthopedic Surgeons, 1992.
3. Spector TD, Hart DJ, Huskisson EC. The use of radiographs in assessing the severity of knee osteoarthritis. J Rheumatol Suppl 1991;27:38–39.
4. Altman RD. Criteria for classification of clinical osteoarthritis. J Rheumatol Suppl 1991;27:10–1
5. Brandt KD, Fife RS, Braunstein EM, Katz B. Radiographic grading of the severity of knee osteoarthritis: relation of the Kellgren and Lawrence grade to a grade based on joint space narrowing, and correlation with arthroscopic evidence of articular cartilage degeneration. Arthritis Rheum 1991;34:1381–1386.
6. Hannan MT, Felson DT, Pincus T. Analysis of the discordance between radiographic changes and knee pain in osteoarthritis of the knee. J Rheumatol 2000;27:1513–1517.
7. Peterfy CG. Imaging of the disease process. Curr Opin Rheumatol 2002;14:590–596.
8. Peterfy CG, Guermazi A, Zaim S, et al. Whole-Organ Magn Reson Imaging Score (WORMS) of the knee in osteoarthritis. Osteoarthritis Cartilage 2004;12:177–190.
9. Kellgren JH, Lawrence JS. Epidemiology of chronic rheumatism. Philadelphia, Pa: Davis, 1963.
10. Noyes FR, Stabler CL. A system for grading articular cartilage lesions at arthroscopy. Am J Sports Med 1989;17:505–513.
11. Zanetti M, Bruder E, Romero J, Hodler J. Bone marrow edema pattern in osteoarthritic knees: correlation between MR imaging and histologic findings. Radiology 2000;215:835–840.
12. Lal NR, Jamadar DA, Doi K, et al. Evaluation of bone contusions with fat-saturated fast spin-echo proton-density

magnetic resonance imaging. Can Assoc Radiol J 2000;51:182–185.
13. Boegard T, Rudling O, Petersson IF, Jonsson K. Correlation between radiographically diagnosed osteophytes and magnetic resonance detected cartilage defects in thepatellofemoral joint. Ann Rheum Dis 1998; 57(7):395-400.
14. Tschirch FT, Schmid MR, Pfirrmann CW, Romero J, Hodler J, Zanetti M. Prevalence and size of meniscal cysts, ganglionic cysts, synovial cysts of the popliteal space, fluid-filled bursae, and other fluid collections in asymptomatic knees on MR imaging. AJR Am J Roentgenol 2003;180:1431–1436.
15. Bergman AG, Willen HK, Lindstrand AL, Pettersson HT. Osteoarthritis of the knee: correlation of subchondral MR signal abnormalities with histopathologic and radiographic features. Skeletal Radiol 1994;23:445–448.
16. Catherine l. hill, Daniel g. gale, Christine e. chaisson, Katherine skinner, Lewis kazis, M. elon gale, and David t. felson;et al Knee Effusions, Popliteal Cysts, and Synovial Thickening: Association with Knee Pain in Osteoarthritis J Rheumatol 2001;28:1330-7.
17. Fernandez-Madrid F, Karvonen RL, Teitge RA, Miller PR, An T, Negendank WG. Synovial thickening detected by MR imaging in osteoarthritis of the knee confirmed by biopsy as synovitis. Magn Reson Imaging 1995;13:177–183.
18. Schweitzer ME, Falk A, Pathria M, Brahme S, Hodler J, Resnick D. MR imaging of the knee: can changes in the intracapsular fat pads be used as a sign of synovial proliferation in the presence of an effusion? Am J Roentgenol 1993;160:823–826.
19. Crues JV, Mink J, Levy TL, Lotysch M, Stoller DW. Meniscal tears of the knee: accuracy of MR imaging. Radiology 1987;164:445–448.
20. Radin E L ; Paul I L;Rose R M. Role of mechanical factors in pathogenesis of primary osteoarthritis. Lancer 1972;I:519-22.
21. Cooper c.,Mc Alindon T ,Snow S et al Individual risk factors for symptomatic osteoarthritis of knee. Osteoarthritis and cartilage1992;1:16-7.
22. Davis MA ,Ettinger WH,Neuhaus J M,Cho S A,Hauck W W. The association of knee injury and obesity with unilateral and bilateral osteoarthritis of knee Ann J epidemiol 1989 ;130 278-88.
23. Curtis W. Hayes, MD, David A. Jamadar, MB, BS, Gavin W. Welch, PhD, Mary L. Jannausch, MS, Laurie L. Lachance, PhD, Diana C. Capul, BA and MaryFran R. Sowers, PhD; et al Osteoarthritis of the Knee: Comparison of MR Imaging Findings with Radiographic Severity Measurements and Pain in Middle-aged Women Radiology 2005;237:998-1007.

Author Information

Vindhya JOSHI, M.D.
Department Of Radiodiagnosis, CSMMU

Ragini Singh, MD DMRE FICR
Department Of Radiodiagnosis, CSMMU

Neera Kohli, M.D FICR FIMSE
Department Of Radiodiagnosis, CSMMU

Umesh Chandra Parashari, M.D.
Department Of Radiodiagnosis, CSMMU

Ashish Kumar, M.S. DNB
Department Of Orthopaedics, CSMMU

Vinita Singh, M.D.
Department Of Orthopaedics, CSMMU