

Solitary Fibrous Tumor Of Pleura: A Rare Tumor

M Atul, P Ashish, M Rajinder

Citation

M Atul, P Ashish, M Rajinder. *Solitary Fibrous Tumor Of Pleura: A Rare Tumor*. The Internet Journal of Oncology. 2005 Volume 3 Number 2.

Abstract

Solitary fibrous tumor of pleura is rare tumors arising from the submesothelial tissue. They differ from the malignant mesotheliomas in having an indolent course, no association with asbestos exposure and a better prognosis than mesotheliomas. Surgery is curative in case of adequately done wide resection. Inadequate resection causes a significantly shorter survival and a high incidence of local recurrence.

INTRODUCTION

Primary tumors of pleura were divided into diffuse and localized form by Klemperer and Rabin in 1937.¹ Diffuse pleural tumors are mesothelioma which are more common than localized or solitary form, arise from mesothelial tissue, are associated with asbestos exposure, and almost always have a fatal course. Solitary tumors are less common, of mesenchymal origin, not related to asbestos exposure, and have a better prognosis than the diffuse variety. The origin of these tumors is controversial, and their nomenclature not consistent, with names such as fibroma, neurofibroma, fibrosarcoma, myxosarcoma, localized fibrous mesothelioma, submesothelial fibroma, benign fibrous mesothelioma, etc...² The preferred term is Solitary Fibrous Tumor (SFT).³ There is no relation between SFT and mesothelioma but they are frequently confused with mesotheliomas. So there is a need to clarify the diagnosis and management of these tumors.

CASE HISTORY

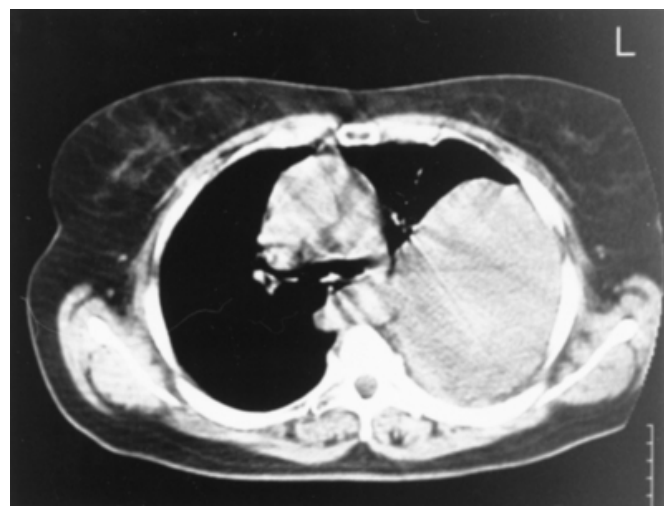
CASE 1

A 50 year old female presented with progressive shortness of breath for two years. She had no other remarkable history such as chest pain, cough, fever, smoking or alcohol use. On physical examination, the percussion note was dull at the base of left lung and breath sounds were also absent in the corresponding area. The rest of the general physical examination and chest examination was normal. Baseline laboratory investigations (Hemogram, Renal function test) were normal. The chest X-Ray (CXR) revealed an opacity in the left hemithorax, suggesting pleural effusion. Pleural tap was attempted, but it was a dry tap and a subsequent CT

scan of chest was to rule out organized empyema or a solid tumor. The CT scan of the chest showed a 14 x 10 cm mass in the left hemithorax causing compression atelectasis of the underlying lung with a shift of the mediastinum towards the right side (Fig 1).

Figure 1

Figure 1: CT scan of the thorax demonstrating a large, well-delineated mass with displacement of the mediastinal structures to the right. No signs of infiltration are seen.

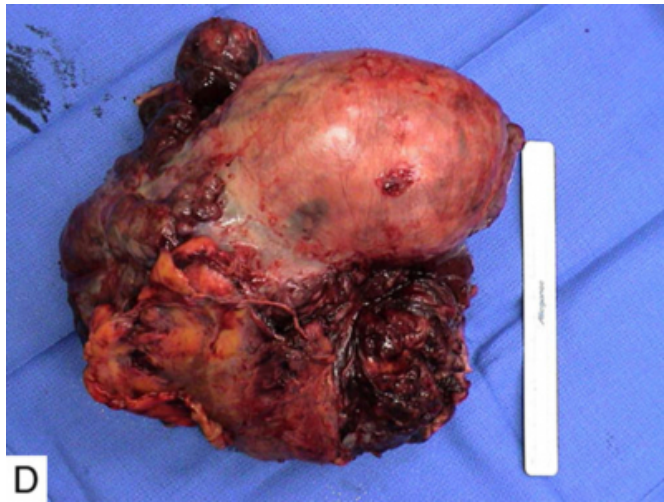


The mass was enhancing homogeneously with the intravenous contrast with no signs of infiltration of the underlying lung. A pre-operative work up was completed including pulmonary function tests which showed a restrictive effect. The patient was optimized and a left posterolateral thoracotomy was performed. Intra-operatively, the tumor was arising from the dorsal pleura of the left chest and attached to the pleura by a thick stalk of 1.5 cm. There were no adhesions to the underlying lung. The pedicle was

ligated in the stalk and the tumor removed (Fig 2). No rib was excised and the chest wall was closed after ensuring the lung expansion and placing chest drains. The histopathology examination showed spindle cells with collagen formation and sporadic mitoses, which was consistent with SFT of the pleura. He patient has been on regular follow up for 30 months and there is no evidence of recurrence.

Figure 2

Figure 2: Resected specimen

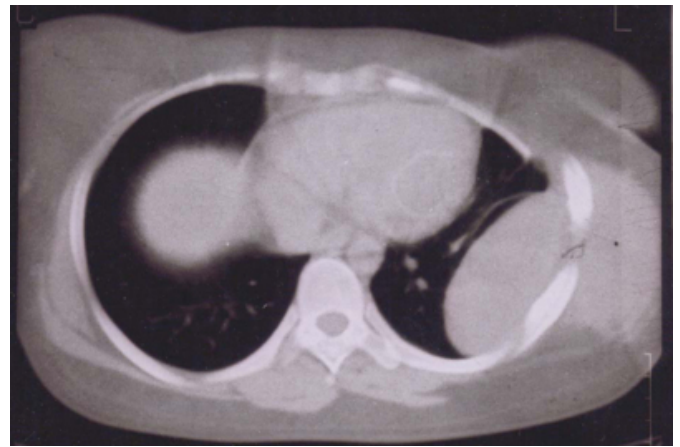


CASE 2

A 27 year old female, previously operated for SFT of the left chest two years ago, now complained of left sided chest pain for six months with no other remarkable history. On physical examination, the percussion note was dull in the mid-axillary line over the 4th to 7th ribs and the breath sounds were also reduced in the corresponding region. The rest of the laboratory work up was normal. A CT scan of the chest showed a 6 x 4 cm mass lesion arising from the left chest wall with exophytic and endophytic components and homogenously enhancing on intravenous contrast (Fig 3).

Figure 3

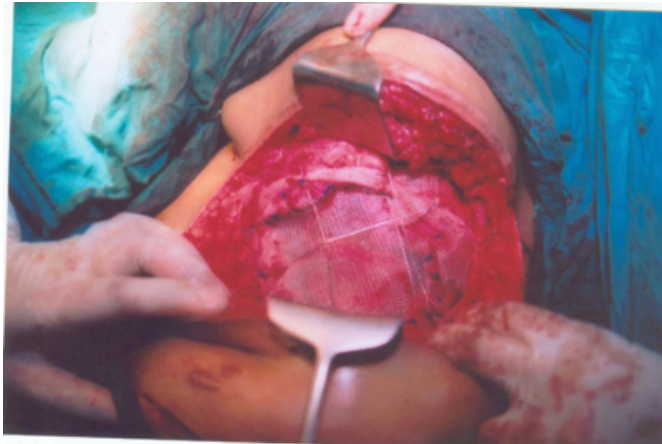Figure 3: CT scan of the thorax demonstrating a mass lesion arising from left chest wall with endophytic and exophytic components



There was no evidence of infiltration of the underlying lung or of mediastinal shift. After completing the pre-operative work up, a wide resection of the tumor was done along with the 4th to 8th ribs which were grossly involved by the tumor. The wide resection left the patient with a large chest wall defect of 12 x 10 cm that was reconstructed in a physiological manner to prevent a paradoxical movement of that segment of the chest wall. This defect was reconstructed by using a polypropylene mesh (15 x 15 cm) spread and fixed with sutures across the defect and re-enforced with the steel wires making a framework across the defect (Fig 4). Expansion of the lung was ensured and chest drains were placed. Overlying skin could be closed primarily by mobilizing skin flaps locally. The histopathology examination was consistent with SFT. Post-operatively all the components of the chest wall were moving synchronously. The patient has been on regular follow up for eight months and there is no evidence of recurrence.

Figure 4

Figure 4: Chest wall defect being reconstructed with polypropylene mesh and steel wires



DISCUSSION

The first case of SFT was described by Wagner in 1870 in his article “Das Tuberkelähnliche Lymphadenom”, more than a half century earlier than the classification of primary pleural tumors into diffuse and solitary form.⁴ SFTs are rare tumor representing less than 5% of all neoplasms involving pleura.⁵ They arise from the submesothelial connective tissue. They may arise from both visceral as well as parietal pleura with two third of them arising from the visceral pleura and the remaining one third from the parietal pleura.⁶ They also occur in other unusual sites such as the pericardium, the anterior mediastinum, the lung parenchyma, the breast, the nose & paranasal sinuses, the upper respiratory tract, the liver, the thyroid, the parotid, the periosteum and the orbit. SFT occurs at all ages but peaks in the sixth and seventh decades of life with equal incidence between men and women.

They may remain asymptomatic, with 40% of the cases being incidentally diagnosed while investigating an unrelated pathology. Sixty percent of patients are symptomatic at the time of diagnosis with the most common symptoms being dyspnea, coughing, and chest pain.⁷ Extrathoracic manifestations include clubbing of fingers in the form of hypertrophic pulmonary osteoarthropathy and hypoglycemia.⁸ Both paraneoplastic syndromes are more common in tumors larger than 8 cm in size and resolve with surgical resection of the tumor.^{8,9} Hypoglycemia is caused by tumor production of insulin like growth factor II.⁹ Only thirteen percent of cases have an aggressive clinical behavior with local infiltration or local recurrence and even distant metastases in some cases. The majority of cases (about 87%) have a benign clinical behaviour.⁸

The conditions commonly confused with SFT include pleural mesothelioma, peripheral bronchial carcinoma, solitary pleural metastasis, and empyema as we first diagnosed in case 1. A CXR may be very helpful in the diagnosis by providing the initial clue, but the CT scan remains the investigation of choice for its ability to assess resectability of the tumor and its relationship to the neighboring structures. MRI is the most sensitive technique to detect the invasion into adjacent structures and is more useful than CT when cost is not a constraint. Fine needle aspiration cytology (FNAC) is inconclusive in most of the cases as tumor contains acellular as well as hypocellular areas and the material obtained is not representative. Definitive diagnosis is usually obtained by histopathology after surgery as in both cases described.

Macroscopically, 80% of tumors arise from but do not invade the visceral pleura. Half of the tumors are pedunculated and half are sessile. On sectioning, they are grey white in color and harbor areas of necrosis and hemorrhage. The microscopic picture of these benign tumors is a “patternless pattern” with fibroblast, collagen, and reticular fibers arranged haphazardly or arranged in a hemangiopericytoma like pattern. A malignant variant is characterized by high cellularity, marked pleomorphism, and high mitotic activity and is seen in 10 to 15% of cases. Most specimens are CD34 and vimentin positive on immunohistochemical staining.

The recommended treatment for SFT is wide resection with complete resection of tumor and its pedunculated portion along with the site of origin. Five year survival rates as high as 97% have been reported with adequate excision. However, with incomplete resection or malignant transformation, the median survival is only 24 to 36 months.¹⁰ The treatment of choice of recurrent disease is re-excision as in case 2. The prognosis of the patient depends in decreasing order of importance on resectability, size of tumor, mitotic count, and pleomorphism. Clinical and radiological follow up are indicated for both benign and malignant SFTs.

CORRESPONDENCE TO

Ohri Ashish, Senior registrar, Dayanand Medical College and Hospital, 3888, Street no 2, opp UCO bank, Durga Puri, Haibowal kalan, Ludhiana, 141001. Punjab, India. Email: ashohri@yahoo.com Phone: +91-9815550159, +91-161-2311-317

References

1. Klemperer P, Rabin CB. Primary neoplasms of the pleura. A report of five cases. Arch Pathol 1937; 11: 385-412.
2. Hernandez FJ, Fernandez BB. Localized fibrous tumors of pleura. Cancer 1974; 6: 1667-1674.
3. Hanau CA, Miettinen M. Solitary fibrous tumor: histological and immunohistochemical spectrum of benign and malignant variants presenting at different sites. Human Pathol 1995; 26: 440-449.
4. Wagner E. Das tuberkelähnliche lymphadenom (Der cytogene oder reticulirte Tuberkel). Arch Heilk (Leipzig) 1870; 11: 497- 499.
5. Drachenberg CB, Bouquin PM, Cochran LM. Fine needle aspiration biopsy of solitary fibrous tumors. Acta Cytol 1998; 42:1003-1010.
6. Magdeleinat P, Alifano M, Petino A. Solitary fibrous tumors of the pleura: clinical characteristics, surgical treatment and outcome. Eur J Cardiothorac Surg 2002; 21:1087 - 1093.
7. Briselli, M, Mark, EJ, Dickersin, GR. Solitary fibrous tumors of the pleura. Cancer 1981; 47: 2678-2689.
8. Okike, N, Bernatz, E, Woolner, B. Localized mesothelioma of the pleura. J Thorac Cardiovasc Surg 1978; 75:363-372.
9. Baxter, RC, Holman, SR, Corbould, A. Regulation of the insulin-like growth factors and their binding proteins by glucocorticoid and growth hormone in nonislet cell tumor hypoglycemia. J Clin Endocrinol Metab 1995; 80: 2700-2708.
10. de Perrot M, Fischer S, Brundler MA, Sekine Y, Keshavjee S. Solitary fibrous tumors of the pleura. Ann Thorac Surg 2002; 74:285-293.

Author Information

Mishra Atul, M.S.

Asst. Professor of surgery, Dayanand Medical College and Hospital

Phri Ashish, M.S.

Senior Registrar, Dayanand Medical College and Hospital

Mittal Rajinder, M.Ch.

Asst. Professor of plastic surgery, Dayanand Medical College and Hospital