

Pseudoaneurysm Of Axillary Artery Following Shoulder Dislocation

N J.S., R Ranganath, S Srinath

Citation

N J.S., R Ranganath, S Srinath. *Pseudoaneurysm Of Axillary Artery Following Shoulder Dislocation*. The Internet Journal of Emergency Medicine. 2003 Volume 2 Number 1.

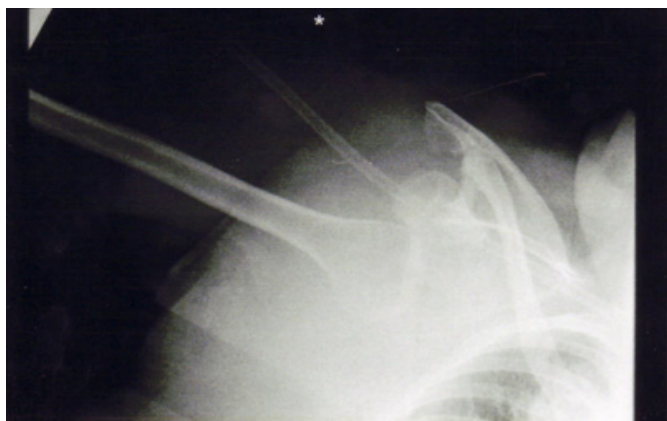Abstract

Axillary arterial pseudoaneurysms are uncommon. Although infrequently seen as an iatrogenic complication very few cases have been reported following postero-inferior dislocation of the shoulder joint. We present one such case, which was successfully managed by surgical intervention. Although uncommon, pseudoaneurysms should not be forgotten after trivial trauma. Upper limb pseudoaneurysms should be recognised early because of the risk of early vascular, neurological compromise and risk potential serious long-term sequelae .

PSEUDOANEURYSM OF AXILLARY ARTERY FOLLOWING SHOULDER DISLOCATION

A 71-year-old lady presented to A/E with a Road Traffic Accident having been side swiped by a car. Initial assessment was normal. Radiological examination of shoulder (figure 1) showed postero-inferior dislocation of right shoulder.

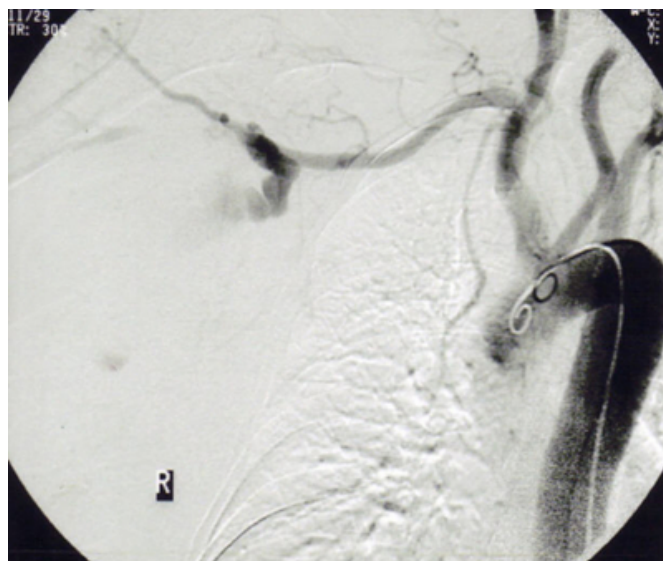
Figure 1



This was promptly reduced under sedation. There was no evidence of pneumothorax. Four weeks later , she presented to A/E again with pain in the right axilla. Examination confirmed the presence of hard pulsatile mass in the axilla with evidence of bruising. Distal radial pulse was decreased along with prolonged capillary refill. A diagnosis of false aneurysm was made and she was transferred to vascular unit. Subsequent angiogram (figure 2) confirmed the presence of axillary artery pseudoaneurysm. This was promptly repaired

from using autologous reversed long saphenous vein bypass graft. Post operative recovery was unremarkable, as was subsequent follow-up.

Figure 2



Difficulties in detecting vascular injuries associated with limb trauma are greater than generally appreciated. 25% of vascular injuries may present with normal distal pulsation¹. Angiography and Doppler are helpful in detecting occult vascular injuries. In the absence of massive bleed, or distal neurovascular deficits, most soft tissue injuries are seldom investigated, explored or followed up². Hence most occult vascular injuries present as pseudoaneurysm or an arteriovenous fistula or both. Majority of them present

during first eight weeks following injury³. Angiography is essential before surgery for delineating anatomy, collateral circulation, venous return or arteriovenous fistula. Axillary artery pseudoaneurysms are uncommon after shoulder dislocation and very few cases have been reported in literature following dislocation of the shoulder. Prompt effort should be made to diagnose this occurrence, as upper limb pseudoaneurysms tend to present serious complications and if untreated can be left with long term sequelae.

Most of the pseudoaneurysms are treated nonoperatively. Recent studies have shown that traumatic pseudoaneurysms (< 2cm) will thrombose spontaneously usually within weeks nearly always maintaining the arterial continuity. Alternatively thrombosis can be achieved from compression bandage, ultrasound guided compression directed towards the neck of false aneurysm or ultrasound guided thrombin injections. Studies have shown that this method is safe, quicker, simple to perform and effective even in patients receiving anticoagulation⁴. Surgical exploration is warranted only for rapid increase in size, uncontrolled bleeding,

compartment syndrome or the presence of an arteriovenous fistula. Pseudoaneurysms of the upper extremity is rare and comprise of <2% all pseudoaneurysms⁵.

CORRESPONDENCE TO

Mr Nagabhushan JS 1/1, 62 Ferry road Glasgow G3 8QW
0141 3343726 e mail- nags1970@aol.com

References

1. Turcotte JK, Towne JB, Bernard VM. Is arteriography necessary in the management of vascular trauma of the extremities? *Surgery* 1978;84:557-62
2. Dennis JW, Frykberg ER, Veldenz HC, Huffman S, Menawat SS. Validation of Nonoperative Management of Occult Vascular Injuries and Accuracy of Physical Examination Alone in Penetrating Extremity Trauma: 5 - 10 year follow up. *J Trauma*. 1998; 44:243-51
3. Robbs JV, Carrim AA, Kadwa AM, Mars M. Traumatic arteriovenous fistula:experience with 202 patients. *Br J Surg*.1994;81:1296-99
4. Mohler ER 3rd, Mitchell ME, Carpenter JP, Strandness DE Jr, et al. Therapeutic
5. Szendro G, Golcman L, Klimov A, Yefim C, Johnatan B, Avrahami E, Yechieli B, Yurfest S. Arterial false aneurysms and their modern management. *Isr Med Assoc J*. 2001 ;3:5-8

Author Information

Nagabhushan J.S.

Department of Surgery, Crosshouse hospital

Rao K. Ranganath

Department of Surgery, Crosshouse hospital

S. Srinath

Department of Surgery, Crosshouse hospital