

Undetected Calyceal Diverticulum with Perioperative CT IVP

A H, S D, E R, D S, K J

Citation

A H, S D, E R, D S, K J. *Undetected Calyceal Diverticulum with Perioperative CT IVP*. The Internet Journal of Urology. 2010 Volume 8 Number 2.

Abstract

A symptomatic calyceal diverticulum is a rare entity. The diverticulum may be congenital, secondary to trauma or a complication of previous surgery such as percutaneous nephrolithotomy (PCNL). A calyceal diverticulum is usually identified during urological investigation for haematuria or recurrent urinary tract infection. We report a case where the calyceal diverticulum was not detected on preoperatively despite imaging with CT IVP. Large calculi that completely fill the diverticulum increase the risk of detection failure, as minimal contrast may fill this potential space. Centrally placed calyceal diverticula are particularly difficult to identify preoperatively due to the overlying collecting system. A subtle sign that may help identify this rare lesion is the lack of movement of the calculus during retrograde pyelogram.

INTRODUCTION

A symptomatic calyceal diverticulum is a rare entity. The diverticulum may be congenital, secondary to trauma or a complication of previous surgery such as percutaneous nephrolithotomy (PCNL). Diverticula are non-secretory and have a smooth wall lined with transitional cell epithelium. It communicates with the adjacent urinary collecting system via a narrow channel¹. There is poor emptying of the diverticulum, and consequently calculi form due to stasis of urine.

The majority of cases are unilateral, and are often discovered incidentally on imaging studies. It may be detected in 0.21%-0.45% of excretory (IVP) studies². The diverticula may be located in the superior (70%), middle (12%) and lower calyx (18%)³.

In the absence of clinical symptoms or complications, calyceal diverticula can be managed conservatively. However, due to urinary stasis complications such as stone formation and infection are common. The commonest indication for therapy of calyceal diverticulum is a concomitant calculus, which is seen in up to 39% of cases. Recurrent infection of calculi may also occur in up to 25%. Further, recurrent infection may be complicated by sepsis or abscess formation².

CASE REPORT

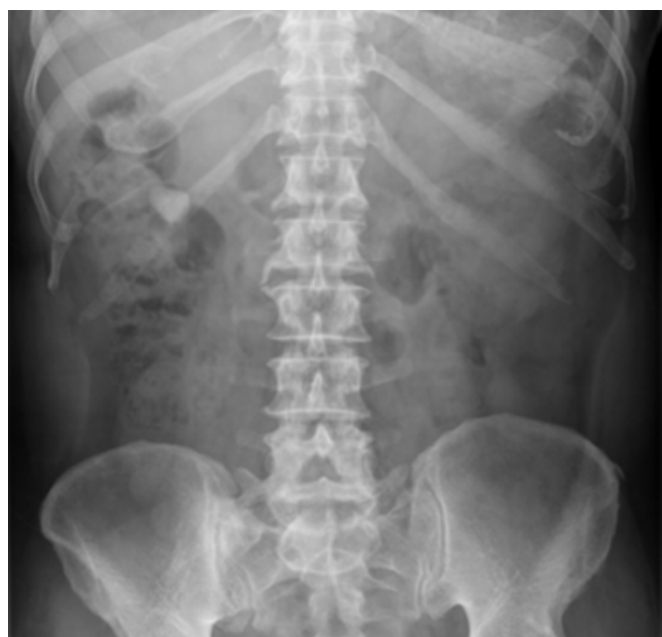A 70 year old male presented to the emergency department

with macroscopic haematuria and right flank pain. Physical examination revealed mild right-sided flank tenderness. Urinalysis was positive for red blood cells.

He proceeded to have a plain abdominal X-ray, which showed a 21mm calculus, projecting over the right renal pelvis on scout view (See Image 1).

Figure 1

Image 1: Calculus projected over right renal pelvis



A further non-contrast CT urography was performed, again showing a stone in the right renal pelvis with no other visible abnormalities (See Images 2 and 3).

Figure 2

Image 2: Right renal pelvis calculus (axial image)

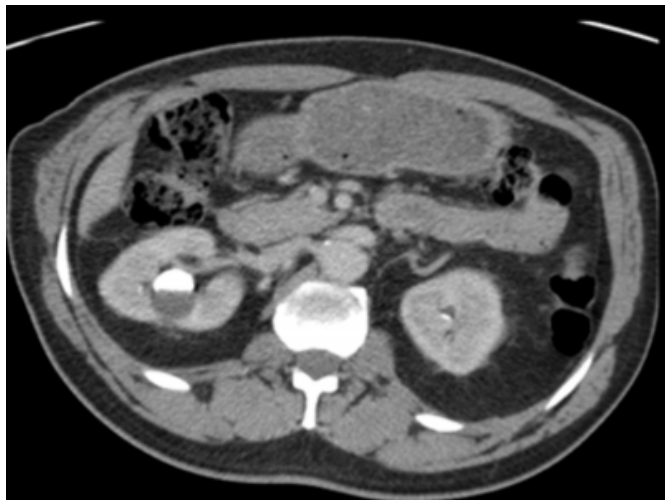
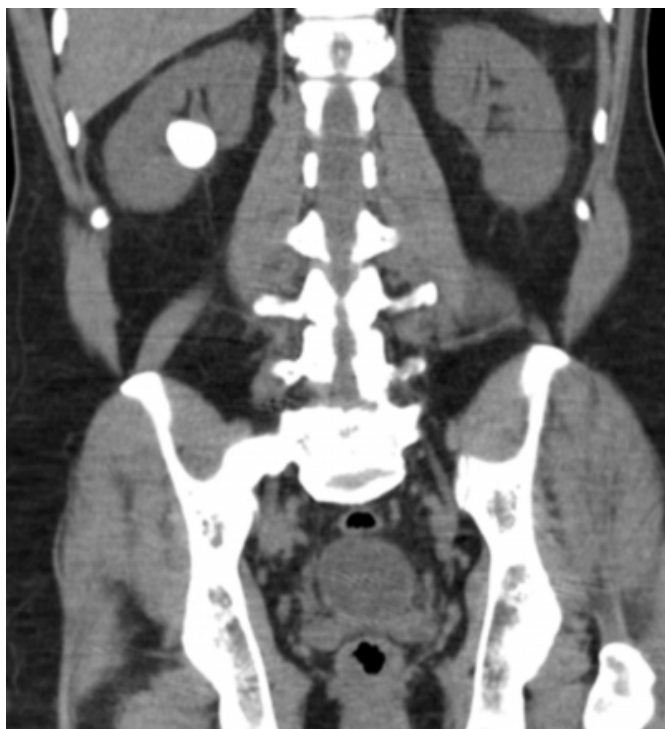
Figure 3

Image 3: Right renal pelvis calculus (coronal view)

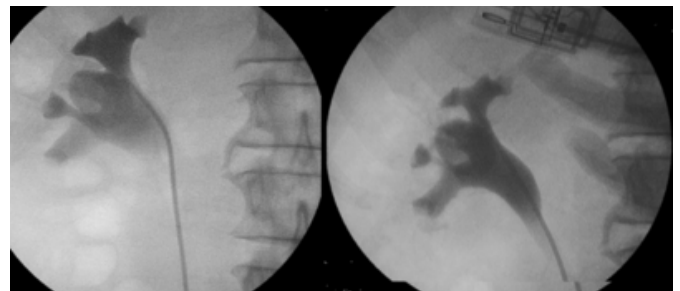


The patient subsequently underwent a percutaneous nephrolithotomy of the right kidney. A mid-pole puncture was performed and the track dilated. On entering the renal pelvis no calculus was visible. However, overlying the renal

pelvis a large radio-opaque mass was clearly visible with intra-operative imaging. Consequently the possibility of a calculus within a calyceal diverticulum was contemplated. With the assistance of fluoroscopic imaging intensifier in theatre, the position of the stone was localised (See Image 4). A direct puncture onto the calculus was performed.

Figure 4

Image 4: Direct puncture onto calculi



Following the puncture, multiple calyceal diverticular stones were retrieved. The neck of the diverticulum was identified, and was cannulated with a guide wire. The guide wire was fed through the diverticulum into the ureter. The diverticular neck was dilated with a balloon dilater. Following this procedure the lining of the diverticulum was obliterated with a roller ball and electrocoagulation. A nephrostomy tube was placed through the diverticula neck and in the renal pelvis. These were both removed on day 4 post operatively.

DISCUSSION

Calyceal diverticulum is a relatively uncommon abnormality of the renal collecting system, with an incidence of 2.1-4.5 per 1000 intravenous urogram (IVU) examinations⁴. While the incidence of diverticula is low, the frequency of stone formation is high due to urinary stasis.

With uncomplicated calyceal diverticulum, most patients are usually asymptomatic, with the abnormality only being found incidentally on imaging studies. However, this case demonstrates that calyceal diverticulum may remain obscure despite detailed imaging with CT IVP. Large calculi that completely fill the diverticulum increase the risk of detection failure, as minimal contrast may fill this potential space. Centrally placed calyceal diverticula are particularly difficult to identify preoperatively due to the overlying collecting system. A subtle sign that may help identify this rare lesion is the lack of movement of the calculus during retrograde pyelogram.

Treatment of symptomatic calyceal diverticulum is

controversial. Traditionally open exploration with suture ligation of the calyceal neck and fulguration of the diverticulum was recommended. The potential space was then packed with perinephric fat. As this procedure has significant morbidity, there has been increasing interest in minimally invasively approaches. Laparoscopy has been trialled but requires advanced laparoscopic skills due to its technical difficulty. Robot assisted laparoscopy may be of benefit to make the procedure less technically demanding. However, Robotic surgery would not reduce the difficulty of finding the diverticulum after mobilising the kidney.

Consequently a study of 17 patients demonstrated that percutaneous treatment is a suitable option for retrieval of calculi and ablation of the defect. This approach involves direct puncture of the diverticulum with the aid of intra-operative fluoroscopy, followed by dilation of the diverticular neck. Post operatively a nephrostomy tube is

placed across the diverticular neck to promote granulation and obliteration of cavity. This technique was demonstrated to be a safe with few complications. Additionally there is minimal perioperative morbidity and a relatively short average hospital stay of 4.4 days⁵.

References

1. Canales B, Monga M. Surgical management of the calyceal diverticulum (2003) *Curr Opin Urol*; 13:255-260.
2. Monga M, Smith R, Ferral H, Thomas R. Percutaneous ablation of caliceal diverticulum: long-term followup. *J Urol* 2000; 163:28-32
3. Middleton A & Pfister RC. Stone-containing pyelocaliceal diverticulum: embryogenic anatomic, radiologic and clinical characteristics (1974) *J Urol*; 111:2-6
4. Stunell H, McNeill G, Browne RFJ, et al. The imaging appearances of calyceal diverticula complicated by urolithiasis (2010) *British Journal of Radiology*; 83:888-894
5. Hulbert JC, Hernandez-Graulau JM, Hunter DW, et al. Current Concepts in the Management of Pyelocaliceal Diverticula (1988) *Journal of Endourology*; 2(1):11-17

Author Information

Aw H

Urology Department, Monash Medical Centre

Spernat D

Urology Department, Monash Medical Centre

Eapen R

Urology Department, Monash Medical Centre

Donnellan S

Urology Department, Monash Medical Centre

Kourambas J

Urology Department, Monash Medical Centre