

How To Reduce Diathermy In Tonsillectomy - Vessel Dissection Tonsillectomy (VDT): Description Of Technique And Analysis Of Results

G Barr

Citation

G Barr. *How To Reduce Diathermy In Tonsillectomy - Vessel Dissection Tonsillectomy (VDT): Description Of Technique And Analysis Of Results*. The Internet Journal of Otorhinolaryngology. 2005 Volume 4 Number 2.

Abstract

As the use of electrodissection in tonsillectomy increases, uncertainty remains concerning any association with postoperative hemorrhage. However, there is some evidence to suggest that the more diathermy is used the risk of postoperative hemorrhage increases. The technique of Vessel Dissection Tonsillectomy (VDT) is described and the results of 335 consecutive cases are presented. The results are discussed in relation to bipolar diathermy tonsillectomy and microbipolar diathermy tonsillectomy and also the U.K. National Prospective Tonsillectomy Audit. It is concluded that VDT has the advantages of cold dissection while reducing diathermy to a minimum.

INTRODUCTION

Electrocautery in tonsillectomy (1, 2), has become increasingly popular over last 20 years. Even in the United Kingdom where in 1990 most tonsillectomies were performed using cold dissection and ligatures for hemostasis (3), electrodissection is now almost equal to cold steel dissection tonsillectomy in numbers. Modifications of the original unipolar technique have occurred with bipolar diathermy being used to try and reduce diathermy trauma.; Pang described bipolar diathermy tonsillectomy(4) and Andrea (5) microsurgical bipolar cautery tonsillectomy. A later development used bipolar scissors dissection (6) and newer variations of electrocautery such as Coblation are available (7). There is uncertainty in the literature over the use of 'hot' techniques and whether increased use of diathermy leads to more secondary hemorrhage but Leinbach's review could find no positive correlation (8). The recent National Prospective Tonsillectomy Audit for England and Northern Ireland(NPTA) has suggested a dose-response relationship between diathermy and postoperative hemorrhage and concluded that diathermy should be used with caution. (9)

In order to try and reduce the amount of diathermy used and minimize intraoperative hemorrhage the technique described below evolved from traditional cold dissection.

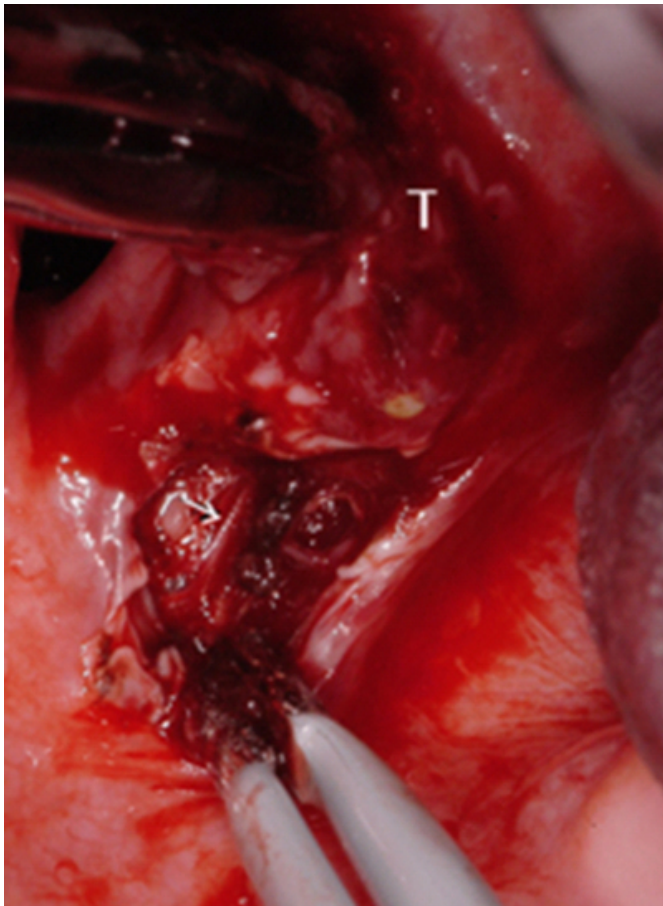
METHOD

TECHNIQUE - VESSEL DISSECTION TONSILLECTOMY (VDT)

The patient is in the standard tonsillectomy position intubated either with an endotracheal tube or a laryngeal mask under general anaesthesia. A Boyle Davis gag is in situ and bipolar diathermy is available, set at 15 Watts. A mucosal incision is made with scissors between the tonsil and anterior pillar in keeping with a cold dissection technique. The next part is crucial to the technique as uncontrolled bleeding will prevent further use of this method and the tonsil would then require to be dissected out in the traditional manner. With the tonsil being held with grasping forceps and the tips of the bipolar forceps very slightly open the mucosa at the upper pole is teased away from the tonsil with no use of diathermy. Small vessels will be visible at this point appearing as white strands running in a vertical direction (figure 1).

Figure 1

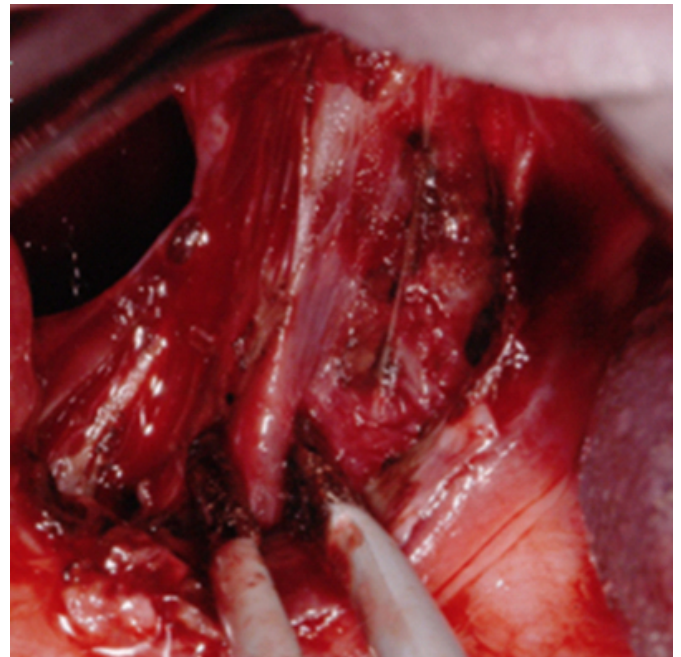
Figure 1: Upper pole being separated. T - tonsil Arrow - vessel



These are diathermised and the dissection deepened until tonsil grasping forceps can be inserted gripping the deep and superficial part of the tonsil. The dissection follows a caudal direction using the bipolar forceps in the same way gently retracting the peritonsillar tissue away from the tonsil with a combination of the forceps slightly apart and blunter dissection with the forceps closed using the outer side of the tip , diathermising the vessels as they are found . The tonsillar vein is usually encountered next (figure 2).

Figure 2

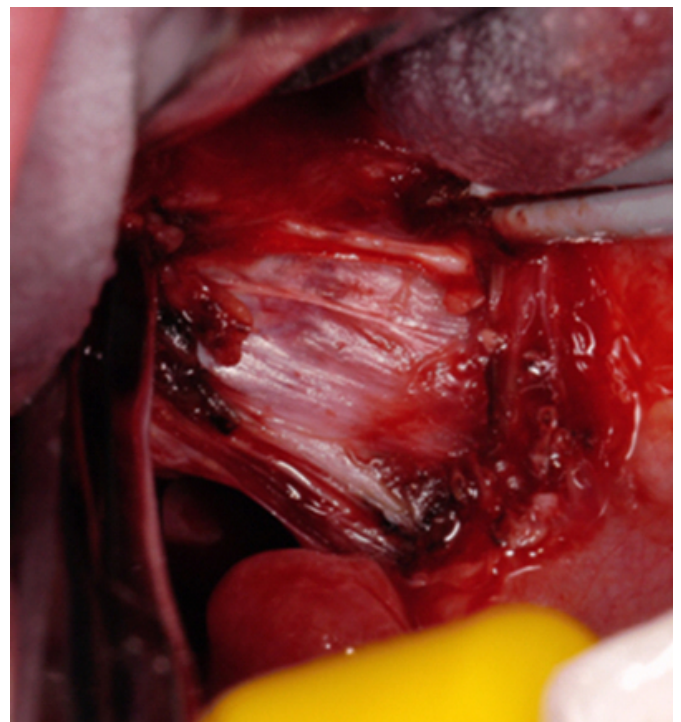
Figure 2: Tonsillar vein



As dissection proceeds inferiorly the main vessels start to come from lateral (figure 3)

Figure 3

Figure 3: Lateral vessels

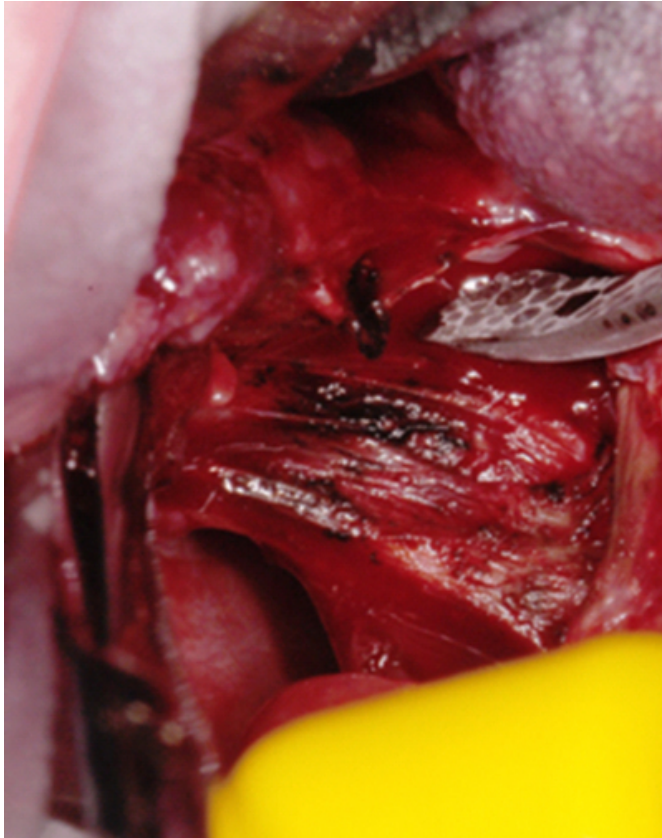


After dissection has reached about half way the angle between the forceps and tonsil bed starts to become too deep and at this point a Gwynne Evans tonsil dissector is used in

the same manner with slow dissection and gentle pressure until the vessels can be seen (figure 4).

Figure 4

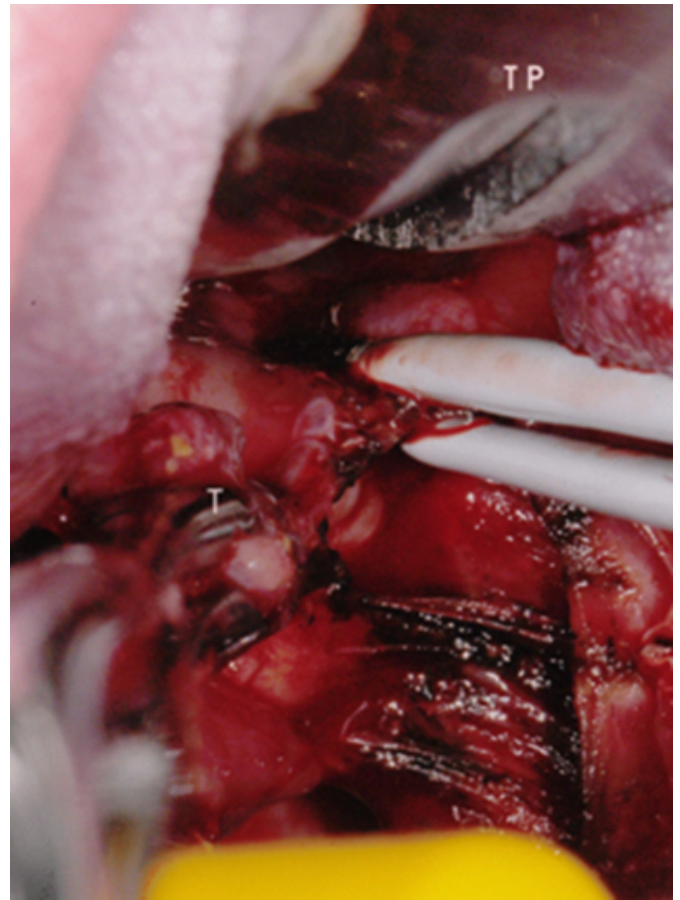
Figure 4: Careful use of the dissector



Normally the dissection plane is extended easily medially towards the lower pole as little bleeding is encountered here. Towards the lower pole just before the tongue base is reached there is often a large vessel again coming from a lateral direction (figure 5).

Figure 5

Figure 5: Lower pole vessel being diathermised. T - tonsil
TP - tongue plate



This should be looked for by pulling on the tonsil medially but also slightly towards the operator and when seen it is diathermised. Generally there are too many vessels in the lower pole tonsil pedicle to deal with individually and at this point the base of the pedicle is diathermised before using a snare. During the dissection tough fibrous strands can be weakened with diathermy and dissected with ease using the tonsil dissector without having to resort to scissor dissection. At the end of the procedure if there are any minor residual bleeding points they can be attended to easily.

ANALYSIS

Retrospective analysis of 335 consecutive adult and paediatric tonsillectomies by the author from 1994 to 2002 was carried out. Disposable instruments were used from 2001. Intraoperative time was recorded prospectively. In one post quinsy patient the quinsy side required scissor dissection and 2 ligatures to be inserted, representing a failure of the technique. This patient had a secondary hemorrhage but is included in the results. All other cases

including post quinsy had the dissection carried out using VDT .

RESULTS

POSTOPERATIVE HEMORRHAGE

No cases of primary hemorrhage occurred (defined as occurring in the first 24 hours). Significant secondary hemorrhage classified as moderate was found in seven patients (2.1 per cent). Only four patients in total (1.2 per cent) required to return to theatre ; table I gives comparative data for the NPTA. One of these patients needed transfusion (0.3 per cent), being classified as severe hemorrhage. All others patients settled with intravenous antibiotic treatment for secondary infection. 8 patients had minor or insignificant hemorrhage , either spitting a clot of blood or some blood stained saliva and had no active bleeding when seen .With a centralised service covering 883 square miles and the possibility that a minor bleed might herald a more severe bleed (although this was not found), these patients were admitted for observation and antibiotic treatment . It is acknowledged that in some series these minor cases may not be included in the results. Including these patients the overall secondary hemorrhage rate was 4.8 per cent. Hemorrhage occurred between 1 and 11 days post operatively with a median of 5.5 and mean of 6 days. The age range was 6 to 36 with a median of 18 and mean 19 years which did not differ significantly from the tonsillectomy group as a whole.

Figure 6

Table 1: Return to theatre

VDT	Number 4/335	Per Cent 1.2
NPTA		
Cold steel	13/1327	0.9
Cold Steel Unipolar Diathermy	13/613	2.1
Cold Steel Bipolar Diathermy	64/3821	1.7
Monopolar Dissection	8/198	4
Bipolar Dissection	86/3773	2.3
Bipolar Scissors	24/893	2.7
Coblation	21/684	3

SURGICAL TIME

The average time for the paediatric age group (12 years or under) over 22 tonsillectomies was 7.9 minutes per tonsil and for adults (over 12 years) 23 tonsillectomies average 10.1 minutes per tonsil. It should be emphasised that almost the entire time is used removing the tonsil in a slow and deliberate fashion . If dissection is proceeded with too quickly this will be counter productive and more bleeding will occur necessitating the use of more diathermy .

BLOOD LOSS

If this technique is applied correctly there should be no significant blood loss. This is normally so slight that it is difficult to measure accurately with some blood on the swab inserted after tonsil removal and some in the suction tubing. In adult patients particularly, there may be a slight generalised ooze during the procedure, but blood loss greater than 15ml for one tonsil removal would represent loss of control. In this series only the previously mentioned quinsy case came into this category.

PAIN

Two adult patients (0.6 per cent) were readmitted for control of pain , one for 1 day and one for 2 days.

ANTIBIOTIC TREATMENT

Antibiotic treatment was not used routinely. 2 patients with extremely large chronically infected tonsils were commenced on Co-amoxiclav postoperatively and both returned with secondary hemorrhage with one of the patients returning to theatre.

DISCUSSION

Pang (10), who described bipolar diathermy tonsillectomy felt that some blunt dissection could be carried out in the upper pole and many using this technique will attempt to reduce the amount of continuous diathermy. VDT takes this further and in smaller children it is often easy to remove the whole tonsil with the forceps alone. However in older patients the plane of dissection as the tonsil curves anteriorly towards the lower pole takes the dissection too deep . The curve of the Gynne Evans tonsil dissector is better suited to continue dissection here . If this is not done then cutting with diathermy would be required to force the plane of dissection more anteriorly, rather than using gentle pressure from the dissector.

Andrea's microbipolar technique (MBT) which is likely to have been developing at the same time as VDT would have been aiming for the same objective of minimising diathermy and diathermising only the vessels. Andrea using angled forceps and starting the dissection towards the lower pole enabled full dissection with forceps. However, starting the dissection at the more vascular part of the procedure, at least , without the microscope would require excess diathermy. For VDT dissection from the lower pole would only be needed in the unusual circumstance where the whole upper pole is so badly fibrosed that a dissection plane cannot be

found. Other than this it is easier to find a clear dissection plane from the superior end and the use of the microscope is not required. This partly explains the reduced operating time compared to MBT, Pizzuto quoting 24.2 minutes for bilateral paediatric tonsillectomy (₁₁) and Kujawski 36.9 minutes for all age groups (₁₂).

The virtually bloodless field gives excellent vision which aids the dissection and problems with retracted vessels are avoided ; both these factors further serve to reduce operating time. The only area of continuous diathermy is at the tongue base pedicle. This could be avoided by clamping and ligating the lower pole pedicle before removal, although there is unlikely to be any significant outcome benefit from this. Diathermy is only applied to the blood vessels for a minimal time and could conceivably be reduced in power from 15 Watts for the method described (noting that the amount of diathermy is a function of the power setting and time applied).

The results for VDT show an overall hemorrhage rate which is similar to bipolar diathermy tonsillectomy in the NPTA, which concludes that there is a relationship between the amount of diathermy used and the amount of postoperative hemorrhage ; the report recommends that diathermy in tonsillectomy should be used with caution . However, the VDT return to theatre rate is comparable with the best result in this study which interestingly was from cold dissection using ligatures for hemostasis . The only difference appears to be a minor increase in insignificant secondary hemorrhage for VDT .The NTPA in keeping with most reports, however, does not include blood transfusion rate , which should be considered as an indicator of severe hemorrhage and was required in only one patient in the VDT series.

Traditional cold dissection tonsillectomy despite having good results can have other associated problems such as : intraoperative blood loss (₁₃) ,blood in the pharynx on extubation, problems with retracted bleeding vessels especially at the upper and lower poles , excessive diathermy to control bleeding or even the need for ligatures or suturing in addition , poor visualisation during dissection which can lead to deeper dissection and more post operative pain. A controlled method with reliable average operating time and complete hemostasis intraoperatively seems preferable. VDT

offers this control, minimising diathermy and low significant post operative haemorrhage with no primary hemorrhage recorded. It gives the advantages of cold dissection without the disadvantages.

CONCLUSION

VDT compliments the technique of microbipolar diathermy dissection tonsillectomy described by Andrea but the use of the microscope necessary using a more straight forward dissection from upper to lower pole. The technique has the advantages of traditional cold dissection without the inherent disadvantages and reduces the use of diathermy to a minimum.

ACKNOWLEDGEMENT

To Dr B Natrajan for reviewing this manuscript.

References

1. Weimart TA, Babyak JW, Richter HJ. Electrodisssection tonsillectomy . Arch. Otolaryngology Head and Neck Surg 1990; 116: 186 - 188
2. Younis RT, Rande H, Lazar RH . History and current practice of tonsillectomy. Laryngoscope 2002; 112: 3 - 5
3. Murty GE, Watson MG, Diathermy haemostasis at tonsillectomy : current practice - a survey of U.K. otolaryngologists J Laryngol Otol 1990; 104 : 549 - 552
4. Pang YT, El-Hakim H, Rothera MP. Bipolar diathermy tonsillectomy. Clin Otolaryngol 1994 ; 19 : 355 - 357
5. Andrea M. Microsurgical bipolar cautery tonsillectomy Laryngoscope 1993; 103 : 1117 - 1178
6. Saleh HA, Cain AJ, Mountain RE. Bipolar scissor tonsillectomy Clin Otolaryngol 1999 ; 24 : 9 -12
7. Temple RH, Timms MS. Paediatric coblation tonsillectomy Int J Paediatr Otorhinolaryngol 2001 ; 61 : 195 - 198
8. Leinbach RF, Markwell SJ, Colliver JA, Lin SY. Hot versus cold tonsillectomy : a systematic review of the literature Otolaryngol Head Neck Surg 2003 ; 129 : 360 - 364
9. Van der Meulen J. Tonsillectomy technique as a risk factor for postoperative haemorrhage Lancet 2004 ; 364 : 697 - 702
10. Pang YT, Paediatric tonsillectomy : bipolar electrodisssection and dissection/snare compared J Laryngol Otol 1995 ; 109 : 733 - 736
11. Pizzuto PM, Brodsky L, Duffy L, Gendler J, Nauenberg E. A comparison of microbipolar cautery dissection to hot and cold knife cautery tonsillectomy Int J Pediatr Otorhinolaryngol 2000 ; 52 : 239 - 246
12. Kujawski O, Dulguerov P, Gysin C, Lehmann W. Microscopic tonsillectomy : a double- blind trial Otolaryngol Head and Neck Surg 1997 ; 117 : 641 - 647
13. Wei JL, Beatty CW, Gustaffson RO. Evaluation of post tonsillectomy hemorrhage and risk factors Otolaryngol Head and Neck Surg 2000 ; 123 : 229 - 235

Author Information

Gerald D. Barr, FRCS(Ed)

Department of Otolaryngology, Monklands Hospital