

Bilateral Leiomyosarcoma Of The Kidney With Family History Of Bilateral Kidney Cancer: Case Report And Review Of The Literature

H Kadikoy, W Haque, V Topkara, A Frome, T Hayes

Citation

H Kadikoy, W Haque, V Topkara, A Frome, T Hayes. *Bilateral Leiomyosarcoma Of The Kidney With Family History Of Bilateral Kidney Cancer: Case Report And Review Of The Literature*. The Internet Journal of Oncology. 2008 Volume 6 Number 2.

Abstract

We describe an unusual case of bilateral renal leiomyosarcoma in a 61-year-old white man in a patient who presented with a pulmonary embolism. The patient also had an uncle with bilateral kidney cancer. The patient did not undergo surgery, as the tumor had invaded the surrounding vasculature and was felt to be unresectable by the consulting surgeons. He was treated with gemcitabine and docetaxel chemotherapy, with stabilization of disease. Patient is now stable 10 months after beginning therapy. Sarcomas make up 1–2% of all malignant renal tumors in adult. Bilateral renal leiomyosarcomas are exceedingly rare, with only 17 being reported in the literature. To the best of our knowledge, this is the first reported case of bilateral renal leiomyosarcoma with a family history of bilateral renal cancer.

INTRODUCTION

Leiomyosarcoma of the kidney is an extremely rare clinical entity with a poor prognosis. It accounts for around 1% of all malignant renal tumors in adults and is the most common histologic subtype of renal sarcomas, amounting to around 50–60% of all cases [1, 2]. The tumors usually appear to arise from either the renal capsule or smooth muscle tissue in the renal pelvic wall. Radiologic features are non-specific and diagnosis is usually made post-operatively. Prognosis has remained fairly poor, with surgical excision being the primary treatment, and isolated reports of success with adjunctive chemotherapy and radiotherapy.

Case Presentation: A 61 year old white male presented to the ER with a 2 day history of acute dyspnea and shortness of breath. The patient began feeling fatigued 6 months prior to presentation, and was diagnosed with Stage II T2N0M0 Gleason's 6 prostate cancer one month prior to presentation. He complained of sudden onset of dyspnea that worsened with exertion and resolved upon rest. He also noticed a right-sided abdominal mass that had become larger over the past 2 weeks. The patient denied chest pain, nausea, vomiting, hemoptysis, or orthopnea. The patient had never smoked or used alcohol. He had no drug allergies and was only taking loratadine for seasonal allergies. Family history was significant for a maternal uncle with bilateral kidney cancer

of unknown origin, diagnosed at the age of 66, and his father diagnosed with prostate cancer at the age of 78. Physical examination showed a firm palpable mass spanning the right upper and right lower quadrant of the abdomen. The chest, heart, and extremities examinations were normal.

Bedside echocardiogram revealed a dilated RV with depressed function and thrombus in right atrium, concerning for blood clot or tumor thrombus. CT thorax and abdomen showed bilateral renal masses, with the right measuring 13.5 cm x 13.2 cm and the left measuring 4.7 cm x 5.2 cm (Figures 1 and 2).

Figure 1

Figure 1. CT of the abdomen showing 7x5 cm right kidney mass.

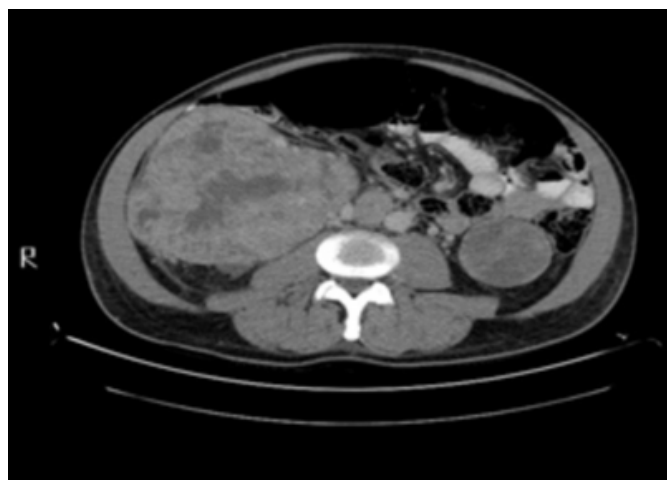
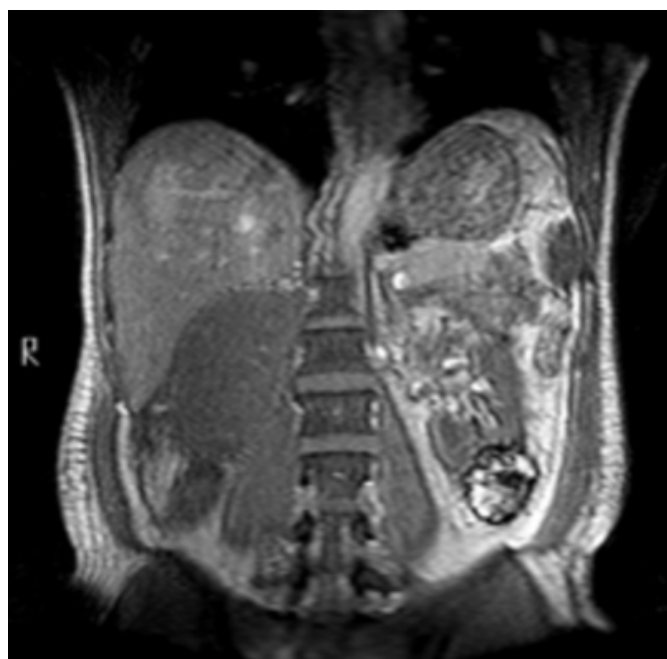

Figure 2

Figure 2. MRI of the abdomen showing bilateral kidney masses



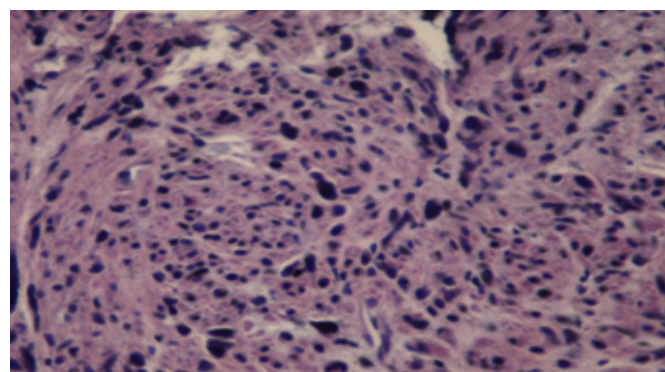
There was expansion of the IVC and of the left renal vein, consistent with tumor invasion. The differential diagnosis included both renal cell carcinoma and leiomyosarcoma.

The patient's dyspnea improved with oxygen, and he was placed on anticoagulation with heparin and coumadin. Urology and oncology were consulted to help determine a plan of care. The treatment options included bilateral nephrectomy with nephron sparing surgery, chemotherapy, and immunotherapy. Urology deemed the surgery too high

risk as the tumor had already invaded the vasculature. Oncology suggested palliative care as the cancer had already metastasized. A CT guided fine needle aspiration was performed (Figure 3).

Figure 3

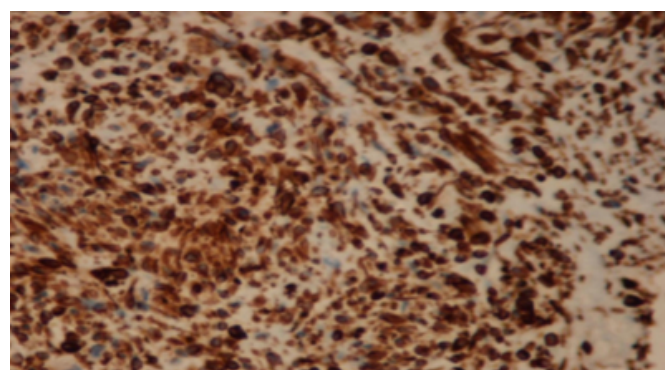
Figure 3. Photomicrograph of the tumor showing areas of spindle shaped cells. There are abnormal mitoses in the center of the slide. [H&E X100]



Immunostaining was positive for vimentin, MSA, and desmin; and negative for pancytokeratin, s-100, and c-kit; consistent with leiomyosarcoma (Figure 4).

Figure 4

Figure 4. Photomicrograph of the tumor showing positive staining for vimentin. [H & E X 100]



The patient is currently receiving palliative care and continues to have a good functional status 11 months after diagnosis.

DISCUSSION

Leiomyosarcoma of the kidney makes up 0.5–1.5% of malignant renal tumors in adults [3]. A female predominance was reported in the literature, with most patients presenting in the fourth through sixth decades of life [4]. Patients with renal leiomyosarcoma present with nonspecific findings, most commonly flank pain. Additional symptoms reported,

in order of decreasing frequency, are hematuria, abdominal mass, weight loss, and gastrointestinal disturbances [1]. Interestingly, our patient initially presented with pulmonary emboli and a right atrial thrombus, differing from the usual presentation of renal leiomyosarcoma.

The CT and MRI show the leiomyosarcoma to be a clearly demarcated multinodular mass of variable density and signal intensity. The regions that have low signal-intensity on T2-weighted MRI displayed delayed enhancement on CT and had more fibrous tissues than did other sites that had more spindle-shaped muscle cells. These distinct MRI and CT findings may help radiologists to include renal leiomyosarcoma in the differential diagnosis.[5] Renal angiography is similar to that found in other renal masses, and shows the vascular pattern of hypervascularity and irregular tortuous neoplastic vessels [6]. The histopathology of leiomyosarcoma shows a fascicular growth pattern and tumor bundles that form right angles. In regards to immunohistochemistry, the leiomyosarcoma will stain positive with vimentin, actin, smooth muscle myosin, desmin, H- caldesmon, laminin, and type IV collagen [6, 7]. Unlike sarcomas, leiomyosarcoma will stain negative for cytokeratin [1]. The diagnosis of leiomyosarcoma is usually made postoperatively by histopathology and staining due to the nonspecific presentation and radiological findings.

The treatment for leiomyosarcoma remains surgical excision. Radical nephrectomy has been employed to prevent recurrence [8]. However, 5 year survival rates in patients who received nephron sparing surgery as opposed to radical nephrectomy are similar in patients who have a primary tumor diameter of 4 cm or less [9]. Therefore, nephron sparing surgery is now recommended in patients with bilateral tumors, marginal renal function, and restricted renal tumors [4]. Leiomyosarcomas carry a poor prognosis, and patients usually die within 2 years [8, 10]. Postoperative radiotherapy and chemotherapy may result in a better

prognosis. Sharma et al [6] used adjunctive chemotherapy of Mesna, Adriamycin, Ifosfamide, and Dacarbazine with sandwich radiotherapy with a dose of 44 Gy in 22 fractions in a patient with renal leiomyosarcoma, and the patient was disease free at 72 months. The chemotherapy regimens that are most effective are doxorubicin or actinomycin D, cyclophosphamide, and vincristine. 5,000 rad adjunctive radiotherapy has been used post- surgically as well [1]. Recent studies have demonstrated the synergy of gemcitabine and docetaxel in metastatic soft tissue sarcomas, and this combination can be effective in disease control in some patients with this disease [9].

References

1. Davis R, Vaccaro JA, Hodges GF, Belville WD, Kiesling V Jr. Renal leiomyosarcoma: plea for aggressive therapy. *Urology*. 1992; 40: 168-71.
2. R Greenlee, T Murray and S Bolden, Cancer statistics, 2000. *CA Cancer J. Clin* 50 (2000) 7
3. Demir A, Yazici CM, Eren F, Turkeri L. Case report: good prognosis in leiomyosarcoma of the kidney. *Int Urol Nephrol*. 2007; 39: 7-10.
4. Cocuzza M, Arap S, Lucon AM, Saldanha LB. Renal leiomyosarcoma treated with partial nephrectomy. *Clinics*. 2005; 60: 345-6.
5. Ochiai K, Onitsuka H, Honda H, Kawamoto K, Uozumi J, Kumazawa J, Masuda K. Leiomyosarcoma of the kidney: CT and MR appearance. *J Comput Assist Tomogr*. 1993; 17: 656-8.
6. Sharma D, Pradhan S, Aryya NC, Shukla VK. Leiomyosarcoma of kidney: a case report with long term result after radiotherapy and chemotherapy. *Int Urol Nephrol*. 2007; 39: 397-400.
7. Deyrup AT, Montgomery E, Fisher C: Leiomyosarcoma of the kidney: A clinicopathologic study. *Am J Surg Pathol* 2004; 28:178-182.
8. Srinivas et al., 1984. Srinivas V, Sogani PC, Hajdu SI, Whitmore Jr. WF: Sarcomas of the kidney. *J Urol* 1984; 132:13-16.
9. Maki RG. Gemcitabine and docetaxel in metastatic sarcoma: past, present, and future. *Oncologist*. 2007 Aug;12(8):999-1006.
10. Lerner SE, Hawkins CA, Blute ML, Grabner A, Wollan PC, Eickholt JT, Zincke H. Disease outcome in patients with low stage renal cell carcinoma treated with nephron sparing or radical surgery. *J Urol*. 1996; 155: 1868-73.

Author Information

Huseyin Kadikoy

Medical Student, Department of Internal Medicine, Baylor College of Medicine

Waqar Haque

Medical Student, Department of Internal Medicine, Baylor College of Medicine

Veli Topkara, MD

Resident, Department of Internal Medicine, Baylor College of Medicine

Adam I. Frome, MD

Nephrology Fellow, Department of Nephrology, Baylor College of Medicine

Teresa G. Hayes, MD, PhD

Assistant Professor, Department of Hematology- Oncology, Baylor College of Medicine