

Bilateral Circumlimbal Cystic Change In Vernal Keratoconjunctivitis

B Ramamurthy, R Gupta, V Sangwan

Citation

B Ramamurthy, R Gupta, V Sangwan. *Bilateral Circumlimbal Cystic Change In Vernal Keratoconjunctivitis*. The Internet Journal of Ophthalmology and Visual Science. 2005 Volume 4 Number 1.

Abstract

Vernal keratoconjunctivitis(VKC) is an allergic condition that mainly affect young people between age of 3 and 25 years with usually onset before age of 10 years.¹ It is common in dry and warm climate.² The conjunctiva develops a papillary response principally of limbus and upper tarsal conjunctiva. Limbal papillae tend to be gelatinous and confluent and they occur more commonly in African and West Indian patients. The peripheral cornea may show waxing and waning, superficial stromal grey white deposition termed pseudogerontoxon. Horner-Tranta dots, which are collections of epithelial cells and eosinophils, may be found round the limbus. There have been no reports of cystic changes occurring in the perilimbal region in VKC although cyst and minute pits have been mentioned ².

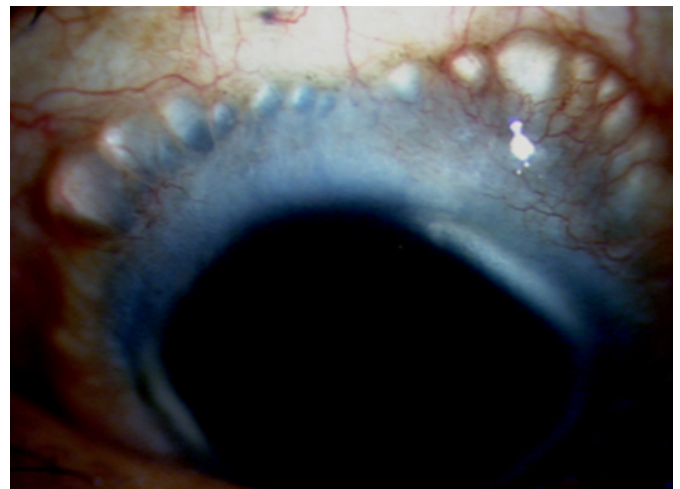
Supported in part by a grant from the Hyderabad Eye Research Foundation

CASE REPORT

A 15 year old boy presented in our institute in june 2003 with complaints of severe redness, watering and itching in both the eyes since 10 years. He denied any history of allergy or systemic disease. His visual acuity in both the eyes was improving to 6/6. On examination there was conjunctival congestion, papillae on upper tarsal conjunctivae, 360-degree limbal papillae with gelatinous nodules and Horner-Trantas dots.. There were cystic changes in perilimbal conjunctiva in both the eyes (fig 1).

Figure 1

Figure 1: Showing perilimbal multiple cysts



IOP were 10 mmHg in both eyes... He was started on topical cyclosporin 2%, cromlyn sodium, prednisolone acetate and lubricant eye drops. During subsequent visits, patient was symptomatically better while on treatment but symptoms reappeared on discontinuation of medications. In quiescent phases upper tarsal conjunctiva papillae were quiet, conjunctivae had minimal congestion. But perilimbal conjunctival cysts gradually increased in number and size. These cysts were not affected by the medications.

DISCUSSION

Bonini et al ³ had described the major and minor clinical

features of VKC depending on the prevalence. Major clinical features (> 80%) include bilateral presentation; age < 20 years, itching, presence of papillae, conjunctival hyperemia, and superficial keratopathy. Minor clinical features (< 80%) include seasonal variation, male sex, symptoms such as photophobia, mucus discharge, tearing, burning, signs such as Horner – Trantas dots, corneal shield ulcer, ptosis. They have not described any perilimbal conjunctival cysts in their patients. Rao SK et al⁴ have described perilimbal pigmentation in patients with VKC. They also did not mention about any case having cystic changes in perilimbal conjunctiva. To best of our knowledge perilimbal conjunctival cysts have not been described in VKC in Medline search. In our case the cysts are gradually progressing in size and number. They were not affected by the medications used commonly for VKC. These cysts did not correlate with symptoms of our patient. Though these cysts have not caused any significant problems in our patient till now, we need to watch for some possible complications like rupture of cyst, infection of cyst contents, corneal changes like dellen formation. Probably these cysts do not

need any specific treatment until patient wants cosmetic improvement or there is some associated complication.

Further observations are required to establish the histopathologic correlation of this finding and its etiopathogenesis.

CORRESPONDENCE TO

Balasubramanya Ramamurthy MD , L V Prasad Eye Institute, L V Prasad Marg, Banjara Hills, Hyderabad 500 036, India. E-mail address: bsrmurthy@lvpei.org Telephone +91-40-2360 8262, Fax: +91-40-2354 8271

References

1. Smolin G, Thoft RA. The Cornea. 3rd edition Pg 354
2. Buckley RJ. Vernal keratoconjunctivitis. Int Ophthalmol Clin 1988;28:303-308 1988
3. Bonini S, Bonini S, Lambiase A et al. Vernal keratoconjunctivitis revisited: a case series of 195 patients with long-term followup. Ophthalmology. 2000 Jun;107(6):1157-63.
4. Rao SK, Meenakshi S, Srinivasan B, Baluswamy S Perilimbal bulbar conjunctival pigmentation in vernal conjunctivitis prospective evaluation of a new clinical sign in an Indian population. Cornea. 2004 May;23(4):356-9

Author Information

Balasubramanya Ramamurthy, M.D.

Cornea and Anterior Segment Services, L.V Prasad Eye Institute

Rakesh Gupta, DOMS

Cornea and Anterior Segment Services, L.V Prasad Eye Institute

Virender S. Sangwan, M.S.

Cornea and Anterior Segment Services, L.V Prasad Eye Institute