

Surgical emphysema and abscess of the thigh – a rare presentation of retroperitoneal perforation of sigmoid colon

S Kumar, P Wong, V Kurup

Citation

S Kumar, P Wong, V Kurup. *Surgical emphysema and abscess of the thigh – a rare presentation of retroperitoneal perforation of sigmoid colon*. The Internet Journal of Surgery. 2009 Volume 22 Number 2.

Abstract

Peritonitis from sigmoid diverticular perforation is a common surgical problem. However, atypical presentations may be difficult to recognise clinically and hence may result in delay in diagnosis. We present a patient who presented with an abscess and subcutaneous emphysema in the right thigh from a retroperitoneal perforation of the sigmoid. The types and implications of the various clinical presentations are discussed as is the differential diagnosis of thigh abscesses.

INTRODUCTION

Perforation of the sigmoid colon is a common cause of faecal peritonitis in the elderly. It does not usually pose diagnostic difficulties as patients often present with overt signs of peritonitis or intra-abdominal abscess. However, occasionally the presentation may not be classical, leading to diagnostic dilemmas and delays in treatment. The clinical presentation featured here describes a patient with diverticular perforation of the sigmoid colon who presented with dominant signs and symptoms in the right thigh.

CASE REPORT

A sixty-three-year-old lady with a background of histologically proven indeterminate proctosigmoiditis of four years duration, being treated with Mesalazine (400mg t.d.s.), Prednisolone (20mg o.d.) and 6-Mercaptopurine (50mg o.d.) was admitted to the medical ward with a history of malaise, anorexia with mild pyrexia for 5 days and a few episodes of diarrhoea. Her other significant past medical history included a deep vein thrombosis and pulmonary embolism 8 months earlier for which she had been warfarinised.

She had no abdominal pain on admission. On examination, she was frail, mildly dyspnoeic and pyrexial (38.2°C). Physical examination of the chest and abdomen was unremarkable and urine dipstick test did not reveal any abnormalities. Over the next four days she continued to have low-grade pyrexia with no localising symptoms or signs of a septic focus. Inflammatory markers were raised with a total leukocyte count of $12.1 \times 10^9/L$ and a C-reactive protein of

352mg/dl. An erect chest X-ray (PA view) was unremarkable. Urine culture was sterile. The abdomen continued to be soft and non-tender.

On the fifth day after admission she complained of pain in her right thigh and hip. An orthopaedic and surgical consultation was sought. Examination showed significant crepitus in the proximal right thigh and around the hip, suggesting subcutaneous emphysema along with fluctuation in keeping with an abscess. There was minimal tenderness to deep palpation in the lower abdomen. A plain film of the right hip and thigh confirmed free gas in the soft tissues (fig.1). A CT scan of the abdomen showed the free air and the pus to be tracking from within the abdomen (fig 2).

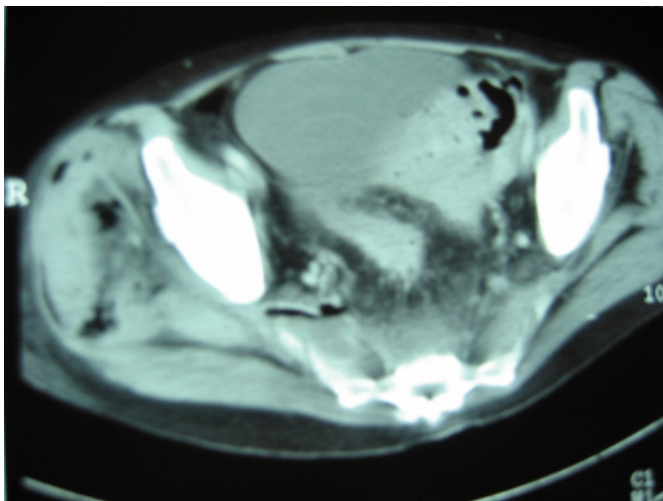
Figure 1

Figure 1. Plain X-ray of the right hip and thigh showing gas in the soft tissues.

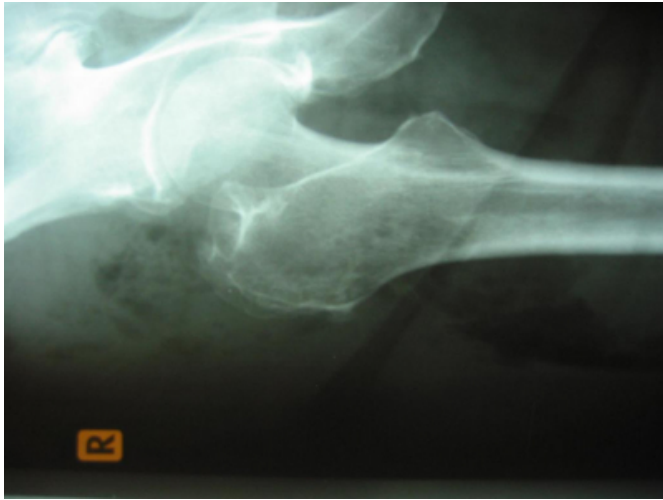

Figure 2

Figure 2. CT scan of pelvis showing air in the retroperitoneum tracking across the region of the sciatic notch on the right side. Air is also seen in the gluteal muscles.



At laparotomy, the sigmoid colon was inflamed and adherent to the presacral region. There was a well walled-off perforation of the sigmoid colon in communication with the retroperitoneum posteriorly. There was no contamination of the general peritoneal cavity. Pus and air was seen to be tracking from the site of perforation in the sigmoid into the retroperitoneum and into the right thigh. A Hartmann procedure was performed resecting the sigmoid colon, the histology of which showed diverticular perforation. The abscess in the thigh which was diffuse and intermuscular was drained by multiple incisions. The patient had a slow

but uneventful recovery.

DISCUSSION

Bowel perforations that present to the surgeon classically manifest the so-called 'peritoneal signs' of tenderness, rebound tenderness, guarding or rigidity to a varying degree. Less convincing presentations do occur, and unless there is a high index of suspicion for their occurrence, they may lead to delays in diagnosis, targeted investigations, optimisation and treatment.

These unusual presentations may be grouped into two distinct categories: (a) Masked or subdued signs pattern - examples include patients on high dose steroids and frail elderly patients in whom abdominal signs may be very subtle despite a florid peritonitis [1,2]. Well walled-off perforations may also fall into this category. (b) Remote signs pattern – wherein the signs are anatomically far removed from the abdomen itself. The patient described here did have a walled-off perforation into the retroperitoneum that tracked down to the thigh and hence presented with remote signs which overshadowed the abdominal symptoms and signs.

The peritoneum, which envelopes the abdominal cavity from within, forms one continuous barrier separating most of the viscera from a potential space - the retroperitoneum. The retroperitoneum in most regions contains loose areolar tissue through which a plane of dissection could be created by air or fluid under pressure. This provides a mechanism by which the barrier, if breached, allows contents to travel along the path of least tissue resistance to anatomically remote regions. This probably explains the surgical emphysema of neck and pneumomediastinum described after appendicular perforation [3], cervical emphysema after diverticular perforation [4] and the subcutaneous emphysema of thigh described from perforation of the sigmoid colon. Haiart et al., in their series [5], described three patients who developed surgical emphysema of the left thigh after sigmoid perforation while in the patient described here, the signs were on the right thigh, far removed from the normal location of the sigmoid colon.

De novo abscesses of the thigh are common. Most of them occur in the region of the groin in relation to the lymph nodes. Though the rest are randomly distributed in different sites in the thigh, they are usually well localised or walled off. A diffuse abscess involving the thigh as in this patient, suggests tracking along inter-muscular planes and should

alert the clinician to a probable remote origin of the pus. This, combined with the presence of free air in the tissue planes, evident clinically as crepitus, makes it imperative to consider a bowel pathology as the source of the surgical emphysema. The differential diagnosis includes Clostridial gas gangrene, necrotising fasciitis, psoas abscess and a tuberculous cold abscess tracking from the spine.

CONCLUSION

‘Common things are common’ is a well known surgical aphorism. However, the surgeon is from time to time confronted with rare presentations of common conditions, the awareness of which would avoid delays in diagnosis and treatment and result in better outcomes. The clinical picture described in this article is one such and it underscores the importance of being aware of alternative patterns that deviate from the usual. In the presence of a diffuse

intermuscular collection of pus and crepitus in the thigh, an intra-abdominal source should be excluded.

References

1. Fletcher K. Acute symptom assessment: determining the seriousness of the presentation. *Lippincott's Primary Care Practice. Long-Term Care.* 1999; 3(2):216-230.
2. Elaine AJ. Presentation of illness in older adults: If you think you know what you're looking for, think again. *American Journal of Nursing.* 2004; 104(10):40-51.
3. McCahy P, Talbot D, Rawlinson J, Higgs MJ. Acute appendicitis presenting with surgical emphysema and pneumomediastinum. *British Journal of Clinical Practice.* 1995; 49(4): 217-8.
4. Basu S, Corless D. Cervical surgical emphysema: a rare presentation of a sigmoid colon retroperitoneal diverticular perforation. *International Journal of Clinical Practice.* 2002; 56(3): 222.
5. Haiart DC, Stevenson P, Hartley RC. Leg pain: an uncommon presentation of perforated diverticular disease. *Journal of the Royal College of Surgeons of Edinburgh.* 1989; 34(1): 17-20.

Author Information

Senthil Kumar, MBBS, MS, FRCS

Specialist Registrar in Surgery, Department of Surgery, University Hospital of North Tees

Peng Foo Wong, MBChB, MRCS

Specialist Registrar in Surgery, Department of Surgery, University Hospital of North Tees

Vijay Kumar Kurup, MBBS, FRCS

Consultant Surgeon, Department of Surgery, University Hospital of North Tees