

Benign recurrent intrahepatic cholestasis (BRIC) – a case report and review of literature

N Chawla, S Kudesia

Citation

N Chawla, S Kudesia. *Benign recurrent intrahepatic cholestasis (BRIC) – a case report and review of literature*. The Internet Journal of Pathology. 2008 Volume 9 Number 2.

Abstract

Benign recurrent intrahepatic cholestasis (BRIC) is a rare hereditary disorder characterized by recurrent and intermittent episodes of cholestasis, episodes of pruritus and jaundice with normal extra hepatic biliary tree. The disease may start in early infancy or childhood but does not proceed to cirrhosis or chronic liver disease. Treatment is mostly symptomatic. Rarity of the disease and its unpredictable clinical morbidity prompted us to report this case.

INTRODUCTION

Cholestatic jaundice in children and young adults is commonly due to viral hepatitis or drug induced liver disease. Rare causes of it include syndromes of intrahepatic cholestasis with familial pattern of occurrence. These familial cholestatic diseases share many clinical similarities with onset in early childhood and recur throughout life. At one end of spectrum is Progressive familial intrahepatic cholestasis (PFIC) which has three subtypes and culminates in cirrhosis in teenage years. At the other end is BRIC which as the name suggests has a benign course. It is characterized by intermittent episodes of cholestasis without extrahepatic bile duct obstruction. It is an autosomal recessive disorder characterised by mutation in the aminophospholipid flippase gene ATP8B1 located on chromosome 18q21₁ and is also known as Summerskill-Tygstrup-De Groote disease. There is initial elevation of serum bile acids, followed by cholestatic jaundice which generally spontaneously resolves after periods of weeks to months. In 1959, Summerskill and Walshe₂ reported 2 unrelated patients with recurrent intrahepatic cholestasis. In the following year, Tygstrup₃ described the condition in 2 distantly related 15-year-old boys living in a small village in the Faroe Islands. Onset in these patients was in the first 2 years of life. Cholestasis was demonstrated by liver biopsy and direct cholangiography. The disorder was characterized by recurrent attacks of pruritus and jaundice. During disease-free intervals, which lasted for months or years, no clinical or biochemical indication of cholestasis was found₂.

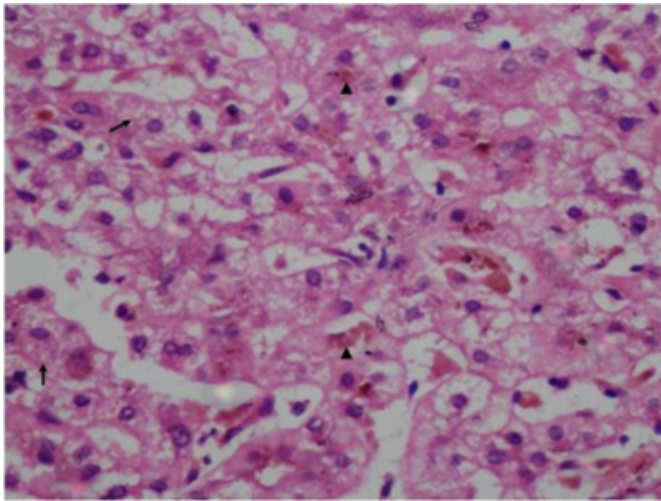
CASE REPORT

A 21 years old male presented with jaundice, dark urine and generalised itching since two months. He gave a history of three similar episodes in the past around the age of 5 years, 11 years and 18 years, respectively. There was no history of any drug or alcohol intake. On examination, apart from icterus and mild hepatomegaly there was no other abnormality on physical examination. Ultrasonography revealed mild hepatomegaly with normal bile ducts and no evidence of cirrhosis. Routine hematological parameters were in normal limits. Liver function tests revealed normal serum aspartate aminotransferase (AST), alanine aminotransferase (ALT) and γ -glutamyl transpeptidase (GGT) levels with twofold increase in serum alkaline phosphatase (ALP) levels. Other biochemical parameters were within normal limits. Liver biopsy was performed to evaluate the pathology.

Gross examination of liver biopsy showed a grey white linear fragment of tissue measuring 2.5 cms in length with areas of greenish discoloration. Microscopic examination showed hepatocytes displaying centrilobular feathery degeneration with severe cholestasis (Figure 1). Portal tracts were normal in appearance with no inflammation and there was no evidence of fibrosis.

Figure 1

Fig. 1- Photomicrograph showing hepatocytes displaying feathery degeneration (arrows) with intrahepatic bile stasis (arrowheads) (H&E, x400).



DISCUSSION

Benign recurrent intrahepatic cholestasis is a recurrent cholestatic disorder in children and adults caused by mutation in FIC-1 gene but does not progress to cirrhosis¹. It comes under a group of congenital cholestatic disorders which includes four disorders, viz., BRIC, Progressive familial intrahepatic cholestasis-1 (PFIC-1), Progressive familial intrahepatic cholestasis-2 (PFIC-2) and Progressive familial intrahepatic cholestasis-3 (PFIC-3)⁴. BRIC and PFIC-1 are caused by inherited mutation in ATP8B1 gene which was previously called FIC-1 gene, but in a different locus¹⁵. PFIC-2 is caused by mutation in gene for canalicular bile salt export pump (BSEP) gene also known as ABCB11 gene⁶, whereas; PFIC-3 is caused by mutation in MDR3 gene coding for canalicular phospholipid export pump⁷. Due to the clinical overlap of symptoms in all the four disorders, gene mapping of affected genes is required for confirmatory diagnosis, however; since there are variable histological features seen in these disorders, liver biopsy helps in reaching a conclusive opinion.

Luketic & Shiffman⁸ (1999) have proposed a diagnostic criteria for BRIC, which include: (1) At least 2 episodes of jaundice separated by a symptom free interval lasting several months to years; (2) Laboratory values consistent with intrahepatic cholestasis; (3) Severe pruritus secondary to cholestasis; (4) Normal intra and extrahepatic bile ducts confirmed by cholangiography; and (5) Absence of factors known to be associated with cholestasis⁸.

Histologically, it is characterized by simple or bland

bilirubin stasis with bile deposition in hepatocytes leading to feathery degeneration, canaliculi and Kupffer cells during episodes of cholestasis. There is no evidence of fibrosis seen as the disease doesn't progress to cirrhosis.

In PFIC-1, the patient presents within 6 months of life with growth failure, diarrhea, jaundice and sensorineural deafness. Laboratory findings show hyperbilirubinemia, profound hypoprothrombinemia and elevated alkaline phosphatase⁹. Histologically, there is bland hepatocellular and canalicular cholestasis with infiltration of biliary tracts by mononuclear cells associated with or without necrosis. There is ductular proliferation and periportal fibrosis leading to cirrhosis seen in late stages. The bile deposited in canaliculi is coarse, granular and is called Byler bile¹⁰.

PFIC-2, also called BSEP deficiency disease is a severe form of disease presenting in infancy with features corresponding neonatal hepatitis showing generalized hepatocellular unrest, parenchymal giant cells transformation associated with parenchymal bilirubin stasis. In late stages, chronic inflammation in portal tracts, cholate stasis and fibrosis leading to cirrhosis is seen⁶. However; the bile seen in this condition is filamentous as compared to coarse, granular Byler bile seen in PFIC-1. The serum GGT is normal in both PFIC-1 and PFIC-2. PFIC-2 can also be differentiated from neonatal giant cell hepatitis by immunohistochemistry using anti-BSEP antibodies^{9,11}.

PFIC-3, also called as MDR3 deficiency disease presents in early childhood and is characterized by elevated serum levels of GGT. Histologically, in contrast to PFIC-1 and PFIC-2, there is dense lymphomononuclear infiltrate associated with damage to interlobular bile ducts associated with ductular proliferation. In late cases, biliary cirrhosis may be seen⁷.

In our case, the patient is a 21 years old male and fulfilled all the 5 criteria for diagnosis of BRIC laid down by Luketic & Shiffman⁸. Laboratory investigation showed normal GGT levels ruling out PFIC-3. Histologically, liver biopsy showed feathery degeneration of hepatocytes with bile deposits in canaliculi. There was no evidence of fibrosis and inflammation in portal triads ruling out PFIC-1. PFIC-2 as well as neonatal giant cell hepatitis were ruled out due to absence of hepatic parenchymal giant cells. Further, there was no damage to interlobular bile ducts with ductular proliferation and lymphomononuclear infiltrate ruling out PFIC-3.

CONCLUSION

Liver biopsy serves as an important tool in diagnosis of various congenital cholestatic diseases where gene mapping and immunohistochemistry are not possible. Moreover, the procedure helps in differentiating BRIC having a relatively benign course from PFIC which is fatal within 10-15 years of onset if left untreated.

References

1. Bull LN, Van Eijk MJT, Pawlikowska L, et al. A gene encoding a P – type ATPase mutated in two forms of hereditary cholestasis. *Nat Genet* 1998; 18:219 – 24.
2. Summerskill WHJ, Walshe JM. Benign recurrent intrahepatic obstructive jaundice. *Lancet* 1959; 274:686 – 690.
3. Tygstrup N. Intermittent possibly familial intrahepatic cholestatic jaundice. *Lancet* 1960; 1:1171-72.
4. Jansen PLM, Muller M, Sturm E. Genes and cholestasis. *Hepatology* 2001; 34:1067 – 74.
5. Van Mil S, Klomp LWJ, Bull LN, Houwen RHJ. FIC I disease: a spectrum of intrahepatic cholestatic disorders. *Semin Liver Dis* 2001; 21:535 – 44.
6. Thompson R, Strautnieks S. BSEP: function and role in progressive familial intrahepatic cholestasis. *Semin Liver Dis* 2001; 21:545 – 550.
7. Jacquemin E. Role of multidrug resistance 3 deficiency in pediatric and adult liver disease: one gene for three diseases. *Semin Liver Dis* 2001; 21:551 – 562.
8. Luketic VA, Shiffman ML. Benign recurrent intrahepatic cholestasis. *Clin Liver Dis* 1999; 3 :509 – 28.
9. Bull LN, Carlton VE, Stricker NL et al. Genetic & morphological findings in progressive familial intrahepatic cholestasis: evidence for heterogeneity. *Hepatology* 1997; 26:155 – 64.
10. Linarelli LG, Williams CN, Phillips MJ. Byler's disease: fatal intrahepatic cholestasis. *J Pediatr* 1972; 81:484 – 92.
11. Chobert MN, Bernard O, Bulle F, Lemonnier A, Alagille D. High hepatic gamma-glutamyl transpeptidase with normal serum gamma – GT in children with progressive idiopathic cholestasis. *J Hepatol* 1989; 8:22 -25.

Author Information

Nitin Chawla, MBBS, MD

Assistant professor, Department of Pathology, SGRR Institute of medical & health sciences, Patel nagar, Dehradun, India

Sandip Kudesia, MBBS, MD, Ph.D.

Professor & Head, Department of Pathology, SGRR Institute of medical & health sciences, Patel nagar, Dehradun, India