

Subglottic Video-airway Imaging

M Weiss, C Villiger

Citation

M Weiss, C Villiger. *Subglottic Video-airway Imaging*. The Internet Journal of Anesthesiology. 1997 Volume 2 Number 3.

Abstract

Video-transmission of the view from the tracheal tube tip using the visualized endotracheal tube (VETT) or a video-optical intubation stylet is a new method to assist tracheal intubation. Subglottic airway anomalies are rare but they can cause serious problems associated with tracheal intubation. We describe a patient with unknown tracheal bronchus scheduled diagnostic laparoscopy. The tracheal bronchus was detected during conventional tracheal intubation by the monitor view transmitted from the tip of the video-optical intubation stylet. Recognition of this anomaly already during the intubation procedure allowed to place the endotracheal tube safely above the tracheal bronchus and to prevent respiratory adverse events such as hypoxemia, atelectasis and barotrauma.

Subglottic video-airway imaging is a beneficial method to detect airway anomalies and to confirm proper tracheal tube position during conventional tracheal intubation and may improve patient safety.

INTRODUCTION

Transmission of the view from the endotracheal tube tip directly onto a video display has been reported as a new method to assist tracheal intubation.^{1,2} The “visualized endotracheal tube” (VETT) or the video-optical intubation stylet loaded in a conventional endotracheal tube (ETT) allow to follow the normal intubation procedure, to confirm final ETT position and to direct the tracheal tube into the trachea when direct laryngoscopic visualization of the cords is inadequate.^{1,2,3}

We report the incidental detection of a tracheal bronchus during routine video-monitored tracheal intubation in a patient with previously unknown tracheal airway abnormality.

CASE REPORT

A 17 year old female patient was scheduled for diagnostic laparoscopic procedure. She had no previous operations and no respiratory problems. Before starting anaesthesia, a video-optical intubation stylet was inserted into the ETT and checked for proper function and clear view. Anaesthesia was induced with pentothal 5 mg/kg, fentanyl 2 mcg/kg and pancuronium 0.1 mg/kg and maintained with sevoflurane 2% in N₂O/O₂. Conventional laryngoscopy revealed a full view of the vocal cords and the tracheal tube was inserted through the vocal cords under direct vision. After passing the vocal cords the anesthetist directed her view to the video display to

confirm tracheal tube position. While advancing the ETT down the trachea, the video-view from the ETT tip revealed a right-sided tracheal bronchus near the carina (Fig. 1+2). The ETT tip was placed 2.5 cm (visually estimated) above the tracheal bronchus using the monitor view and the stylet was removed from the ETT. No difficulties were stated during the laparoscopic procedure. The patient was extubated without problems and her postoperative course was uneventful.

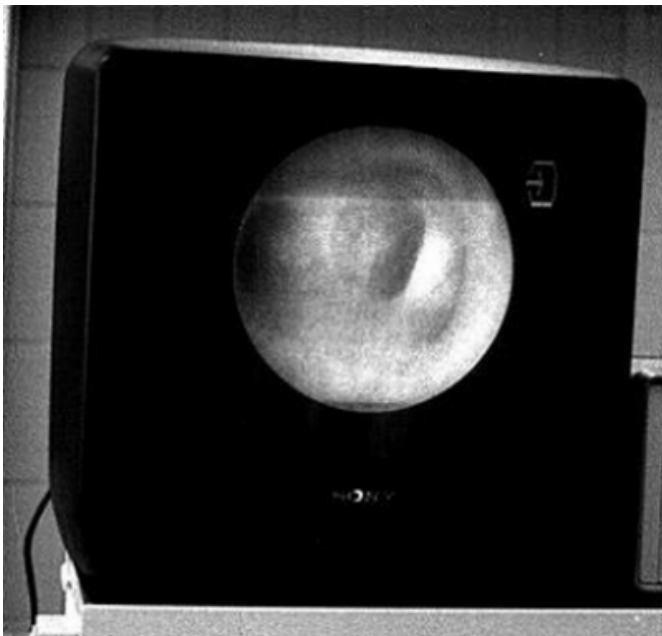
Figure 1

Figure 1: The video view from the tip of the video-optical intubation stylet reveals a right-sided tracheal bronchus near the carina



Figure 2

Figure 2: Monitor view of the right-sided tracheal bronchus, transmitted from the tip of the video-optical intubation stylet during conventional tracheal intubation



DISCUSSION

Subglottic airway abnormalities, such as webs, stenosis, tracheal bronchi, compressions or tumors are rare but have been reported to cause serious difficulties with tracheal intubation. ^{4,5,6}

A tracheal bronchus is an aberrant (=displaced) or an accessory (=supernumery) bronchus mostly arising from the right lateral wall of the trachea.⁷ The incidence is reported to be 0.1 - 3 %.^{7,8,9} A tracheal bronchus can be associated with other anomalies and respiratory morbidity in the childhood, but it is usually asymptomatic and may remain unknown.^{9,10} In such patients the endotracheal tube can obstruct an ectopic bronchus followed by hypoxemia and pulmonary atelectasis. The ETT can also migrate into a tracheal bronchus, causing profound hypoxemia and hyperinflation of the corresponding lobe with the risk of barotrauma. ^{6,11,12,13}

The visualized endotracheal tube (VETT) or the video-optical intubation stylet allow to monitor the subglottic airway in an simple and comfortable manner without jeopardizing the standard intubation procedure. In our patient video-controlled tracheal intubation helped to detect the tracheal bronchus already during intubation and to place the ETT safely above the tracheal bronchus preventing adverse respiratory events. With this technique subglottic airway abnormalities such as laryngeal or tracheal stenosis and obstructions are also identified during intubation and airway management can be changed according the subglottic findings. This helps to avoid airway trauma with bleeding and swelling and to order postoperative diagnostic procedure. Upon this, subglottic video-airway imaging is also a beneficial method to confirm final tracheal tube placement.

CONCLUSIONS

Subglottic video-airway imaging allows to recognize subglottic anomalies during intubation and helps to adapt airway management to the underlying disease. Furthermore, endobronchial and esophageal malpositioned tracheal tubes, two not uncommon problems in anaesthesia, are also immediately detected with this technique.

Video-monitoring of the endotracheal tube tip is a simple and useful method to visualize the subglottic airway during routine tracheal intubation and may help reducing morbidity and mortality associated with tracheal intubation.

References

1. Frass M, Kofler J, Thalhammer F et al Clinical evaluation of a new visualized endotracheal tube (VETT). *Anesthesiology* 1997;87:1262-1263.
2. Weiss M Video-Intuboscopy - An new aid for routine and difficult tracheal Intubation. *British Journal of Anaesthesia* 1998;80:525-528.
3. Weiss M Management of difficult tracheal intubation with a video-optically modified Schroeder intubation stylet.

- Anesthesia Analgesia 1997;85:1181-1182.
4. Ching ZK, Jawan B, Poon YY, Lee JH Unsuspected difficult intubation caused by a laryngeal web. British Journal of Anaesthesia 1997;79:396-397.
 5. Saito S, Dohi S, Tajia K Failure of double-lumen tube placement: Congenital tracheal stenosis in an adult. Anesthesiology 1987;66:83-85.
 6. Vredevoe LA, Brechner TH, Moy P Obstruction of anomalous tracheal bronchus with endotracheal intubation. Anesthesiology 1981;55:581-583.
 7. Mc Laughlin FJ, Strieder DJ, Harris GBC, Vawter GP, Eraklis AJ Tracheal bronchus : Association with respiratory morbidity in childhood. Journal of Pediatrics 1985;106:751-755.
 8. Le Roux NT Anatomical abnormalities of the right upper bronchus. Journal of Thoracic and Cardiovascular Surgery 1962;44:255-227.
 9. Inada K, Kishimoto S An anomalous tracheal bronchus to the right upper lobe. Diseases of the Chest 1957;31:109-112.
 10. Siegel Mj, Shackeford GD, Francis RS Tracheal bronchus. Radiology 1979;130:353-355.
 11. Tomoda M, Ueda W, Hasegawa T, Hirakawa M Troubled endotracheal intubation : An adult case of anomalous tracheal bronchus. Masui 1992;41:984-987.
 12. Pribble CG, Dean JM An unusual cause of intraoperative hypoxemia. Journal of Clinical Anesthesia 1994;6:247-249.
 13. Venkateswarlu T, Turner CJ, Carter JD, Morrow DH The tracheal bronchus. An unusual airway problem. Anesthesia Analgesia 1976;55:746-747.

Author Information

M. Weiss, M.D.

Department of Anaesthesia, University Children's Hospital

C. Villiger, M.D.

Department of Anaesthesia, University Children's Hospital