

Warfarin Induced Intra Alveolar Hemorrhage: A Case Report

S Mogili, M Krishnamurthy, Z Alkhoury, J Lyons

Citation

S Mogili, M Krishnamurthy, Z Alkhoury, J Lyons. *Warfarin Induced Intra Alveolar Hemorrhage: A Case Report*. The Internet Journal of Internal Medicine. 2009 Volume 8 Number 2.

Abstract

A 29-year-old female presented with facial cellulitis. Past medical history includes DVT of the right upper extremity secondary to PICC line for which she was receiving coumadin. Physical exam was notable for facial pustular cellulitis and she showed good response with IV Vancomycin but subsequently developed progressively worsening dyspnea with hypoxia. Auscultation of chest revealed bilateral scattered crackles with poor bilateral air entry. CXR showed bilateral interstitial markings of the lungs, with a diffuse nodular pattern. The labs revealed drop in Hct and INR of 6.95. CT angiogram showed diffuse ill-defined interstitial opacities with nodular appearance. Bronchoalveolar lavage revealed bloody aliquots consistent with DAH secondary to supratherapeutic INR. Coumadin was discontinued and steroids were administered for a potential capillaritis and the patient responded well. This case highlights a relatively unusual presentation of DAH due to supratherapeutic INR, which was likely precipitated by concurrent warfarin therapy and antibiotic administration.

INTRODUCTION

Diffuse alveolar hemorrhage (DAH) refers to a clinical syndrome resulting from injury to the alveolar capillaries, arterioles, and venules leading to red blood cell accumulation in the distal air spaces¹. It often presents with a clinical triad of hemoptysis, anemia and diffuse alveolar consolidation⁴. It is caused by diseases that damage the alveolar capillary barrier or by disorders of coagulation⁴. Only a small number of reports cite the occurrence of pulmonary hemorrhage in patients treated with coumadin, warfarin, or heparin³. Diffuse alveolar hemorrhage complicating warfarin therapy is associated with a high mortality rate².

CASE PRESENTATION

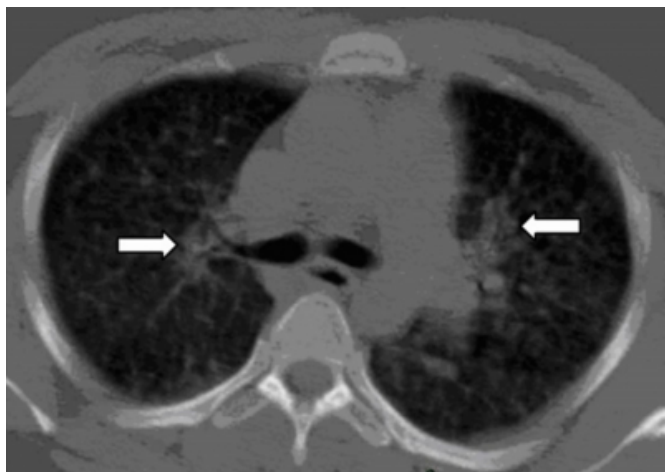
A 29-year-old female presented with facial cellulitis for 2 days. Past medical history includes MRSA skin infections and DVT of the right upper extremity secondary to PICC line for which she was receiving coumadin. Social history includes tobacco abuse and occasional alcohol intake. Physical exam was normal except for facial pustular cellulitis. She was started on IV Vancomycin and showed good response in couple of days, but subsequently started having dyspnea, which was progressively worsening with hypoxia. Auscultation of chest revealed bilateral scattered crackles with poor bilateral air entry. CXR showed bilateral

interstitial markings of the lungs, with a diffuse nodular pattern.

The labs revealed drop in Hct from 30.2 to 27.9 and INR of 6.95. CT angiogram showed diffuse ill-defined interstitial opacities with nodular appearance (see Figure1). Patient was transferred to Intensive Care Unit for worsening hypoxia. Bronchoalveolar lavage revealed bloody aliquots consistent with DAH. The most likely etiology was considered to be secondary to supratherapeutic INR, which was precipitated by concurrent antibiotic administration, as all the other workup was negative. Coumadin was discontinued and IV steroids were administered followed by oral steroids for a potential capillaritis. The patient showed good response over subsequent 2-3 days and was discharged home in stable condition.

Figure 1

Fig1: CT scan of chest showing numerous, small ill-defined interstitial opacities.



DISCUSSION

Diffuse alveolar hemorrhage can be associated with or without systemic findings. Certain conditions that are associated with systemic findings include, Henonch-Scholein purpura, cryoglobulinemic vasculitis, exposure to toxic agents such as insecticides and pesticides, connective tissue diseases, and use of offending drugs such as anticoagulants, D-pencillamine, nitrofurantoin, amiodarone, propylthiouracil, or cocaine⁵. Hemorrhage with no associated systemic findings should be considered in conditions such as antglomerular basement membrane antibody disease, microscopic polyangiitis, and idiopathic pulmonary hemosiderosis⁵. Corticosteroids and immunosuppressive agents remain the main standard of treatment for capillaritis and vasculitis. Removal or avoidance of the offending

drug/toxin is the standard for medication/toxin-induced hemorrhage.

There have been prior cases reported about catastrophic alveolar hemorrhage due to supratherapeutic INR's (prothrombin time of 480 seconds)², but in this case we find that a mild to moderate supratherapeutic INR can also cause diffuse alveolar hemorrhage requiring intensive care monitoring. This case highlights a relatively unusual presentation of diffuse alveolar hemorrhage due to a supratherapeutic INR. This was likely precipitated by concurrent warfarin therapy and antibiotic administration. Given the number of patients requiring anticoagulant therapy, vigilance should always be maintained to monitor INR's when antibiotics are administered so as to prevent bleeding complications as seen in this case.

References

1. Amy L. Olson, Marvin I. Schwarz: Diffuse Alveolar Hemorrhage; *Prog Respir Res. Basel, Karger, 2007, vol 36, pp 250–263*
2. JK Thomas, K Jayaprakash, KJR Misiriya, SA Khadar, JM Pappachan: Catastrophic Pulmonary Alveolar Hemorrhage Complicating Warfarin Therapy; *Journal of Association of Physicians of India ISSN 0004 5772 2008, vol. 56, noJAN, pp. 34-34 [1 page(s) (article)]*
3. Anthony Papagiannis, MD; A. Peter Smith, MD; and Mark W. Hebden, MD: Acute Dyspnea, Chest Tightness, and Anemia in a 33-Year-Old Man; *Chest 1995; 107; 863-865 DOI 10.1378/chest.107.3.863*
4. V T Barnett, F Bergmann, H Humphrey and J Chediak: Diffuse alveolar hemorrhage secondary to superwarfarin ingestion; *Chest 1992; 102; 1301-1302 DOI 10.1378/chest.102.4.1301*
5. Octavian C. Ioachimescu, James K. Stoller: Diffuse Alveolar Hemorrhage: Diagnosing it and finding the cause; *Cleveland clinic journal of medicine, 2008, vol 75, pp 258-279.*

Author Information

Sujatha Mogili, MD

Resident, Department of Internal medicine, Unity Hospital

Mahesh Krishnamurthy, MD

Resident, Department of Internal medicine, Unity Hospital

Ziad A. Alkhoury, MD

Hospitalist, Unity Hospital

Jason J. Lyons, MD

Critical Care / Pulmonology Physician, Unity Hospital