

# Digital Pseudotumor associated with Von Willebrand Disease

M Mathew, G Goel, A Kurien

## Citation

M Mathew, G Goel, A Kurien. *Digital Pseudotumor associated with Von Willebrand Disease*. The Internet Journal of Hematology. 2008 Volume 5 Number 2.

## Abstract

Hemophilic pseudotumor is a term used to describe a progressive, encapsulated, slowly expanding, cystic mass occurring as a result of recurrent hemorrhage, usually in soft tissues but occasionally in bone or subperiosteal location. It is an uncommon but serious complication of bleeding diathesis occurring in only 1 - 2% cases and has mostly been reported in severe factor VIII and IX deficiency. We describe a rare case of hemophilic pseudotumour of the left 5<sup>th</sup> metacarpal bone in a 13 year old male child diagnosed with von Willebrand disease.

## INTRODUCTION

Von Willebrand disease (vWD) is a congenital bleeding disorder with autosomal dominant inheritance. It is characterized by a qualitative and quantitative deficiency of von Willebrand factor along with a deficient factor VIII coagulant activity in the plasma.<sup>1</sup> Patients present with frequent and severe hemorrhagic manifestations depending on the severity of defect. Development of pseudotumor is a known complication of hemophilia but has been rarely reported with vWD.<sup>2</sup> It consists of chronically encapsulated enlarging hematoma due to recurrent extra-articular hemorrhage, leading to slow destruction of adjacent structures.<sup>3</sup> It commonly affects the pelvis and long bones of lower limbs and rarely other sites like mandible, maxilla, nasal bones, tibia, radius, humerus, orbit, cranium or small bones.<sup>4,5</sup> In this report, we present a unique case of hemophilic pseudotumour of the left 5<sup>th</sup> metacarpal bone in a patient with von Willebrand disease.

## CASE REPORT

A 13 year old boy, diagnosed to have von Willebrand disease, presented to the pediatric department with a gradually progressive, painful, globular swelling extending from dorsal to palmar aspect of the left hand measuring 6x10cms since 6 years. It was firm in consistency, with well defined margins, smooth surface, non-pulsatile and tender. The child also complained of intermittent episodes of epistaxis and gum bleeds. He had a prolonged bleeding time and activated partial thromboplastin time, other coagulation tests being normal. Factor VIII activity was 3.5% and von

Willebrand factor assay showed an activity of 4.5%.

Radiographic evaluation of the swelling showed a large expansile lytic lesion involving the diaphysis and metaphysis of the 5<sup>th</sup> metacarpal bone. The cortex was thinned out with evidence of internal trabeculations in the lesion. The lesion was seen abutting the medial aspect of the 4<sup>th</sup> metacarpal bone with thinning of the shaft. An amputation of the 5<sup>th</sup> finger was performed as it had become a useless and dangerous appendage due to progression in size of the lesion. All the three male siblings of the patient had similar history of bleeding diathesis.

## PATHOLOGICAL FINDINGS

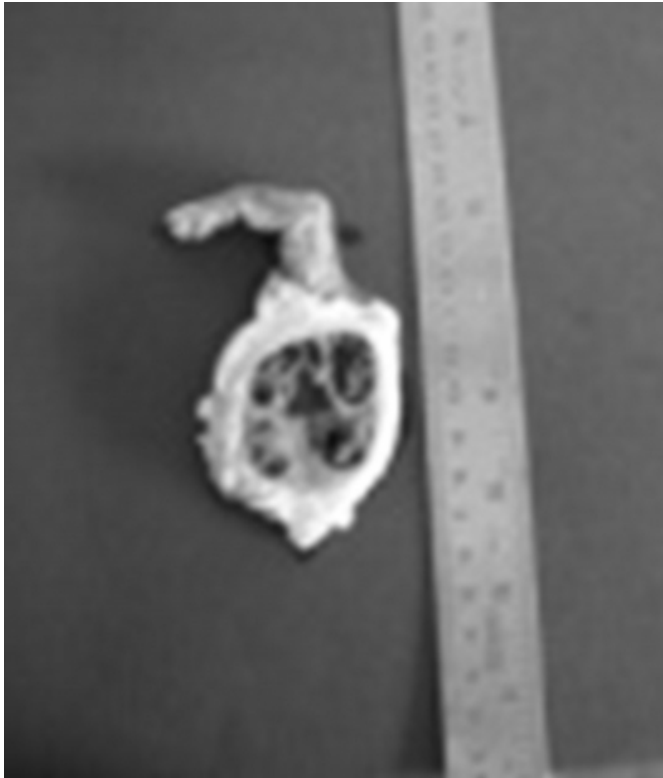
A specimen of atrophied little finger with 5<sup>th</sup> metacarpal bone and a large globular mass at the base weighing 89gms and measuring 13x5x4cms was received. On cut section an encapsulated globular mass with intramuscular hemorrhage measuring 4.5x5.5cms was seen. (Fig 1)

Microscopic examination showed multiple blood filled cysts separated by fibrous tissue and lined by an inner layer of hemosiderin and hemosiderin laden macrophages, a middle fibrous layer and an outer reticular zone containing blood vessels and elastic tissue. Fragments of bone rimmed by osteoblasts, calcific debris, thrombi in various stages of organization and areas of new bone formation admixed with areas of bone destruction were seen. (Fig 2)

A histopathological diagnosis of a hemophilic pseudotumor of the 5<sup>th</sup> metacarpal bone was made.

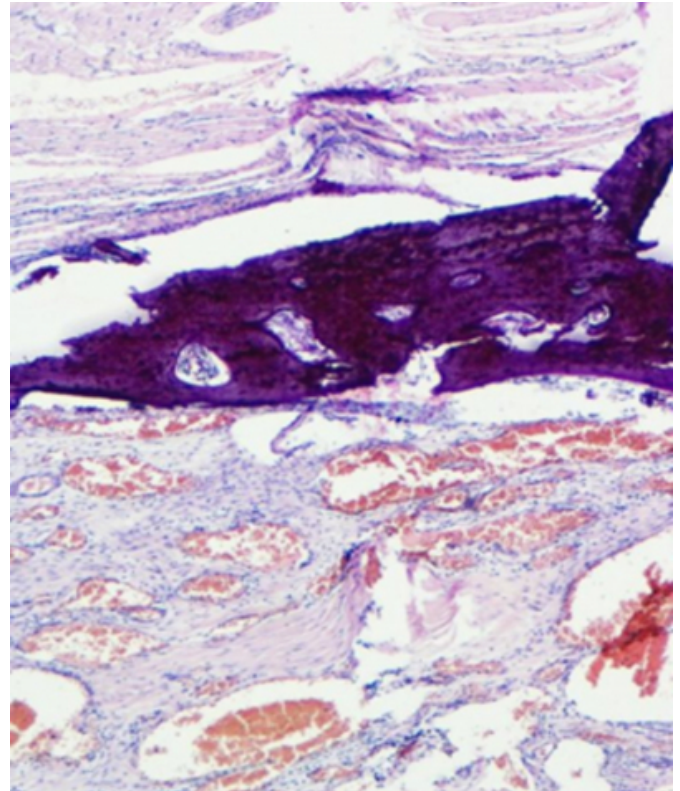
**Figure 1**

Figure 1: Amputated little finger with the 5 metacarpal bone showing pseudotumor



**Figure 2**

Figure 2: Multiple blood filled cysts separated by fibrous tissue



## DISCUSSION

Von Willebrand disease is the most common inherited bleeding disorder. Pseudotumor is an infrequent manifestation of bleeding diathesis, seen only in 1-2% hemophiliacs with severe disease and rarely in a patient with vWD. This entity was first described by Starker in 1918 in a 14 year old hemophilic boy.<sup>6</sup> Pseudotumor is a term used to describe a progressive cystic tumor-like mass involving the extra-articular musculoskeletal system, produced by recurrent hemorrhage and accompanied by radiographic evidence of bone involvement.<sup>7</sup> This is differentiated from hemophilic cysts which are confined to the muscle and not associated with changes in the bone.<sup>6</sup> The mechanism of formation of pseudotumor starts as a subperiosteal hemorrhage with stripping of the periosteum from the cortex until this is limited by aponeurotic and tendinous attachment, which then raises or destroys the muscle.<sup>6</sup>

The etiology of pseudotumors is not very well known but various authors have attributed it to intraosseous bleeding with pressure necrosis of bone or to bleeding into large muscles in areas with rich periosteal blood supply to the bone.<sup>8</sup> Two types of pseudotumors have been described, a proximal type occurring in long bones and a distal type

confined to small joints of hands and feet. The distal type is more common in children whereas the proximal type occurs in adults.<sup>3</sup>

Radiographic evaluation by CT scan and MRI is useful in determining the extent, diagnosis and differentiation of pseudotumor from other conditions and determination of management and follow up assessment. The radiographic findings vary with the extent, location and different stages of hemorrhage in the pseudotumor.<sup>9</sup> Pseudotumors on radiography are well defined, osteolytic, expansile lesions showing medullary bone destruction, cortical thinning or thickening and peripheral sclerosis. Internal calcifications or ossifications and subperiosteal bone formation may be seen focally in soft tissue pseudotumors.<sup>9,10</sup> Radiologically pseudotumor may mimic Ewing's sarcoma, aneurysmal bone cysts, giant cell tumor, malignant fibrous histiocytoma, neurofibroma and certain malignant neoplasms like osteosarcoma.<sup>3</sup> However, a pseudotumor is histologically distinct from these entities. On microscopy, it shows a cyst wall composed of various layers of fibrous tissue, an inner layer containing hemosiderin, a middle fibrous layer and an outer reticular zone containing large vessels and elastic tissue.<sup>6</sup>

The management of pseudotumor is aimed at preserving the function. Most of the cases are satisfactorily managed by conservative therapy with immobilization and clotting factor prophylaxis. Surgical intervention is done for cases with skeletal, neurological or organ damage.<sup>2</sup>

## CONCLUSION

Several cases of hemophilic pseudotumor have been reported in literature since 1918, but with the advent of newer treatment modalities, these lesions are becoming a rarity. However, one still encounters an infrequent case which can pose a diagnostic difficulty due to its ominous radiological presentation.

## References

1. Ozhan SAM, Isik S, Oznur II, Atilla S, Kemaloglu Y. Pseudotumor of the maxillary sinus in a patient with von Willebrand's disease. *AJR* 1996; 166: 950-951.
2. Eby CS, Caracioni AA, Badar S, Joist JH. Massive retroperitoneal pseudotumor in a patient with type 3 von Willebrand Disease. *Hemophilia* 2002; 8: 136-141.
3. Kapoor R, Sastri J, Malhotra P, Kumar V, Singh P. Hemophilic pseudotumor: Is there a role of radiotherapy? A case report with review of literature. *Turk J Hematol* 2006; 23: 53-58.
4. Gupta AD, Bose A, Mahalanabis D. Haemophilic pseudotumour involving the right second metacarpal bone in a 5-year-old boy, treated by ray amputation. *Hemophilia* 2004; 10: 408-409.
5. Inoue T, Suzuki Y, Nishimura S, Murakami K, Nishijima M. Cranial hemophilic pseudotumor associated with factor IX deficiency: Case Report. *Surg Neuro* 2008; 69: 647-51.
6. De Valderrama F, Spain M, Matthews JM. The hemophilic pseudotumor or hemophilic subperiosteal hematoma. *J Bone Joint Surg Br* 1965; 47: 256-65.
7. Ahlberg AK. On the natural history of hemophilic pseudotumor. *J Bone Joint Surg Am.* 1975; 57: 1133-36.
8. Shaheen S, Alasha E. Hemophilic pseudotumor of the distal parts of radius and ulna. A case report. *J Bone Joint Surg Am.* 2005; 87: 2546-49.
9. Park JS, Ryu KN. Hemophilic Pseudotumor Involving the Musculoskeletal System: Spectrum of Radiologic Findings. *AJR.* 2004; 183: 55-61.
10. Stafford JM, James TT, Allen AM, Dixon LR. Hemophilic Pseudotumor: Radiologic-Pathologic Correlation. *Radiographics* 2003; 23: 852-56.

**Author Information**

**Mary Mathew, MD**

Department of Pathology, KMC

**Garima Goel, MD**

Department of Pathology, KMC

**Anamma Kurien, MD**

Department of Pathology, KMC