

Identical Abnormal Electrocardiograms In Monozygotic Twins

T Grandhi, K Willmer

Citation

T Grandhi, K Willmer. *Identical Abnormal Electrocardiograms In Monozygotic Twins*. The Internet Journal of Cardiology. 2003 Volume 2 Number 2.

Abstract

Abnormal electrocardiogram in normal people or in patients with non-cardiac chest pain is rare, but recognised entity. We report a case of abnormal electrocardiogram showing ischaemic changes in a patient with musculoskeletal chest pain. We have reviewed the literature, causes of abnormal ECG and method of separation of physiological from pathological ECG in twins discussed.

WORK DONE AT

Department of Cardiology
Russell's Hall Hospital
Dudley
West Midlands DY1 2HQ
United Kingdom

INTRODUCTION

Abnormal resting electrocardiogram in asymptomatic people or in patients with non-cardiac chest pain is a recognised entity. Comparing the electrocardiograms in twins can be helpful in separating physiological from pathological ECG. We report a case of abnormal ECG in a patient with non-cardiac chest pain, which was initially thought to be of ischaemic origin.

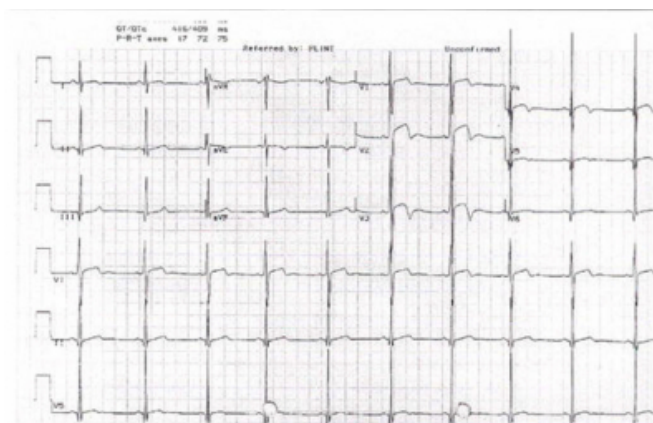
CASE REPORT

A 21-year-old male mechanic presented to the Accident & Emergency Department at Russell's Hall Hospital on an early morning with chest pain of 1-hour duration and a feeling of being generally unwell. He woke up from sleep with severe pain in his central chest, which was spasmodic and constricting in nature, with no definite pattern of radiation. He was noted to have worked out at the gym the previous day. He denied any other cardiovascular or respiratory symptoms or a recent viral illness. His past medical history did not reveal any risk factors for ischaemic heart disease. He denied any therapeutic or recreational drug use. He was one of monozygotic twins. His father has hypertension. He was an occasional smoker and drinks moderate amount of alcohol at weekends.

The pain started to ease off by the time he attended Accident & Emergency. On arrival, he was haemodynamically stable with normal pulse and blood pressure. His oxygen saturation was 99%. Systemic examination was normal. His electrocardiogram on arrival showed ST elevation in leads V₂ and V₃, T-wave inversion in leads V₁ to V₃, tall R wave in V₄ to V₆ and deep S wave in V₂ and V₃ (figure 1). After one hour this pattern was unchanged. He was admitted with a provisional diagnosis of ischemic chest pain secondary to Hypertrophic Obstructive Cardiomyopathy or Pericarditis.

Figure 1

Figure 1: Electrocardiogram of the patient



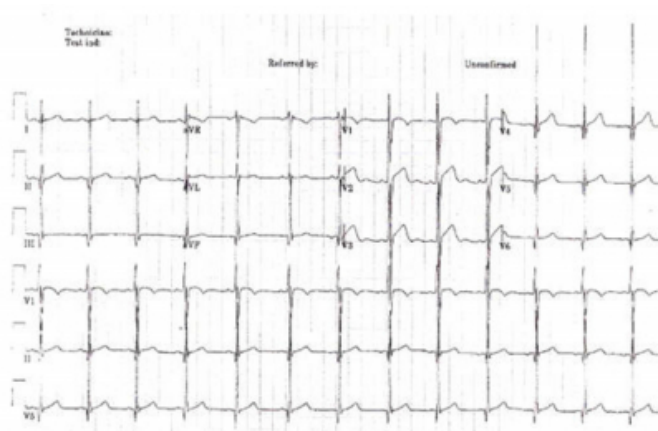Blood tests at admission revealed elevated cardiac enzymes. His CK was 278, CKMB 14, AST 82 and LDH 433. He developed a further episode of chest pain in the ward. He had an emergency echocardiogram that was reported as showing septal hypokinesia and no evidence of left ventricular hypertrophy. On the basis of tight, central chest

pain, an abnormal ECG with ST elevation, elevated cardiac enzymes and his echocardiographic findings he was thrombolysed with reteplase and was started on beta-blockers and heparin. Blood tests from a second specimen, taken 6 hours after the first, revealed a further rise in his cardiac enzymes. His CK at 6 hours was 1596, CKMB 50, AST 157 and LDH 809. He had a further episode of chest pain the following day. The chest pain settled over two to three days with symptomatic treatment. The ECG changes remained unchanged despite treatment. Subsequent review of the echocardiogram by the consultant cardiologist showed it to be normal.

In view of the persistent ECG changes an ECG of his twin was performed which revealed similar changes of early repolarisation (figure 2). It was therefore concluded that his pain was probably musculoskeletal in origin as were his enzyme changes due to working out at the gym the day prior to admission, and that his ECG changes were a normal variant. He was discharged home on Aspirin. He was asymptomatic at follow up.

Figure 2

Figure 2: Electrocardiogram of the twin brother



DISCUSSION

It was concluded that the ECG was a normal variant in view of the similar ECG changes in both the twins. Similar abnormal ECG changes in asymptomatic twins have only been reported once in the literature [1]. Both the twins had abnormal identical resting electrocardiograms, which is recognised and may be of genetic origin. The ECG of an individual is rather akin to the fingerprint - each individual has a unique ECG (usually why misfiled ECGs are detected). However 50% of monozygotic and 22% of dizygotic twins have been shown to have identical electrocardiograms in previous studies [2, 3]. This may be due to hereditary hypersensitivity of beta-receptors of the myocardium and can usually be detected by change in the ECG on administration of beta-blocker. In cases of twins a paired ECG between twins can be valuable in separating pathological from physiological changes under these circumstances.

CORRESPONDENCE TO

Mr Tagore M Grandhi 59 Regency Avenue King's Lynn
Norfolk PE30 4UH United Kingdom Tel: +44 1553 775797
Fax: +44 1553 613466 E-mail: tmgrandhi@hotmail.com

References

1. Maccarini PA. An unusual ECG pattern in two healthy identical twins. *Acta. Genet. Med. Gemellol* 1975; 24: 173
2. Ferrer MI. Identity and the electrocardiogram, with a note on twins and altered identities. *The Am. J of Cardiology* 1983; 51: 1784-5
3. Perez GL, Keith L. Electrocardiograms of twins. *Proc Clin Biol Res* 1978; 24: 39-47

Author Information

Tagore M. Grandhi, FRCS

Staff Grade (General Surgery), Queen Elizabeth Hospital, King's Lynn

Kate A. Willmer, MRCP

Consultant Cardiologist, West Cumberland Hospital