

Autolobectomy in Swyer-James (Mcleod's) Syndrome: Value of Preoperative V/Q Scan

T Ones, F Dede, T Lac?n, B Cal?skan, S Inan?r, T Erd?l, H Turoglu

Citation

T Ones, F Dede, T Lac?n, B Cal?skan, S Inan?r, T Erd?l, H Turoglu. *Autolobectomy in Swyer-James (Mcleod's) Syndrome: Value of Preoperative V/Q Scan*. The Internet Journal of Nuclear Medicine. 2007 Volume 5 Number 1.

Abstract

Swyer James (Mcleod's) syndrome (SJMS) is an uncommon disease and asymptomatic patients may not be diagnosed until later in life. A 34-year-old man with SJMS is presented in this case report. V/Q scan showed markedly diminished perfusion and ventilation in the left upper lobe which was like a surgically resected lobe (autolobectomy). This case report underlines the V/Q scan findings potentially may lead the surgeons for choosing the best surgical treatment plan.

INTRODUCTION

Swyer James (Mcleod's) syndrome (SJMS) is a rare complication of respiratory tract infections occurring in early childhood^{1,2}. Initially this syndrome was thought to be congenital in origin and was attributed to hypoplasia of the pulmonary artery. This theory, however, was later disproved because the number of bronchial generations and vascular branches in these patients were normal³.

In this syndrome, one lung, one or more lobes of the lung, or one or more segments in a lobe of one hemithorax, are found to be abnormally radiolucent without the usual pulmonary markings with bronchial deformation and the lung fields do not empty on expiration⁴.

CASE REPORT

A 34-year-old man was admitted to our hospital with dyspnea and chest pain. The patient had a history of multiple left sided respiratory infections in childhood. The previous CXR which was obtained in the late childhood (Fig.1A) demonstrates shift of the mediastinum, trachea and heart towards the right side and a dense opacity involving the entire upper lobe of the left lung.

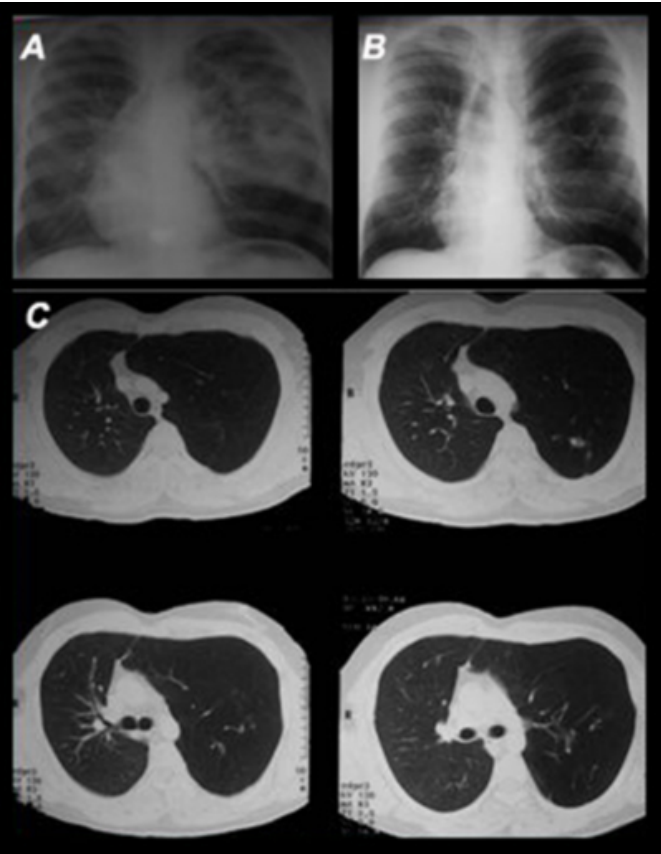
Chest examination showed diminished breath sounds over the left hemithorax. A CXR obtained on admission (Fig.1B) showed shift of the mediastinum, trachea and heart towards the right side. The upper side of the left lung was hyperlucent and showed a marked diminution in the vascular markings.

A high-resolution computed tomographic scan (HR-CT)

with contrast (Fig.1C) revealed loss of normal anteroposterior attenuation gradient and marked air-trapping at the left upper side with a reduced vascularity.

Figure 1

Figure 1: CXR's demonstrates shift of the mediastinum, trachea and heart towards the right side. Previous CXR (A) shows a dense opacity throughout the upper lobe of the left lung and new CXR (B) shows hyperlucency involving the upper side of the left lung. HR-CT of the chest (C) with contrast depicting loss of normal anteroposterior attenuation gradient and marked air-trapping at the left upper side with a reduced vascularity.

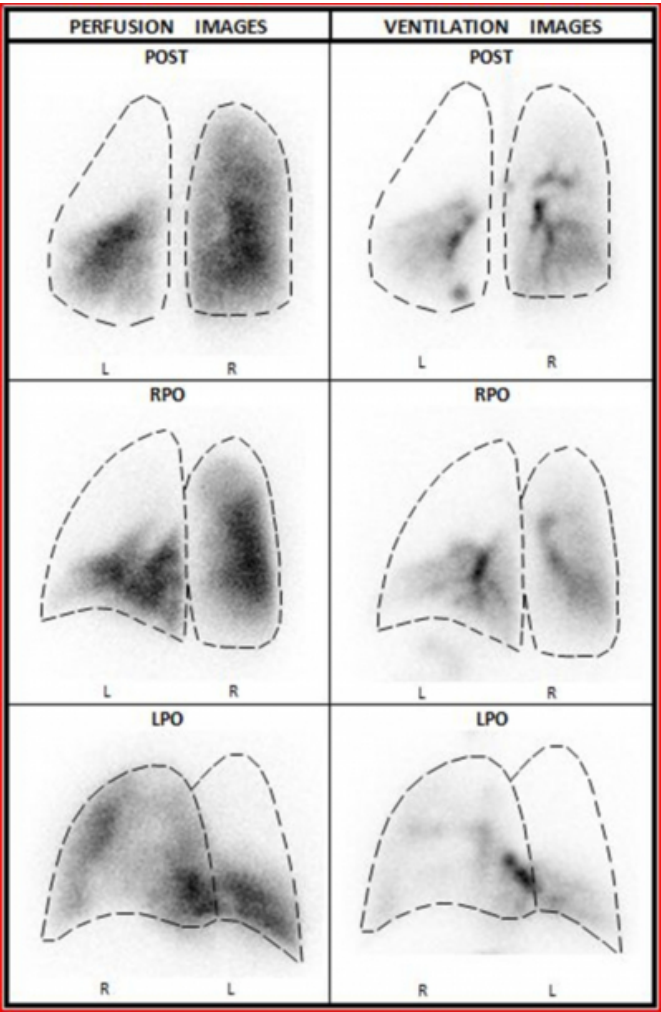


Fiberoptic bronchoscopy was revealed no obstructing lesions and the number of major bronchi on the left was normal.

Ventilation/perfusion imaging was showed markedly diminished perfusion and ventilation in the left upper lobe (Fig.2).

Figure 2

Figure 2: Posterior, right posterior oblique (RPO) and left posterior oblique (LPO) V/Q images shows markedly diminished perfusion and ventilation in the left upper lobe.



These findings are consistent with those of unilateral lobar SJMS and a left upper lobectomy was performed without complication. The follow-up visit at 3rd months showed no dyspnea and no chest pain.

DISCUSSION

The SJMS is usually asymptomatic and generally diagnosed by chest radiography (CXR) in a child with respiratory symptoms. However, CXR can be insensitive and may appear normal and may therefore, underestimate the prevalence of this condition⁵. The bronchial damage may develop as a complication due to the repeated episodes of lower respiratory tract infections, resulting in bronchiolitis obliterans⁶⁷⁸. Small airways obstruction, alveolar over distension and the characteristic destructive changes of emphysema during childhood is considered a very important factor in the pathogenesis of this syndrome⁶⁷⁸.

The SJMS should be differentiated from the other causes of unilateral hyperlucency on CXR, such as those related to congenital bronchial and/or vascular abnormalities. CT can be used in the differential diagnosis of SJMS and therefore help to rule out foreign bodies in children and endobronchial tumors in adults₆. CT can also help to exclude pulmonary artery agenesis and other syndromes associated with a small or hypoattenuated lung₆.

Pulmonary angiography can confirm hypoplasia of the main pulmonary artery and branches in the corresponding areas but is not necessary for the diagnosis (like flexible fiberoptic bronchoscopy) if the CT and V/Q scan findings are typical for the SJMS₃.

The V/Q scan is an important modality in the diagnosis of the SJMS. The unexpected regions of bronchiolitis in the contralateral lung and bilateral involvement were demonstrated with only the V/Q scan compared with CXR and CT in a case report₆.

Most of SJMS patients have unilateral affected lungs. SJMS is rarely seen in one lobe of the lung rather than unilateral total involvement and there is no other case report with an previous CXR which was obtained in the late childhood as with our patient. The previous CXR showed no evidence of hyperlucency involving the entire upper lobe of the left lung suggestive of congenital lobar emphysema which should be considered in the differential diagnosis of SJMS. The dense opacity involving the left upper lobe was interpreted as associated with of an infectious disease. This finding also supports the bronchial damage theory for the pathogenesis of

SJMS with infective bronchitis and bronchiolitis leading to obliteration of small airways. The V/Q scan in our patient, showed markedly diminished perfusion and ventilation in the left upper lobe which was like a surgically resected lobe (autolobectomy) and this demonstrating key finding led the surgeons for left upper lobectomy instead of pneumonectomy.

This case report underlines the importance of the V/Q scan as a quick and easily noninvasive diagnostic tool that seems to be necessary and complementary with the anatomical imaging modalities in detecting the affected lung regions. The V/Q scan findings potentially may lead the surgeons for choosing the best surgical treatment plan.

References

1. Swyer PR, James GCW. A case of unilateral pulmonary emphysema. *Thorax* 1953;8:133-6.
2. McLeod WM. Abnormal transradiancy of one lung. *Thorax* 1954;9:147-53.
3. Mathur S, Gupta SK, Sarda M, Jaipal U. Swyer-James-McLeod syndrome with emphysematous bulla. *J Indian Med Assoc* 1995;93:150-4.
4. Salmanzadeh A, Pomeranz SJ, Ramsingh PS. Ventilation-perfusion scintigraphic correlation with multimodality imaging in a proven case of Swyer-James (Macleod's) syndrome. *Clin Nucl Med* 1997;22:115-8.
5. McKinney LA, Mathai MG, Byrd RP, Roy TM. An unusual presentation of a rare disorder: Swyer-James-Macleod's Syndrome. *Clin Pulm Med* 2002;9(2):105-8.
6. Erkasar CF, Caglar CE, Koray D, Ilgin KN. Bilateral Swyer-James (Macleod's) syndrome. *Indian J Pediatr* 2002;69:433-5.
7. Penn CC, Liu C. Bronchiolitis following infection in adults and children. *Clin Chest Med* 1993; 14: 645-54.
8. Lucaya J, Gartner S, Garcia-Pena P, Cobos N, Roca I, Linan S. Spectrum of manifestations of Swyer-James Macleod syndrome. *J Comput Assist Tomogr* 1998; 22: 592-7.

Author Information

Tunc Ones, MD

Instructor, Department of Nuclear Medicine, Marmara University School of Medicine, Istanbul, Turkey

Fuat Dede, MD

Department of Nuclear Medicine, Marmara University School of Medicine, Istanbul, Turkey

Tunc Lacn, MD

Department of Chest Surgery, Fatih Sultan Mehmet Training and Research Hospital, Istanbul, Turkey

Billur Calskan, MD

Department of Nuclear Medicine, Diyarbakir State Hospital, Diyarbakir, Turkey

Sabahat Inanr, MD

Professor, Department of Nuclear Medicine, Marmara University School of Medicine, Istanbul, Turkey

T. Yusuf Erdl, MD

Professor, Department of Nuclear Medicine, Marmara University School of Medicine, Istanbul, Turkey

H. Turgut Turoglu, MD, M.Sc.

Professor, Department of Nuclear Medicine, Marmara University School of Medicine, Istanbul, Turkey