

Epithelioid Angiomyolipoma: A Rare Variant Of Renal Angiomyolipoma

J Astigueta, M Abad, M Pow-Sang, C Morante, L Meza, V Destefano, J Montes, R Dyer

Citation

J Astigueta, M Abad, M Pow-Sang, C Morante, L Meza, V Destefano, J Montes, R Dyer. *Epithelioid Angiomyolipoma: A Rare Variant Of Renal Angiomyolipoma*. The Internet Journal of Urology. 2008 Volume 6 Number 1.

Abstract

Angiomyolipoma (AML) is a rare well-known soft tissue tumor involving the kidneys, liver and other organs. Despite the large size they can achieve, the possibility of bilaterality, the multiplicity of lesions and / or regional lymph involvement, and its malignant potential have not been demonstrated. However, in recent years an epithelioid variant has been described which is characterized by its aggressive behavior, difficult histological characterization and poor prognosis. We report a case of renal epithelioid angiomyolipoma (AMLE) in a 12-years-old male with stigmata of tuberous sclerosis (TSC). The tumor was composed of diffused sheets of epithelioid cells. Immunohistochemically, the cells were immunoreactive for HMB 45 and negative for cytokeratin.

INTRODUCTION

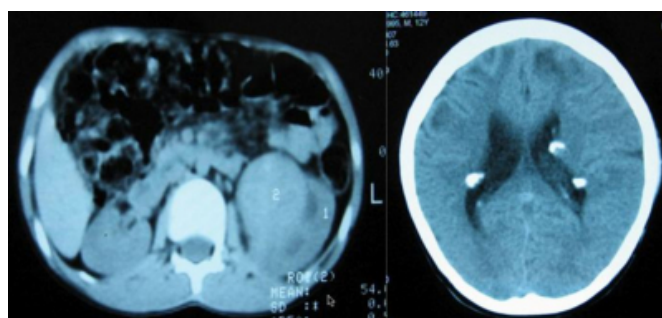
Angiomyolipoma (AML) of the kidney is a rare benign tumor, first described by Morgan in 1951.¹ Histologically it is classified as typical (triphasic), with three components: mature fatty tissue, blood vessels and smooth muscle; and atypical (monophasic or epithelioid).¹²³ The epithelioid angiomyolipoma (AMLE), recently separated from the rest of angiomyolipomas, is a atypical histological variant, with aggressive behavior; associated in more than half of the cases to Tuberous Sclerosis (TSC), with mutations in the p53 gene and a high rate of distant metastases.⁴⁵⁶⁷ We present the first case diagnosed in the institution.

CASE REPORT

A 12-years-old male patient with a history of delay in psychomotor development and tonic-clonic seizures treated with carbamazepine and phenytoin. Approximately 3 weeks before evaluation, the patient presented gross hematuria with clots and abdominal pain predominantly hypogastric. Computerized tomography of the abdomen and pelvis showed a 80 x 64 x 56 mm heterogeneous mass involving two-thirds of the upper left kidney, chest x-ray was normal and a brain computerized tomography showed a cortico-subcortical hypodense areas associated with multiple periventricular calcifications (Figure 1).

Figure 1

Figure 1: Contrast enhanced CT shows a mass heterogeneous that occupies the two-thirds of the upper left kidney and Axial contrast enhanced CT demonstrates multiple calcifications periventriculars.



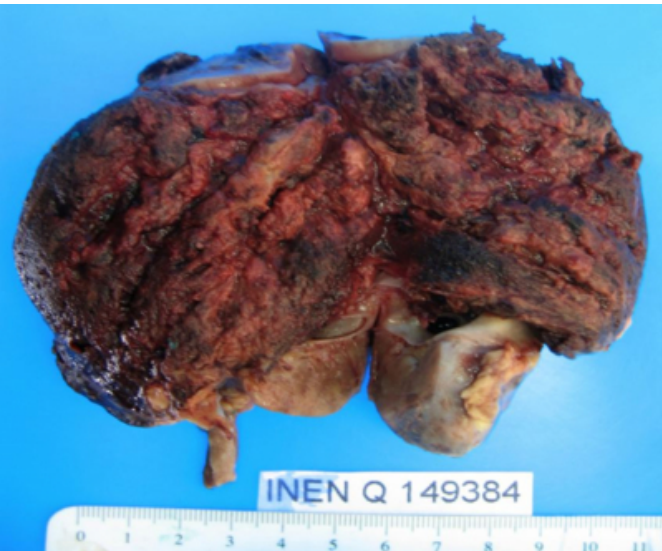At physical examination, the patient is awake but does not obey orders, with severe disturbance of higher brain functions without motor deficit. Examination of the fundus oculi did not reveal retinal lesions. At the face, nose, and nasogenian folds multiple erythematous papules up to 2 mm were present. At abdominal palpation a non-tender left flank tumor was present. Under the diagnosis of left kidney angiomyolipoma associated with tuberous sclerosis, the patient underwent a left radical nephrectomy and left para-aortic lymphadenectomy.

Macroscopically the specimen showed a 250 grams kidney, with a 8 x 7 x 2.3 cm brownish tumor replacing 90% of the

renal parenchyma. Hemorrhagic and necrotic tissue was identified, infiltrating and destroying the pyelocalicial system (Figure 2).

Figure 2

Figure 2: Macroscopic image. Note the hemorrhagic aspect of the tumor mass.



Microscopically there is an infiltrating tumor with irregular edges, consisting mainly of polygonal epithelioid cells with clear cytoplasm, interspersed with granular eosinophilic and multinucleated cytoplasm similar to the ganglion cells. These cells presented nuclear atypia, prominent nucleoli and mitosis (0-5 mitosis / 10 high power fields); also present areas of hemorrhage and necrosis. There were no vascular or perineural invasion. The ureter, perirenal fat and surgical margins were free of malignancy.

This hystomorphology was consistent with epithelioid angiomyolipoma (Figure 3), which was confirmed by immunohistochemical tests, whose results are presented in

Figure 3

Figure 3: Microscopic image: Cells polygonal of epithelioid aspect, and other multinucleated similar to the ganglion cells and Epithelioid AML with many HMB-45 positive cells.

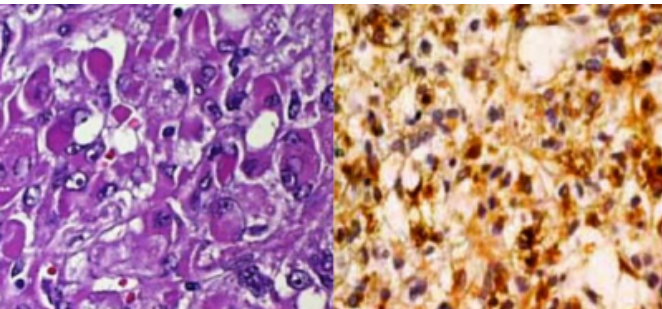


Figure 4

Table 1: Immunohistochemistry panel.

	HMB45	CD117	Vimentin	α Actin	Keratin
ANGIOMYOLIPOMA	+	+	+	-	-

DISCUSSION

Renal AML, also known as hamartoma, is a relatively rare benign tumor that appears in 0.3% of the general population and accounts for 3% of solid renal masses.¹⁸ It belongs to the family of lesions characterized by epithelioid perivascular proliferation cells and consists, in varying proportions, of three cell lines: mature fatty tissue, smooth muscle and irregular blood vessels.²⁴ Usually presents under two clinical forms: as a single large tumor in women of middle age, or associated with Bourneville disease or tuberous sclerosis, which is usually bilateral, multiple, and with the highest incidence in young men, representing between 15 and 20% of cases.¹⁸

Tuberous Sclerosis (TSC) is a hereditary disease whose diagnosis can be made at different stages of life. The infant starts with bending spasms, hipsiarrhythmia and hypomelanotic spots on the skin. In older children and adolescents, as our patient, they present with epilepsy, facial angiofibromas, and intracranial calcifications in the region of the ventricular walls. It also involves other organs such as kidneys, liver, brain, heart, eyes, lungs and bones. The association of AML and RCC is an unusual finding. Lane et al. reported 28 cases of coexistence of AML and RCC including ipsilateral (18), contralateral (6) and bilateral (3) tumors.⁹ Given the paucity of published cases, it is not yet possible to tell to what extend this coexistence of AML and RCC influences the prognosis.¹⁰¹¹¹²

AML is present in 50 to 80% of cases of TSC, and their partnership is more close with epithelioid variant of renal AML, an entity of relatively recent description, with few reports in the literature, which is characterized by its aggressiveness.³⁴⁵ It is known that more than half of patients with AMLE have ET.⁶⁷⁹

AMLE affects both sexes equally, with an average age at diagnosis of 38 years.¹⁸ Patients are symptomatic, complaining of flank pain, palpable mass, and less than 15% will present renal failure due to compression and replacement of renal parenchyma. Is a tumor that brings a diagnostic problem, often being interpreted as a renal cell carcinoma, or high-grade sarcoma. The imaging studies

simulate clear cell carcinoma scanty fatty tissue.^{9,10,11,12}

Macroscopically, tumors are medium to large size, yellowish-orange with large areas of hemorrhage and necrosis. There may be extrarenal tumor extension or involvement of the vena cava or renal vein. Microscopically, is an infiltrating tumor, very cellular, consisting mainly of polygonal cells with vacuolate cytoplasm, eosinophilic granular or clear, with plenty of glycogen, and other multinucleated similar to the ganglion cells. Can also be found a small proportion of fusiform cells. Cells samples nuclear anaplasia, mitotic activity with presence of atypical figures, vascular invasion, necrosis and inflammatory response. The bleeding is prominent. Few cases show focal areas of classic AML. Most cases, as in the present case, lack the typical elements of AML.¹⁹ Immunohistochemistry is important to characterize this tumor. The presence of immunoreactivity positive for HMB45, HMB50, CD117, CD63, and the negativity to epithelial markers and cytokeratins confirm the diagnosis.²

It has also been described an expression variable markers for smooth muscle (smooth muscle actin and actin specific muscle). Genetically, it shares the same alteration than the classic AML; that is, the loss of allelic short arm of chromosome 16p (TS2). Furthermore, mutations in the p53 gene in the epithelioid variant have been identified, suggesting an important role in their malignant behavior.^{3,4,13}

In approximately one third of cases metastases of AMLE have been described to lymph nodes, liver, lung, bone and marrow. To date, no pathological parameters have been identified which directly correlates with survival. However, tumors with necrosis, mitotic activity and nuclear anaplasia, have a more aggressive behavior.^{10,11,12}

The management of renal AMLs is widely discussed in the literature. The most widely accepted is the therapeutic algorithm of Oesterling et al,¹⁴ based on clinical presentation, the size of the tumor and bilaterality. Thus, in asymptomatic tumors, evaluation with abdominal ultrasound and/or CT-scan every six or twelve months, depending on the size of the tumor, greater or less than 4 cm., respectively, is necessary. In symptomatic and/or bilateral tumors, artery embolization, selective kidney or conservative surgery (nephron sparing) are the treatments of choice. Radical nephrectomy is reserved for those cases with hemodynamic instability due to massive bleeding, large tumors, or

coexistence with carcinoma in the same kidney,^{9,15} criteria considered in the clinical management of the present case.

CORRESPONDENCE TO

Milagros Abad Licham, MD. Department of Oncology-Pathology Instituto Nacional de Enfermedades Neoplásicas Av. Angamos Este 2520, Surquillo, Lima – Perú. e-mail: milagros.abad@hotmail.com, jca_astigueta@hotmail.com

References

1. Martigoni G, Amin MB. Angiomyolipoma. En Tumours of the urinary system and male genital organs. Lyon France. WHO IARC; 2004: 63-67.
2. Amin MB. Epithelioid angiomyolipoma. En Tumours of the urinary system and male genital organs. Lyon France. WHO IARC; 2004: 68-69.
3. Eble JN, Amin MB and Young RH. Epithelioid angiomyolipoma of the kidney: a report of five cases with a prominent and diagnostically confusing epithelioid smooth muscle component. Am J Surg Pathol. 1997; 21: 1123.
4. Serrano Frago P, Del Agua Arias Camison C, Gil Sanz MJ, Allue Lopez M, Gonzalvo Ibarra A, Plaza Mas L et al: Controversies related to epithelioid variant of renal angiomyolipoma: a review of the literature. Urology 2006; 67: 846.
5. Acikalin MF, Tel N and Oner U. Epithelioid angiomyolipoma of the kidney. Int. J Urol. 2005; 12(2): 204-207.
6. Bjornsson J, Short MP, Kwiatkowski DJ and Henske EP. Tuberous sclerosis associated renal cell carcinoma, clinical, pathological and genetic features. Am J Surg Pathol. 2001; 25: 121.
7. Roach ES, Gomez MR and Northrup H. Tuberous sclerosis complex consensus conference: revised clinical diagnostic criteria. J Child Neurol 1998; 13: 624.
8. Nelson CP and Sanda MG. Contemporary diagnosis and management of renal angiomyolipoma. J Urol 2002; 168: 1315.
9. Lane BR, Aydin H, Danforth T, Zhou M, Remer E, Novick AC and Campbell SC: Clinical correlates of renal angiomyolipoma subtypes in 209 patients classic, fat poor, tuberous sclerosis associated and epithelioid. J Urol 2008; 180: 836-843.
10. Christiano AP, Yang X and Gerber GS: Malignant transformation of renal angiomyolipoma. J Urol 1999; 161: 1900.
11. Kawaguchi K, Oda Y, Nakanishi K, Saito T, Tamiya S, Nakahara K et al: Malignant transformation of renal angiomyolipoma: a case report. Am J Surg Pathol 2002; 26: 523.
12. Jimenez RE, Eble JN, Reuter VE, Epstein JI, Folpe AL, de Peralta-Venturina M et al: Concurrent angiomyolipoma and renal cell neoplasia: a study of 36 cases. Mod Pathol 2001; 14: 157.
13. Danforth TL, Lane BR and Novick AC: Conservative management of giant symptomatic angiomyolipoma in patients with tuberous sclerosis complex. BJU Int 2007; 100: 794.
14. Oesterling JE, Fishman EK, Goldman SM and Marshall FF: The management of renal angiomyolipoma. J Urol 1986; 135: 1121.
15. Dickinson M, Ruckle H, Beaghtler M and Hadley HR: Renal angiomyolipoma: optimal treatment based on size and symptoms. Clin Nephrol 1998; 49: 281.

Author Information

Juan C. Astigueta

Departamento de Urología, Instituto Nacional de Enfermedades Neoplásicas

Milagros A. Abad, MD

Departamento de Patología Oncológica, Instituto Nacional de Enfermedades Neoplásicas

Mariela R. Pow-Sang, MD

Departamento de Urología, Instituto Nacional de Enfermedades Neoplásicas

Carlos Morante, MD

Departamento de Urología, Instituto Nacional de Enfermedades Neoplásicas

Luiz Meza, MD

Departamento de Urología, Instituto Nacional de Enfermedades Neoplásicas

Victor Destefano, MD

Departamento de Urología, Instituto Nacional de Enfermedades Neoplásicas

Jaime Montes, MD

Departamento de Patología Oncológica, Instituto Nacional de Enfermedades Neoplásicas

Richard Dyer, MD

Departamento de Patología Oncológica, Instituto Nacional de Enfermedades Neoplásicas