

Paraganglioma of the cauda equina

K Mardi, R Thakur

Citation

K Mardi, R Thakur. *Paraganglioma of the cauda equina*. The Internet Journal of Neurosurgery. 2008 Volume 6 Number 1.

Abstract

Paragangliomas of the cauda equina are rare neuroendocrine tumors. We present a case of nonsecreting paraganglioma of the cauda equina, preoperatively misdiagnosed as neurofibroma. A 42year old lady presented with pain and burning sensation in the lower back. MRI showed an intradural / extra medullary well defined mass at the L4,L5 level. Microscopic examination of the resected tumor revealed paraganglioma. The tumor cells were positive for chromogranin and synaptophysin. Although it is difficult to correctly diagnose paraganglioma preoperatively , especially in the region of cauda equina, it should be included in differential diagnoses.

INTRODUCTION

A paraganglioma of cauda equina region is extremely rare and since most of them are nonsecreting tumours, the pre-operative diagnosis of paraganglioma is very difficult. Histologically these neoplasms may have considerable similarity with ependymoma, the most common neoplasm of the lower spinal cord, and the diagnosis can be easily missed unless special techniques are employed. The clinical and pathological data obtained from this and the other reported examples suggests that paragangliomas of the cauda equina are benign, slowly growing neoplasms. In contrast to ependymomas and to paragangliomas elsewhere, they are well circumscribed, amenable to complete resection and have an excellent prognosis.

CASE REPORT

A 42year old female presented with pain and burning sensation in the lower back . Pain was moderate and intermittent initially and became continuous in the last six months. Pain was radiating to the gluteal region and increased on coughing and taking deep breath. There was no history of urinary or bowel problem. On clinical examination ,motor and sensory systems were within normal limits. All the reflexes were present. The spine showed no deformity. X ray of the lumbar spine was also normal However MRI showed an intradural / extra medullary well defined mass at the L4,L5 level. Possibilities of neurofibroma and ependymoma were suggested. Laminectomy of L₅- S₁ with near total excision of the tumor was conducted and 3x3 c.m multilobular pinkish, friable mass arising from cauda equine was excised.

PATHOLOGICAL FINDINGS

We received three pale tan coloured soft tissue masses measuring 2.5 x 1x0.5c.m.with nodular outer surface. Cut surface of these were pale tan in colour with areas of hemorrhage. On Microscopic examination, The tumor was partially encapsulated and comprised of nests and broad anastomosing trabeculae of round to polygonal cells tumor cells separated by delicate fibrovascular septa (zellballen pattern).These tumor cells showed moderately abundant eosinophilic cytoplasm , central round to oval nucleus with finely stippled chromatin, occasional nucleolus and intranuclear inclusion. The tumor cells were positive for chromogranin and synaptophysin.

Figure 1

Figure 1:Showing tumor cells arranged in zellballen pattern(H&E,20x)

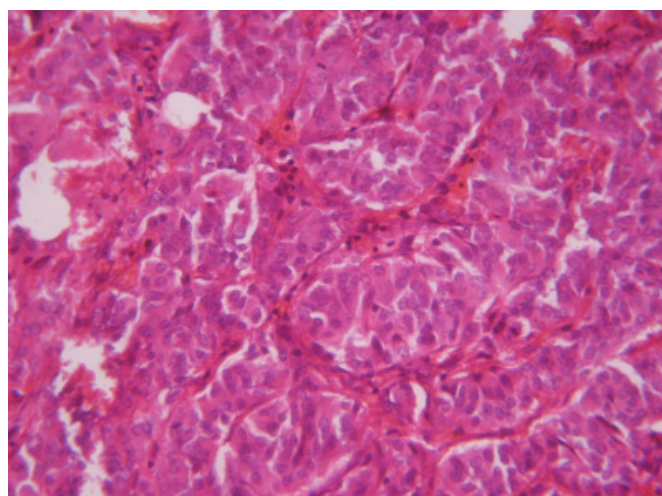
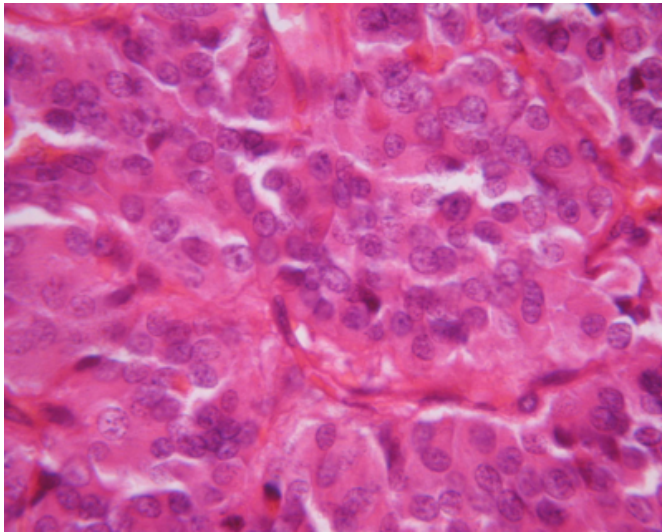


Figure 2

Figure 2: Higher magnification showing round to polygonal tumor cells with round to oval nucleus and finely stippled chromatin (H&E, 40x)



DISCUSSION

Parangliomas are rare benign tumors arising from the heterotopic sympathetic ganglion.¹² Cauda equina parangliomas were first reported by Lerman and Kaplan in 1972.³ Primary parangliomas of craniospinal axis are predominantly found in the intradural, extramedullary compartment at the level of the cauda equina.³ Cases in pineal gland, pituitary, cerebellopontine angle have been reported. They are generally found in the middle-aged population, ranging from 13 to 71 years.⁴⁵

The histogenesis of cauda equina parangliomas remains enigmatic. Interestingly, Caccamo et al.⁶ have described a cauda equina tumor with both ependymal as well as paranglionic differentiation, confirmed both immunohistochemically and ultrastructurally. The authors speculated that this tumor arose from elements normally found in the human filum terminale, such as ependymal cells, ganglionic neurons and neuroblasts. Moreover, in human newborns the existence of ependymal cells with neurosecretory activity has been reported in the filum terminale.⁷ Despite these studies, any transdifferentiation-hypotheses regarding ependymal and neuroendocrine/neuronal cells in humans are at present highly speculative.

Although morphologically similar to adrenal tumours of this type, parangliomas of the cauda equina differ in that the vast majority (97%) do not secrete catecholamines.²⁸ Patients typically present with clinical signs and symptoms

referable to a lesion in the cauda equina (cauda equina syndrome), manifested by lower lumbar pain, sensory or motor loss to the lower extremities, and bowel and bladder dysfunction.^{9,10} The duration of symptoms varies from days to years. Cerebrospinal fluid protein is usually elevated. Radiologically, parangliomas of the cauda equina are typically hypo- or isointense to the spinal cord on T1-weighted images, hyperintense on T2-weighted images, and strongly contrast-enhancing.⁴ Pathologically, these are solid, highly vascularized, slow-growing intradural extramedullary masses. They are well encapsulated and originate from the proximal filum terminale. Cystic components may be found within the tumors. Histologically these tumors are similar to paranglioma elsewhere. However the tumor cells manifest greater tendency for ganglion cell and schwannian differentiation. Presence of nucleomegaly, pleomorphism and occasional mitosis do not signify malignancy in these tumors. Immunohistochemically the tumors show positivity for Neurofilament protein, Neuron specific enolase, Chromogranin, Synaptophysin. Some cases also show positivity for serotonin, somatostatin and occasional positivity for keratin. Ultrastructurally, the tumor cells show intracytoplasmic dense core neurosecretory granules, lamellar stacks of rough EPR, well developed golgi apparatus, fenestrated endothelial cells, cilia and fibrous bodies in the cytoplasm. The last two features occur only in parangliomas of this site.

The differential diagnosis of a mass in the cauda equina region includes ependymoma, nerve sheath tumor, meningioma, lipoma, dermoid, and hematogenous or drop metastasis. Ependymoma is the most common tumor in this location. It resembles paranglioma because of location, encapsulation and perivascular arrangement of cells. Occasional variants with pseudopapillary structure and perivascular arrangement resemble myxopapillary ependymoma but can be differentiated by lack of mucoid matrix and characteristic immunohistochemical and EM findings. However, it is difficult to distinguish preoperatively the paranglioma from other tumours of the cauda equina. In none of the few cases reported in literature a preoperative diagnosis was possible, and the surgical findings raised questions in the differential diagnosis with ependymomas.

Current WHO classification of CNS tumors classifies paranglioma as grade I tumor. Complete surgical resection is considered curative and subtotal resection often leads to recurrence. Total excision is often very difficult owing the tendency of these neoplasms to infiltrate cauda's roots. Less

than 1% are locally aggressive.¹¹ Rare case of cerebellar metastasis has been reported. Slow growth and delayed recurrence make long-term follow-up of these lesions necessary.

CORRESPONDENCE TO

Dr.Kavita Mardi ,MD,DNB Associate Professor 12-A, Type V Quarters GAD Colony Kasumpti, Shimla, H.P E. mail: kavitamardi@yahoo.co.in

References

1. Yang SY, Jin YJ, Park SH, Jahng TA, Kim HJ, Chung CK. Parangliomas in the cauda equina region: clinicopathologic findings in four cases. *J Neurooncol* 2005 ;72:49-55.
2. Caruso R, Wierzbicki V, Marrocco L, Salvati M. Parangliomas of the cauda equina. Report of one case and review of the literature. *J Exp Clin Cancer Res* 2006 ;25:269-75.
3. Lerman A, Kaplan E, Daman L. Ganglioneuroma paranglioma of the intradural filum terminale. *J Neurosurg* 1972;36:652-8.
4. Soffer D, Scheithauer B. Paranglioma. Pathology and genetics of tumours of the nervous system. In: Kleihues P, Cavenee WK, editors. World Health Organisation classification of tumours. Lyon: IARC Press; 2000. 112-14
5. Vita TV, Hellman S, Rosenberg SA. Cancer of the head and neck. In: DeVita TV, Hellman S, Rosenberg SA, editors. *Cancer: Principles and practice of oncology*. Philadelphia: Lippincott-Raven; 2001. p. 841-46.
6. Caccamo DV, Ho KL, Garcia JH . Cauda equina tumor with ependymal and paranglionic differentiation. *Hum Pathol* 1992; 23:835-37.
7. Miller CA, Torack RM . Secretory ependymoma of the filum terminale. *Acta Neuropathol* 1970; 15:240-50.
8. Noorda JP, Wuisman PIJM, Kummer AJ, Winters HA, Rauwerda JA, Egeler-Peerdeman SM. Nonfunctioning malignant paranglioma of the posterior mediastinum with spinal cord compression. A case report. *Spine* 1996;14:1703-09.
9. Sonneland PRL, Scheithauer BW, Lechago J, et al. Paranglioma of the cauda equina region: clinicopathologic study of 31 cases
10. *Cancer* 1986;15:1720-35.
11. Iliadis C, Kirgiannis K, Wozniak G, Vlychou M, Santarius T, Kirollos RW. . Parangliomas of the cauda equina. *Neurologia i Neurochirurgia Polska* 2008; 42, 5: 463-66.
12. Moran CA, Rush W, Mena H .Primary spinal parangliomas: a clinicopathological and immunohistochemical study of 30 cases. *Histopathology* 1997 ;31:167-73.

Author Information

Kavita Mardi, MD, DNB

Associate Professor, Deptt of Pathology, Indira Gandhi Medical College

R.C. Thakur, MD

Professor and Head, Deptt of Neurosurgery, Indira Gandhi Medical College