

# Large Asymptomatic Adrenal Incidentaloma

S Tiwary, M Singh, R Shukla, V Shukla

## Citation

S Tiwary, M Singh, R Shukla, V Shukla. *Large Asymptomatic Adrenal Incidentaloma*. The Internet Journal of Surgery. 2005 Volume 8 Number 2.

## Abstract

Incidentally discovered adrenal masses, or adrenal incidentalomas, have become a common clinical problem owing to wide application of radiologic imaging techniques. The significance of these masses, as well as the optimal approach to management, has generated some controversy regarding further evaluation and therapy. Most of the tumors are benign and hormonally inactive. Surgery is the ideal and ultimate solution of diagnostic and therapeutic dilemma related to such asymptomatic masses. A large adrenal tumor was detected during ultrasonography of abdomen in a patient with chronic cholecystitis with cholelithiasis.

## INTRODUCTION

The term 'adrenal incidentaloma' (AI) refers to an adrenal mass unexpectedly detected through an imaging procedure done for reasons unrelated to adrenal dysfunction. This definition encompasses a heterogeneous spectrum of pathologic entities, including primary adrenocortical and medullary tumors, benign or malignant lesions, hormonally active or inactive lesions, metastases, and infections Extra-adrenal pheochromocytomas are known as paraganglioma & comprise 15-18 % of all pheochromocytomas<sup>2, 3</sup>. Location of paraganglioma may be at any site where paraganglion is present. Superior para-aortic region (between diaphragm and the inferior renal poles) is the most common site (46%) of paraganglioma followed by inferior para-aortic region (29%)<sup>3</sup>. Thorax & urinary bladder, each have 10% cases of paraganglioma & remainder are at other sites<sup>3</sup>. Origin of pheochromocytoma in or around adrenal gland should be regarded as pheochromocytoma, but paraganglioma may present with origin around adrenal gland. A large incidental mass of adrenal was detected in a patient of chronic cholecystitis with cholelithiasis by ultrasound which proved to be pheochromocytoma after adrenalectomy.

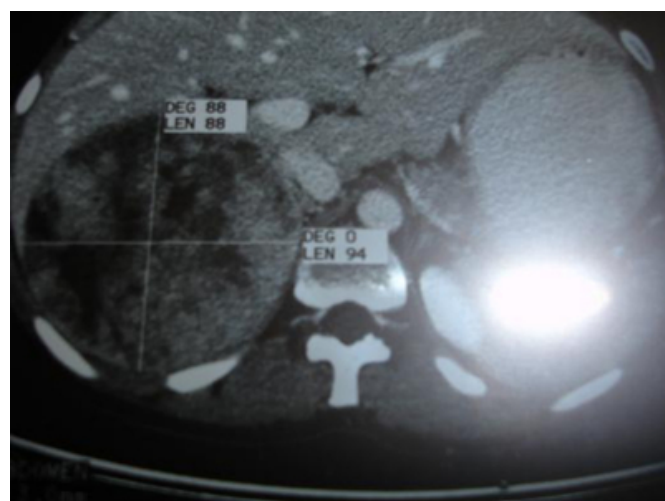
## CASE REPORT

A 22 years female was presented with pain right upper quadrant of abdomen for 6 months. Nausea and vomiting were associated. Physical examination was unremarkable. No other abnormalities e. g hypertension, diabetes mellitus, headache could be detected after examination of the patient & subsequent investigations. Ultrasound examination

revealed a large mass of right adrenal gland in addition to chronic cholecystitis and cholelithiasis. Urinary catecholamines were not raised. There were no clinical findings suggestive of endocrine neoplasm. CT scan of upper abdomen revealed a mass of upper pole of right adrenal gland measuring 12.6cm X 10.5 cm in size (Fig 1). A provisional diagnosis of adrenal incidentaloma was made. Patient underwent adrenalectomy along with cholecystectomy.

## Figure 1

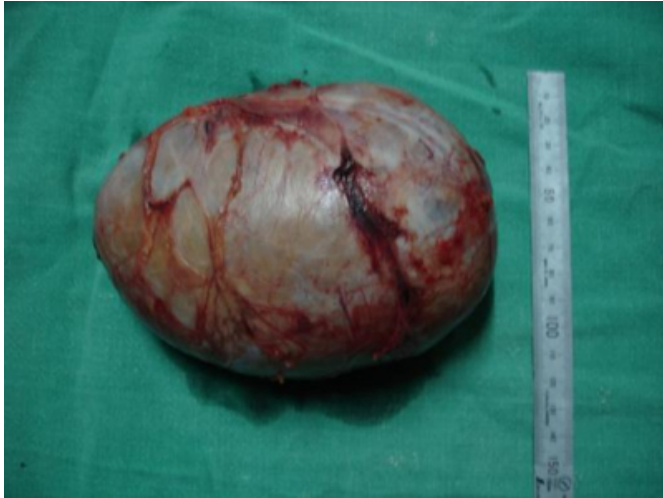Figure 1: CT. scans showing right adrenal pheochromocytoma.



Gross examination of tumor revealed encapsulated surface with well circumscribed margin (Fig 2).

**Figure 2**

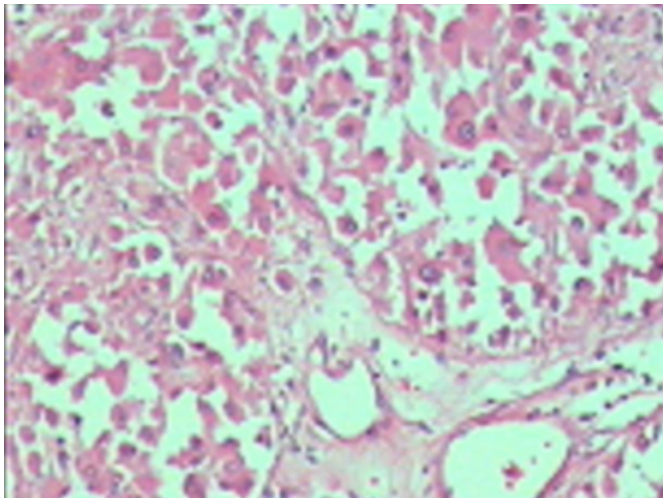
Figure 2: Resected specimen of pheochromocytoma.



On cut section, surface was yellow and variegated with widespread area of hemorrhage and necrosis. Microscopic examination revealed it to be pheochromocytoma (Fig 3) with minimal cytological pleomorphism.

**Figure 3**

Figure 3: Photomicrograph of adrenal pheochromocytoma.



There was no extension outside adrenal gland. Multiple foci of hemorrhage and necrosis were identified. These findings were suggestive of benign pheochromocytoma.

## DISCUSSION

Despite the rarity of primary endocrine cancers of the adrenal, adrenal masses are not uncommon human tumors. The prevalence of adrenal incidentaloma approaches 3% in middle age, and increases to as much as 10% in the elderly <sup>4</sup>. The differential diagnosis of an incidentally discovered mass of adrenal is extensive, but most are nonsecreting cortical

adenomas. In a recent systematic review that combined studies using the broadest definitions, adenomas were the most common accounting for 41%. Metastasis 19%, adrenocortical carcinoma 10%, myelolipoma 9% and pheochromocytoma 8%, with other usually benign lesions such as adrenal cysts comprised the remainder <sup>5</sup>. Follow-up of patients with nonfunctioning adrenal masses suggests that the majority of adrenal lesions remain stable in size. About 5–25% increase in size by at least 1 cm and 3–4% decrease in size <sup>6</sup>. The threshold for clinically significant increase in size is unknown, particularly since the reproducibility of size determination by imaging procedures is unknown. The risk of malignancy appears to be low. Up to 20% of patients develop hormone overproduction; while this is less likely in tumors less than 3 cm. The risk of tumor becoming hormonally active reaches to plateau after 3–4 years. Adrenal scintigraphy has proved useful in discriminating between benign and malignant lesions. Finally, fine-needle aspiration biopsy is an important tool in the evaluation of oncological patients and it may be useful in establishing the presence of metastatic disease. Patients of cortical carcinomas have a very poor clinical outcome <sup>7</sup>.

The majority of AI are non-hypersecretory cortical adenomas, but an endocrine evaluation can lead to the identification of subtle hormone excess. A benign and hormonally inactive tumor neither poses a risk to a patient's health nor warrants the risks of further diagnosis and treatment. The challenge is to recognize and treat the small percentage of AI that does pose a significant risk, either because of their hormonal activity or because of their malignant histology. Mass size is the most reliable variable to distinguish benign and malignant adrenal masses. Approximately 25% of masses greater than 6 cm in diameter are adrenal cortical carcinomas. Adrenalectomy should be recommended for masses greater than 4.0 cm because of the increased risk of malignancy. Pheochromocytoma is a frequent cause of clinically inapparent adrenal masses, accounting for 1.5–23% of these masses. In a review of 40,078 autopsies at the Mayo Clinic between 1928 and 1977, pheochromocytoma was found in 0.13% and had not been diagnosed in 76% of the patients while alive <sup>8</sup>.

The incidence of adreno-hepatic fusion is reported to be 9.9% among autopsy cases <sup>9</sup>. Tumors situated above right adrenal gland may be paraganglioma. Pheochromocytoma arising from the neural crest can migrate to various locations in autonomic tissue, most commonly the sympathetic ganglia and the organ of Zuckerkandl. We supposed the case

to be a pheochromocytoma, but higher location of the tumor and situation over upper pole of right adrenal gland kept a possibility of paraganglioma also. If such type of tumor located in adrenohepatic fusion it develops towards liver. It may invaginate into liver with its blood supply from right adrenal artery <sup>10</sup>. Other tumor which may be considered to be located here asymptotically and detected incidentally is adrenal rest tumor which is derived from ectopic adrenocortical cells. But it is very rare with only for cases have been reported up to 1986 <sup>11</sup>.

In conclusion, all pheochromocytomas over right adrenal gland may not be pheochromocytoma. Some may be paraganglioma or adrenal rest tumor derived from ectopic adrenocortical cells. Surgery with adrenalectomy should be recommended to solve the diagnostic-therapeutic puzzle related to large size tumors (> 4 cm).

### CORRESPONDENCE TO

Dr. V. K. Shukla, MCh (Wales) Professor Department of General Surgery Institute of Medical Sciences Banaras Hindu University Varanasi - 221 005, India. Tel. 91-542-2307507 Fax : 91-542-2367568, 2368174 Email: vkshuklabhu@satyam.net.in

### References

1. Bertherat J, Mosnier-Pudar H, Bertagna X. Adrenal incidentalomas. *Current Opinion in Oncology* 2002; 14:58-63.
2. Moutton J.S, Moulton JS. CT of the adrenal glands. *Semin Roentgenol* 1988; 23:288-303.
3. Whalen RK, Athausen AF, Daniels GH. Extra-adrenal pheochromocytoma *J Urol* 1992; 1-10.
4. Aron DC. The adrenal incidentaloma: disease of modern technology and public health problem. *Reviews in Endocrine and Metabolic Disorders* 2001; 2: 335-342.
5. Kloos RT, Gross MD, Francis IR, Korobkin M, Shapiro B. Incidentally discovered adrenal masses. *Endocr Rev* 1995; 16:460-484
6. Libe R, Dall'Asta C, Barbetta L, Baccarelli A & Beck-Peccoz P. Long-term follow-up study of patients with adrenal incidentalomas. *European Journal of Endocrinology* 2002; 147:489-494.
7. Mansmann G, Lau J, Balk E, Rothberg M, Miyachi Y & Bornstein SR. The clinically inapparent adrenal mass: update in diagnosis and management. *Endocrine Reviews* 2004; 25:309-340.
8. Sutton MG, Sheps SG, Lie JT. Prevalence of clinically unsuspected pheochromocytoma. Review of a 50-year autopsy series. *Mayo Clin Proc* 1981; 56:354-360[.
9. Honmac K. Adreno-hepatic fusion. An autopsy study. *Zentrab Pathol* 1991; 137:117-22.
10. Ueda J, Takaysu K, Muramatsu Y, Iwata R, Kosuge T, Sakamoto Satake M, Pheochromocytoma growing exophytically from the right adrenal gland & unvaginating into the liver.
11. Conteras P, Altieri E, Liberman C, Gac A, Rojas A, Ibarra A et al. Adrenal rest tumor of the liver causing Cushing syndrome; treatment with ketoconazole preceding an apparent surgical care. *J Chin Endocrinol Metab* 1985; 60:21-8.

**Author Information**

**Satyendra K. Tiwary, M.S.**

Senior Resident, Department of General Surgery and Radiology, Institute Of Medical Sciences, Banaras Hindu University

**Manish K. Singh, M.B.B.S.**

Junior Resident, Department of General Surgery and Radiology, Institute Of Medical Sciences, Banaras Hindu University

**R. C. Shukla, M.D.**

Reader, Department of General Surgery and Radiology, Institute Of Medical Sciences, Banaras Hindu University

**Vijay K. Shukla**

Professor, Department of General Surgery and Radiology, Institute Of Medical Sciences, Banaras Hindu University