

# Gastric Heterotopia of the Rectum: A Case Report

B Wildemore, V Ciocca, A Infantolino, B O'Hara

## Citation

B Wildemore, V Ciocca, A Infantolino, B O'Hara. *Gastric Heterotopia of the Rectum: A Case Report*. The Internet Journal of Pathology. 2006 Volume 5 Number 2.

## Abstract

We report a case of gastric heterotopia found in the rectum during colonoscopic examination of a 34-year-old female. The lesion was diagnosed in a patient who presented with a change in bowel habits and other intestinal complaints. The decision was made to perform an elective colonoscopic examination with biopsy of a suspicious area in the rectum. Pathologic examination of the biopsy specimen confirmed the diagnosis of gastric heterotopia. A thorough review of the literature reveals that only 40 cases of gastric heterotopia have been reported in the rectum, and most of these were identified as single, sessile polyps. This case highlights the importance of recognizing this unusual histologic entity.

## INTRODUCTION

Ectopic gastric mucosa has been described at various locations in the body including the mouth, esophagus, duodenum, pancreas, biliary system, small bowel, mediastinum, scrotum, bladder, and spinal cord (1). Nevertheless, gastric heterotopia of the rectum is a rare finding, with only 40 cases reported in the literature to date. We describe a case of gastric heterotopia in the rectum and review the potential manifestations, likely etiologies, and diagnostic pitfalls for this unusual biopsy finding.

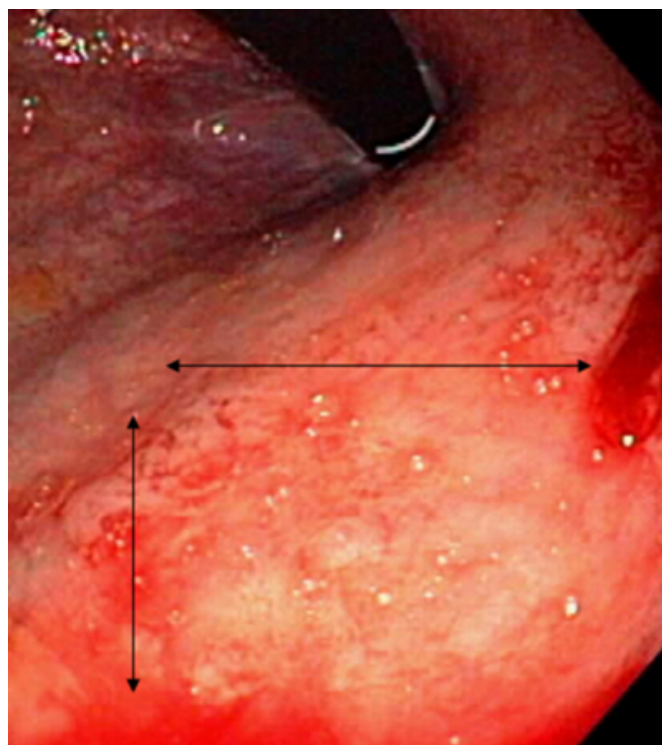
## CASE REPORT

A 34-year old female presented with altered bowel habits, abdominal bloating, excessive "intestinal noise," visible abdominal distention, and occasional nausea. She denied any rectal bleeding, and had no family history of colon cancer. The patient had undergone a colonoscopy approximately four years prior secondary to irritable bowel syndrome complaints. The colonoscopic examination was normal at that time.

Colonoscopic examination at the current presentation revealed the colonic mucosa to be normal. A single non-bleeding smooth polyp, described as salmon in color, was seen in the rectum that measured 1.5cm. The affected area was slightly raised, sessile, and well circumscribed. There appeared to be some furrowing within this "polyp". Dyes were not originally applied, and magnification endoscopy unavailable. This polyp did not involve the anal verge and showed no stigmata of recent hemorrhage (Figure 1).

## Figure 1

Figure 1: Colonoscopic view of a single large sessile polyp seen in the rectum (arrows delineate the polyp).



Multiple biopsies were obtained and sent for pathologic examination. On retroflexed view, other than the polyp, the examination was unremarkable.

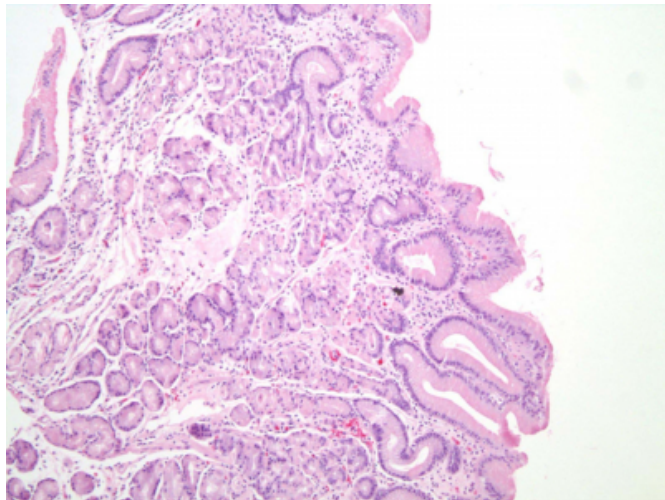
## PATHOLOGIC FINDINGS

The fragmented polyp was received in formalin and measured 1.4 x 1 x 0.5 cm in aggregate. Paraffin embedded

tissue was sectioned at 5 microns and multiple levels were evaluated with routine hematoxylin and eosin stain. Benign fundic-type gastric mucosa was present on microscopic examination (Figure 2).

### Figure 2

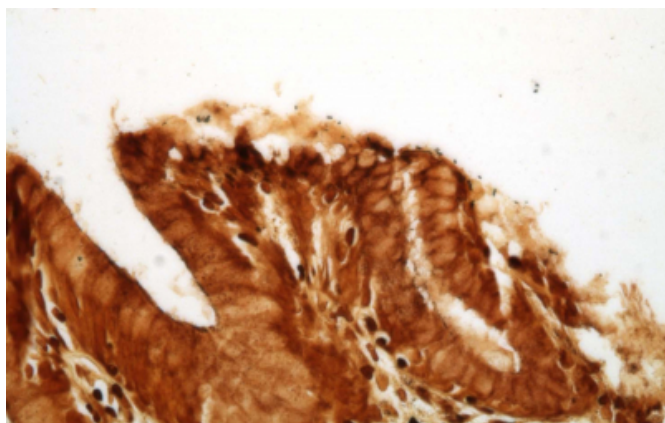
Figure 2: Fundic-type gastric mucosa in a rectal biopsy (hematoxylin and eosin, 40x)



No colonic mucosa was identified. No dysplastic epithelium was identified. A Warthin-Starry stain highlighted *Helicobacter*-like organisms located on the surface of the gastric-type mucus cells (Figure 3).

### Figure 3

Figure 3: *H. pylori* like organisms on surface of mucosal cells (warthin starry, 400x)



## DISCUSSION

Rarely does the histologic evaluation of a colorectal polypectomy specimen reveal heterotopic gastric mucosa. Heterotopic gastric mucosa in the rectum has only been described in 40 published reports, usually presenting as small sessile polyps. Vieth et al reported that peptic lesions or repeated mechanical manipulation may “displace”

heterotopic gastric glands into the submucosa in a pseudoinvasive manner (2). However, the clinical history of our patient was unremarkable regarding prior rectal injury.

Review of the literature through 2006 contains 40 cases of gastric heterotopia of the rectum. The first case of gastric heterotopia of the rectum was reported by Ewell and Jackson in 1939 (3). The lesion was found to be more common in males than females, with an average age at presentation of about 21 years (4). The most common symptom at presentation was painless rectal bleeding, with abdominal pain and diarrhea also being reported. The heterotopic tissue was frequently located in the posterolateral region of the rectum, between 5 and 8cm from the anal verge (5). This patient did not report any bleeding per rectum, but instead presented with symptoms of irritable bowel syndrome.

Embryologic development of the esophagus and stomach occurs at approximately the fourth week of gestation. During this period, the esophagus develops as the foregut is divided into the ventral respiratory portion and the dorsal esophageal portion. Subsequently, the stomach appears as a fusiform dilatation of the foregut and its appearance changes as various regions of its wall grow at different rates. The stomach also rotates as the position of the surrounding organs is determined. Developmental errors in this formation from failure of these structures to develop correctly can be implicated in instances of gastric heterotopia in the foregut, where it is most frequently seen in the esophagus (6).

Although there is no agreement regarding the origin of the gastric tissue found at these ectopic sites, a few theories have been postulated. It has been suggested that congenital gastric heterotopia results from an error during fetal development in the differentiation of pluripotent endodermal stem cells (4). This theory is supported by the immunocytochemical studies of Carlei et al. who demonstrated that the metabolic and functional activity of gastric heterotopic mucosa regarding the production of acid and mucin is identical to that of the normal stomach (1, 7). Another theory detailing a congenital origin involves the failure of the developmental descent of the fetal foregut. In contrast, other authors suggest that gastric heterotopia is an acquired condition, similar to Barrett's esophagus, whereby abnormal regeneration of the mucosal cells after trauma or a destructive process results in metaplasia (4).

*Helicobacter pylori* (*H. pylori*) may colonize gastric mucosa wherever it is found in the alimentary tract, and the manifestations of infection, including ulceration and

bleeding, may be similar to those seen in the stomach. Dye et. al. reported a case of rectal gastric heterotopia, positive for *H. pylori* by histochemical stain, found to be actually colonized with organisms (8). This finding supports the possibility that *H. pylori* may pass along the gastrointestinal tract in a viable form. Kestenberg et. al. felt that the findings of *H. pylori* organisms in a typical distribution on the surface of the gastric-type mucus cells in the rectum gives strength to the theory that the bacteria may be eliminated in the feces (1). A warthin-starry histochemical stain of our biopsy highlighted a few rod-shaped organisms that had morphologic features consistent with *H. pylori*. A biopsy of the patient's gastric antrum obtained at the same time showed only scattered chronic inflammatory cells within the lamina propria and a special stain for *H. pylori* was negative. Despite these results, *H. pylori* infection cannot be ruled out as this biopsy represents only a limited area of the stomach. Given the negative pathology results, additional confirmatory testing (such as the sensitive urease breath test or *H. pylori* stool antigen test) was not done. Nevertheless, this finding provides additional evidence that the organisms may in fact be passed with feces and contribute to the ulceration and bleeding commonly seen in these cases.

Identification of the gastric mucosa is usually made on biopsy, as it would be difficult to identify the gastric mucosa prior to the development of a visible abnormality by direct visualization. In many of the cases cited, the symptoms had been present for many years, and the patients underwent extensive work-up prior to diagnosis (5). Surgical excision or polypectomy is the preferred treatment modality, with complete symptomatic relief occurring in most cases following excision. Since this type of lesion can occur anywhere in the alimentary tract, long-term follow-up is

recommended for all patients (9). In this case, endoscopic mucosal resection (EMR) was not done as this was felt to be a benign condition and there is no established recommendation for removal. Instead, the patient is to be followed with periodic flexible sigmoidoscopies. Since this is such a rare case and there are no guidelines, it is uncertain whether it needs to be removed or simply just followed. Furthermore, it is unclear whether there is increased malignant potential. EMR will be discussed with the patient on a follow-up visit.

### References

1. Kestenberg A, Marino G, de Lima E, Garcia FT, Carrascal E, Arredondo JL. Gastric heterotopic mucosa in the rectum with *Helicobacter pylori*-like organisms: a rare cause of rectal bleeding. *Int J Colorectal Dis*. 1993;8(1):9-12.
2. Vieth M, Kushima R, de Jonge JP, Borchard F, Oellig F, Stolte M. Adenoma with gastric differentiation (so-called pyloric gland adenoma) in a heterotopic gastric corpus mucosa in the rectum. *Virchows Arch*. 2005;446(5):542-5.
3. Ewell GH, Jackson RH. Aberrant gastric mucosa in the rectum with ulceration and hemorrhage. *World J Surg*. 1939; 38:641-3.
4. Steele SR, Mullenix PS, Martin MJ, et al. Heterotopic gastric mucosa of the anus: a case report and review of the literature. *Am Surg*. 2004;70(8):715-9.
5. Devereaux CE, Devereaux RG. Heterotopic gastric mucosa of the rectum with a review of the literature. *J Clin Gastroenterol*. 1994;19(1):41-5.
6. Srinivasan R, Loewenstine H, Mayle JE. Sessile polypoid gastric heterotopia of rectum: a report of 2 cases and review of the literature. *Arch Pathol Lab Med*. 1999;123(3):222-4.
7. Carlei F, Pietroletti R, Lomanto D, et al. Heterotopic gastric mucosa of the rectum--characterization of endocrine and mucin-producing cells by immunocytochemistry and lectin histochemistry. Report of a case. *Dis Colon Rectum*. 1989;32(2):159-64.
8. Dye KR, Marshall BJ, Frierson HF Jr, Pambianco DJ, McCallum RW. *Campylobacter pylori* colonizing heterotopic gastric tissue in the rectum. *Am J Clin Pathol*. 1990;93(1):144-7.
9. De Angelis P, Trecca A, Francalanci P, et al. Heterotopic gastric mucosa of the rectum. *Endoscopy*. 2004;36(10):927.

**Author Information**

**Bernadette M. Wildemore, M.D.**

Department of Pathology, Thomas Jefferson University Hospital

**Vincenzo Ciocca, D.O.**

Department of Pathology, Thomas Jefferson University Hospital

**Anthony Infantolino, M.D.**

Department of Gastroenterology and Hepatology, Thomas Jefferson University Hospital

**Brian J. O'Hara, M.D.**

Department of Pathology, Thomas Jefferson University Hospital