Nasopharyngeal Myiasis: Report of an unusual case with a brief review of literature.

P Adhikari, B Pradhan, S Khanal, S Khalilulla

Citation

P Adhikari, B Pradhan, S Khanal, S Khalilulla. *Nasopharyngeal Myiasis: Report of an unusual case with a brief review of literature.*. The Internet Journal of Head and Neck Surgery. 2009 Volume 4 Number 1.

Abstract

We report a case of nasal myiasis in a 43-year-old female presented from a remote area of Nepal. More than 150 maggots were removed from her nose and nasopharynx. She was managed conservatively and became completely free of maggots. A brief review of literature on nasal myiasis is also included.

INTRODUCTION

The term myiasis is derived from the Greek word "myia" meaning fly.[1] It causes infestation of live human and vertebrate animals with dipterous larvae which, at least for a certain period, feed on the host's dead or living tissue, liquid body substances or ingested food.[2] Low socioeconomic status, immunocompromised state, mental retardation and unhygienic living conditions also may be the contributing factors responsible for myiasis.

CASE REPORT

A 43-years-old Nepalese female was admitted in the Department of ENT and Head and Neck Surgery, TU Teaching Hospital, Kathmandu with the complaints of foreign body sensation in the nose, nasal obstruction and purulent nasal discharge for two months. On examination, her vitals were normal. Anterior rhinoscopy revealed multiple maggots in her nasal cavity. Nasoendoscopy also revealed multiple maggots in the nasal cavity and nasopharynx. (Fig: 1, 2).

Figure 1

Fig: 1. Nasoendoscopy showing maggots in nasal cavity

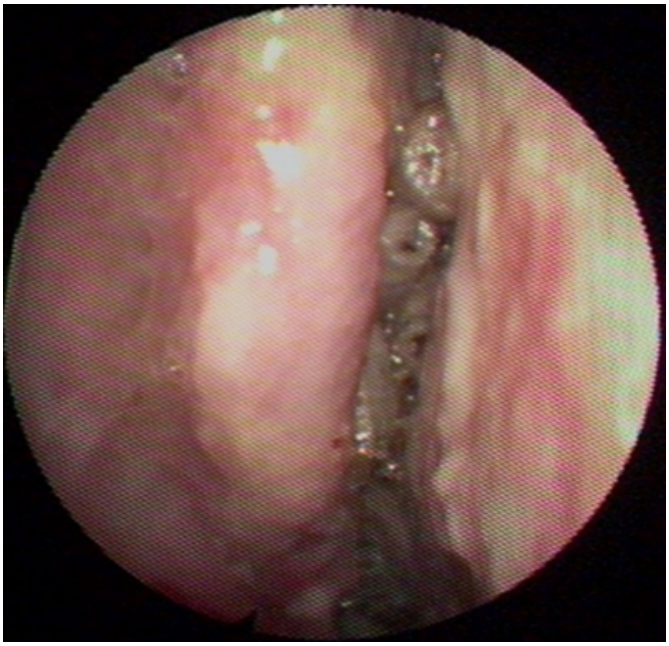

Figure 2

Fig: 2. Nasoendoscopy showing maggots in nasopharynx

Other ENT and head and neck examinations were normal. Routine blood investigations and serological profiles were normal. Patient was managed by instillation of turpentine oil into the nasal cavity and removing the maggots by suction and forceps. Multiple nasal irrigations were done with plenty of saline. She was treated with prophylactic oral antibiotics to prevent secondary infection. The patient had excellent recovery during two weeks of her hospital admission.

DISCUSSION

Myiasis is not an uncommon parasitic infestation in the tropics and subtropics, and due to international travel, cases are also encountered outside the endemic region in both Europe and North America.[3] Myiasis producing larvae attack three main parts of the body: cutaneous tissue (furuncular and creeping), body cavities, and body organs.[3, 4] Lesions with foul discharge or blood attract and stimulate the female insect to deposit eggs on them.[5]

However, larvae may burrow into and destroy the tissue. Rapid destruction of adjacent tissues, including bone, may result in the death of the host. Tissue destruction may occur by mechanical means and by the production of collagenase.[4]

Myiasis is also frequently seen in adults, especially those who are mentally retarded.[5] Our patient is a mentally competent, immunocompetent adult. The main symptoms of nasal myiasis are foreign body sensation and itching in throat, being followed by cough and then other various, respiratory and nasal manifestation such as nasal discharge, sneezing, laryngospasm, dyspnea and stridor.[6]

The diagnosis of myiasis is made by seeing the larval movement. Since the nasal cavity has inaccessible areas, removal of maggots can be difficult by conventional instrument and several settings are required. To overcome this problem, a nasal endoscope can be used for a direct vision.[7]

In our case, we removed more than 150 maggots from nose and nasopharynx. The patient was managed by irrigating the nasal cavity with turpentine and removing the maggots by suction and forceps. We also did the nasal irrigation several times with a large volume of saline. Besides, we also used oral antibiotics prophylactically to prevent secondary infection. The patient had excellent recovery in two weeks of hospital admission.

CONCLUSION

Although nasal myiasis is extremely uncommon in the field of otorhinolaryngology, especially in the western world, the possibility of its occurrence always exists. The treatment is simple and cure is rapidly obtained once the diagnosis is made.

References

1. Adhikari P, Sinha BK, Bhattarai H, Shrivastav RP. Myiasis in a postoperative mastoid cavity. Nepal Med Coll J 2007;9: 284-5.
2. Bhatt AP and Jayakrishnan A. Oral myiasis : a case report. Int J. Paediatr. Dent 2000; 10: 67-70.
3. Nouttsis C and Millikan LE. Myiasis. Dermatol Clin 1994;12: 729-36.
4. Ciftcioglu N, Altintas K, Haberal M. A case of human orotracheal myiasis caused by Wohlfahrtia magnifica. Parasitol Res 1997;83: 34-6.
5. Lokman Uzun, Fikret Cinar, Levent Bekir Bedir, Turan Aslan, Kursat Altintas. Radical mastoidectomy cavity myiasis caused by Wohlfahrtia magnifica. J Laryngol Otol 2004;118: 54-6.
6. Masoodi M, Hosseini K. The respiratory and allergic manifestations of human myiasis caused by larva sheep bot fly (Oestrus ovis): a report of 33 pharyngeal cases from southern Iran. Ann Trop Med Parasitol 2003;97: 75-81.
7. Erdinc Aydin, Sefika Uysal, Babur Akkuzu, Fusun Can. Nasal myiasis by fruit larvae: a case report. Eur Arch Otorhinolaryngol 2006;263: 1142-3.

Author Information

P. Adhikari, MS
Resident, Ganesh Man Singh Memorial Academy of ENT and Head and Neck Studies

B. Pradhan, MS
Professor and Unit Chief, Rhinology and Allergy, Ganesh Man Singh Memorial Academy of ENT and Head and Neck Studies

S. Khanal, MBBS
TU Teaching Hospital

S Khalilulla, MS
Resident, Ganesh Man Singh Memorial Academy of ENT and Head and Neck Studies