

Ileo-Uterine Fistula Complicating A Spontaneously Ruptured Pyometra - A Rare Case Report

H Bansal, R Jenaw, R Mandia

Citation

H Bansal, R Jenaw, R Mandia. *Ileo-Uterine Fistula Complicating A Spontaneously Ruptured Pyometra - A Rare Case Report*. The Internet Journal of Gynecology and Obstetrics. 2009 Volume 14 Number 2.

Abstract

Pyometra is a collection of pus in the uterine cavity. The incidence of pyometra in gynecological patients is 0.05-0.1% and in elderly patients 13.6%. This paper is aimed to report a case of ileo-uterine fistula complicating a pyometra. So far no literature is available to report this complication.

INTRODUCTION

The incidence of pyometra in gynecological patients is 0.05-0.1% and in elderly patients 13.6%. The prognosis of pyometra depends both on the underlying cause (e.g. malignancy) and on possibility of spontaneous perforation.

CASE REPORT

A 58 year old post menopausal female presented with complain of a colicky pain abdomen for 10 days, gradually progressive lower abdominal distension, decreased urine output for the last 10 days and no urine output for 1 day. The patient complained of multiple episodes of bilious vomiting and non passage of flatus and motion one day prior to admission. The patient had a past history of P/V whitish discharge 3months back which resolved after taking medication. There was no history of post menopausal bleeding.

On examination the pulse was 112, BP 110/70 mmHg and respiratory rate 24/min. On catheterization no urine came out. On abdominal examination, the lower abdomen was distended, tender and shifting dullness was present. Bowel sounds were absent. Per rectal examination was normal. Per vaginal examination revealed atrophic vagina, cervix could not be palpated and there was no discharge per vaginal.

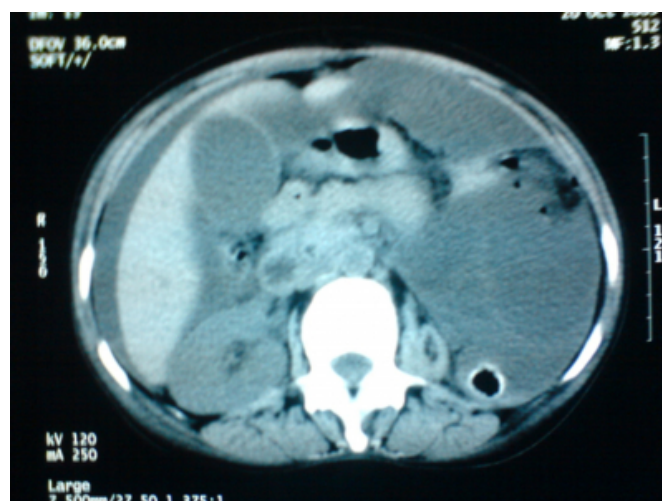Blood investigations revealed anemia (Hb-8gm %), TLC 9.1×10^3 per cubic mm and deranged Renal function tests [urea (95mg %) and creatinine (2.3mg %)]. X-ray FPA revealed multiple air fluid level suggestive of small bowel obstruction. Sonogram revealed a collection in the uterine cavity with an adnexal mass and gross ascites. Non contrast

C.T. abdomen revealed gross ascites, uterine collection and small left kidney [Fig.1.].

A provisional diagnosis of acute intestinal obstruction with pyometra with acute on chronic renal failure was made. The patient was managed conservatively initially. Continuous Ryle's tube suction was done; the patient was not allowed anything orally and was taken on intra venous antibiotics and fluids according to urine output. After appropriate investigations an Exploratory Laprotomy was planned.

Figure 1

Fig.1. C.T. Scan showing left atrophic kidney and massive free fluid

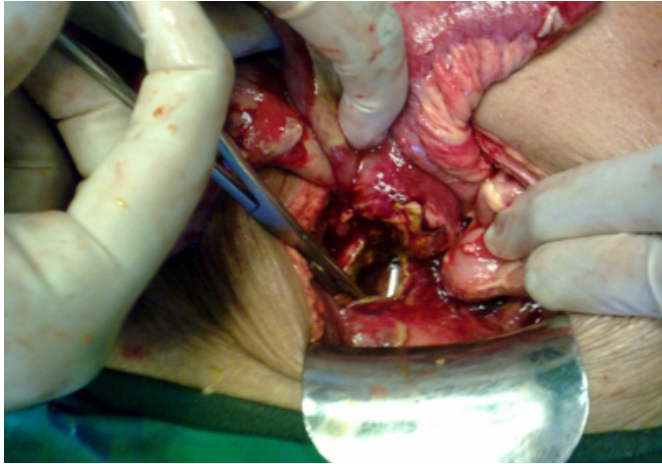


On opening up the abdomen, 2 litres of pus was drained. A fistula between terminal part of ileum and uterus was noted [Fig.2.]. Total abdominal hysterectomy and bilateral salpingo-oophorectomy with resection of involved ileal

segment with end ileostomy was performed. Post operative course was uneventful and the patient recovered from renal failure too. Histopathological examination revealed pyometra with chronic salpingo-oophritis.

Figure 2

Fig.2.Per-op picture showing Ileo-uterine fistula



DISCUSSION

Pyometra is the collection of pus in the uterine cavity and is mainly seen in post menopausal women. When correctly diagnosed, monitoring is warranted to detect persistent and recurrent disease [1]. Most common causes are senile endometritis, genital tract malignancy or due to effect of radiation. Other causes are benign tumors like leiomyoma, endometrial polyps, senile cervicitis, cervical occlusion after surgery, puerperal infections, and congenital cervical anomalies [2]. Classical triad of symptoms includes lower abdominal pain, purulent vaginal discharge and post menopausal bleed.

A spontaneous perforation of pyometra leading to diffuse peritonitis rarely occurs. Once ruptured, the symptoms become severe and acute abdomen often develops; it is therefore important to make a differential diagnosis from other causes of acute surgical abdomen [3].

Pneumoperitoneum associated with rupture is recognized in only 56% of the cases [4]. Ultrasound is the investigation of

choice for imaging. The uniform thick walled appearance of distended uterus and failure to identify uterus as separate structure differentiates it from pelvic abscess.

Management includes repeated dilatations of cervix and drainage using Foley's catheter or drainage tube under antibiotic cover. Passage of a sound or a dilator releases a flow of pus which is often blood stained. It is appropriate to avoid curettage while draining pyometra for fear of perforation. When cause of pyometra is malignant management is as per case. Persistent pyometra indicates need for hysterectomy and bilateral salpingo-oophorectomy [5]. Prompt recognition and treatment improves the prognosis considerably.

Very few cases of spontaneous rupture of pyometra have been reported [6]. This is the first case of an ileo uterine fistula complicating a ruptured pyometra to be reported. Pyometra is an unusual cause of peritonitis, but it must be considered as a possible diagnosis in elderly women presenting with an acute abdomen [7].

References

1. Saha PK, Gupta P, Mehra R, Goel P, Huria A. Spontaneous perforation of pyometra presented as an acute abdomen : A case report. *Medscape J Med.*2008;10(1): 15.
2. Begum Y,Esra U,Alper S,Gulfem G,Zehar K.Spontaneous perforation of pyometra : a case report. *Infect Dis Obstet and Gynecol.*2006;26786:1-3.doi 10.1155/IDOG/2006/26786.
3. Loabat G,Mohsen F,Behnam S. Spontaneous uterine perforation due to Pyometra presenting as acute abdomen. *Infect Dis Obstet Gynecol.*2006;60276:1-2.doi 10.1155/IDOG/200660276.
4. Dalal S, Rohilla P, Garg P. Spontaneous rupture of pyometra - A rare cause of acute abdomen in elderly female.The Internet J of Gynecology and obstetrics.2009 Volume12 Number1.
5. Chao-Hsu L, Chang WC. Spontaneous perforated pyometra with an intrauterine device in menopause - a case report. *Jpn J Infect Dis* :2008;61,471-478.
6. Jhobta RS, Sharma D, Jhobta A, Minhas SS. Spontaneous rupture of pyometra - A rare cause of peritonitis. *Journal of Pelvic Medicine & Surgery.* Sep/Oct(2006), volume12(5):267-268.
7. Inui A,Nitta A,Yamamoto A,Kang S,Kanehara I,Tanaka H,Nakumara S et al. Generalized peritonitis with pneumoperitoneum caused by the spontaneous perforation of pyometra without malignancy : Report of a case. *Surgery today.* Jpn J Surg.1999;29:935-938. Doi 10.1007/BF02482791.

Author Information

Hanish Bansal

Post graduate student (3rd year), Department of General Surgery, Surgical Unit 4, S.M.S Medical College

Raj Kamal Jenaw

Professor and Unit Head, Department of General Surgery, Surgical Unit 4, S.M.S Medical College

Rajendra Mandia

Associate Professor, Department of General Surgery, Surgical Unit 4, S.M.S Medical College