

# Mirror Hand Deformity - A Rare Congenital Anomaly Of The Upper Limb

S Rabah, S Salati, S Wani

## Citation

S Rabah, S Salati, S Wani. *Mirror Hand Deformity - A Rare Congenital Anomaly Of The Upper Limb*. The Internet Journal of Surgery. 2008 Volume 21 Number 1.

## Abstract

Mirror hand deformity is a very rare congenital disorder. We report a case of a two-year-old child suffering from this disorder, which is being managed in the Department of Plastic & Reconstructive Surgery of King Fahad Medical City, Riyadh, Saudi Arabia.

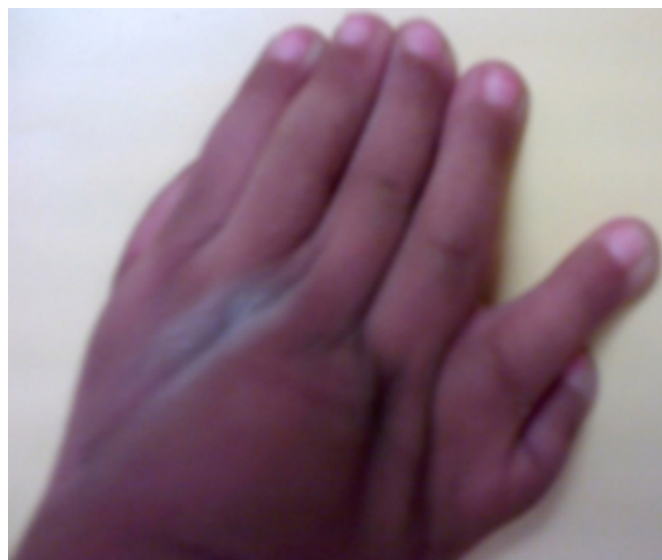## CASE PRESENTATION

This two-year-old male was referred to our center from a peripheral center for management of his congenitally deformed right upper limb. He is the product of a non-consanguineous marriage, first in birth order, with uneventful perinatal history. There is no family history of congenital disorders. Examination revealed a normal baby boy without any other anomalies apart from the deformed right upper limb. There is hypoplasia of right arm and forearm and the right hand has seven fingers and an absent thumb. There is loss of the normal contour of the right shoulder, with prominence of the tip of the acromion; all shoulder movements are grossly restricted, especially abduction, with the humeral head being felt in the axilla lying against the ribs. Flexion of the elbow and supination/pronation of forearm are limited to 40° and 10° respectively. The wrist is radially deviated but the range of movements is within acceptable limits. Radiographs of the affected limb revealed a hypoplastic right scapula with no clear glenoid margins and inferior dislocation of the humeral head. The forearm has an absent radius and two ulnae. The carpus has five bones and the hand bears seven triphalangeal digits and each digit has a corresponding metacarpal. After thorough evaluation, the patient has been planned to undergo multi-stage operations in form of soft-tissue distraction at the wrist joint to correct the radially deviated joint, excision of the radial two digits and creation of a thumb through pollicisation of one of the radial digits. At the elbow, excision of part of the upper end of one of the ulnae will be required to improve supination/pronation. These operations are planned to be finished before school age for better results and function and to prevent the psychological impact of such

deformity on the patient.

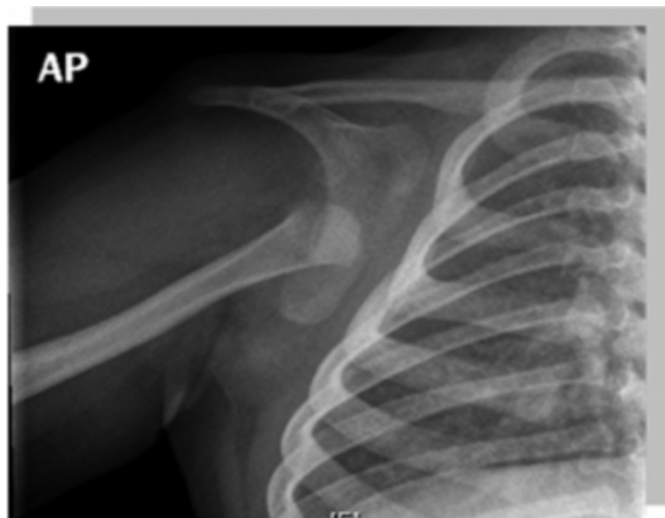
## Figure 1

1. Right hand with seven fingers and absent thumb



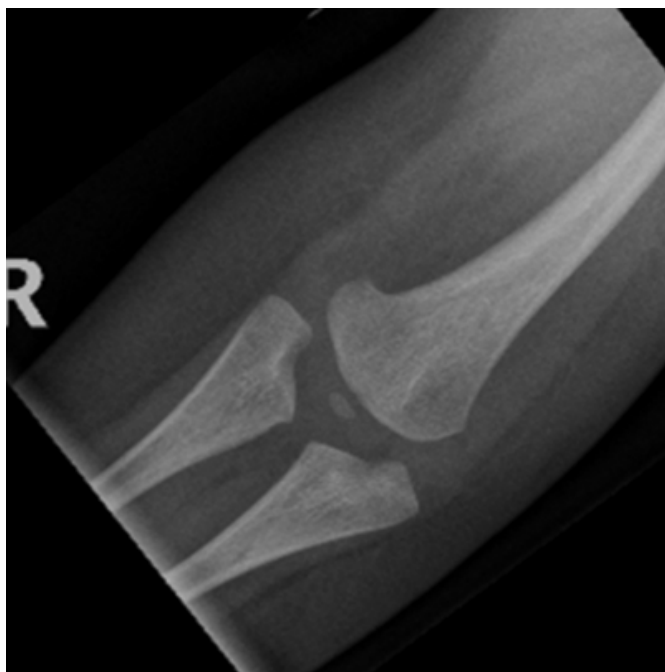
**Figure 2**

2. Right shoulder dislocation with hypoplastic scapula.



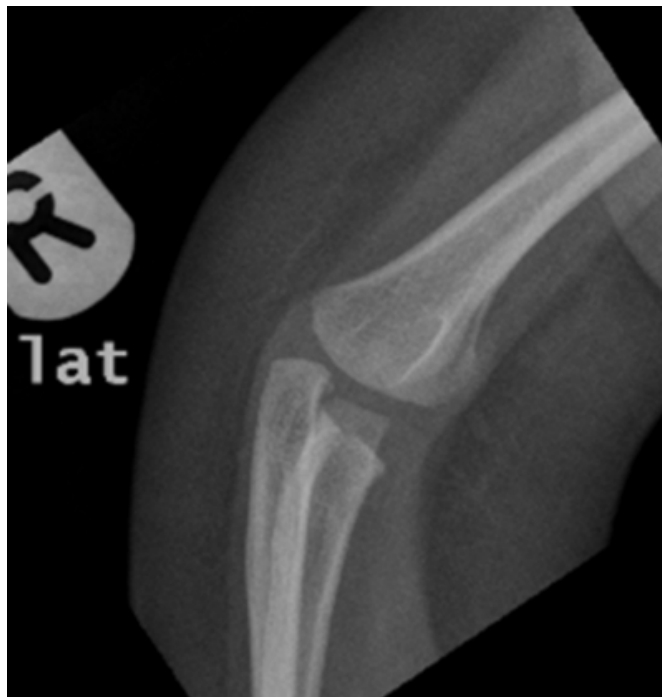
**Figure 3**

3. Right elbow joint with ulnar dimelia with each of the duplicated ulnae articulating with the distal humerus separately and tending to face each other. There is no capitulum on the distal humerus.



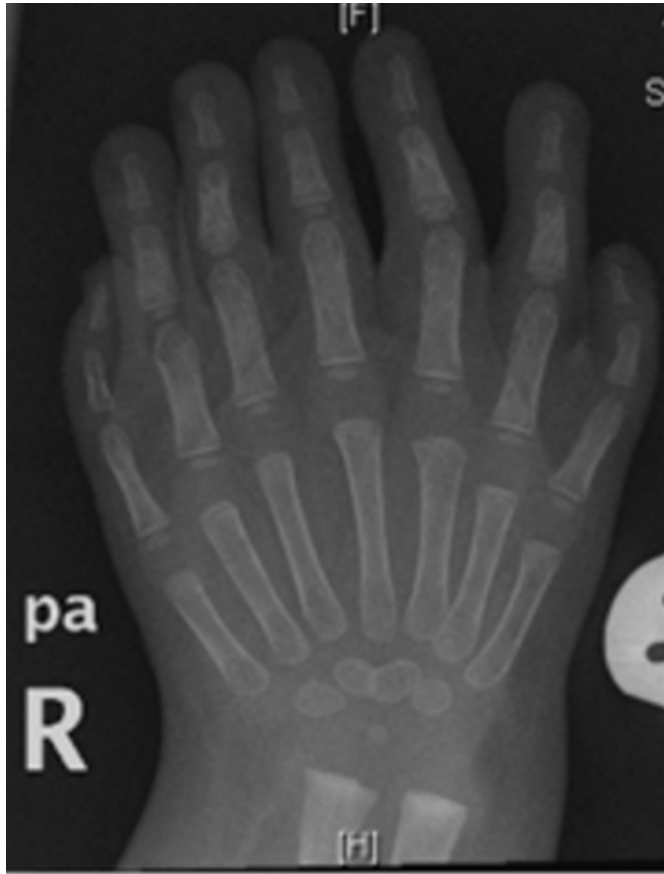**Figure 4**

4. Lateral view of right elbow showing two ulnae



**Figure 5**

5. Right hand with seven triphalangeal fingers. Ulna and ulnar carpal bones are duplicated with replacement of scaphoid and trapezium. The distal ulnar epiphyses are broadened.



### DISCUSSION

Mirror hand deformity, also known as ulnar dimelia is an extremely rare congenital anomaly of the upper limb with only 70 cases reported in literature.<sup>1</sup> This condition is characterized by duplication of the ulna. There is no radius and the ulna is symmetrically duplicated around a central digital axis producing seven or eight digits. Our patient has two ulna bones and seven fingers on the right hand. Anatomically the carpus appears symmetrical with a large lunate surrounded by triquetrals on either side. There are two capitates and two extensor tendons to the central digit. The ulnar nerve is also duplicated. Arterial supply is through a lateral vessel supplying the radial two and a half digits and a medial vessel supplying the ulnar four and a half digits.<sup>2,3</sup>

The embryology of this disorder was first explained by Saunders and Gasseling<sup>4</sup> who were able to produce mirror image duplications in chicken by grafting a small portion of posterior border mesoderm into an anterior portion. This is regarded as a zone of polarizing activity (ZPA) and is

considered to be responsible for limb patterning on an anteroposterior axis. This is regulated by a gene named as sonic hedgehog (shh) gene. Ectopic expression of the ZPA cells or the sonic hedgehog (shh) gene can result in mirror image deformities. More recently, secondary signaling molecules such as bone morphogenic proteins and certain Hox genes have been implicated in the embryogenesis of mirror image deformities. Hox genes encode positional information during embryogenesis. Hox b-8 is thought to be important in the specification of the ZPA cell positioning, the ectopic expression of which has been experimentally shown to result in mirror image duplication.<sup>5-7</sup> Retinoids have been shown to regulate the expression of Hox genes<sup>6</sup> to some extent.

In the literature, different variants of mirror hand deformity have been reported. Al-Qattan and Al-Thunayan<sup>8</sup> have proposed a classification of mirror hand deformity based on presence/absence of other congenital anomalies and the type of forearm bones present in a particular patient. Accordingly, a patient will be classified as Type 1 if there is ulnar dimelia, Type 2 if there are two ulnae and one radius, Type 3 if there is one radius and one ulna, Type 4 if there are associated anomalies (syndromic) and Type 5 if there are multiple hands on a single limb. Our case has two fully developed ulnae and hence can be categorized under Type 1 class of mirror hand deformities.

The management of this disorder is directed at achieving a functional and aesthetic upper limb and involves multiple complex operations. The stiffness of the shoulder, elbow and wrist is very difficult to treat and remains a major problem whereas excision of excess digits and pollicisation is now an established and successful means of treating the hand deformity.<sup>9-10</sup>

### References

1. Schmitt P, Guéro S, Brunelle F. Ulnar dimelia: imaging modalities and surgical implications. *J Radiol* 2000;81(3):219-22.
2. Mark T. Jobe and Phillip E. Wright II. Congenital Anomalies of Hand. In: Canale T (editor), *Campbell's Operative Orthopaedics*, 9th. Ed., 1998; Vol.4: p.3792.
3. Muteti EN, Carter LL. Mirror hand – ulnar dimelia. A case report. *ECAJS* 2007;12(2):88-91.
4. Saunders JW, Gasseling MT. Ectodermal–Mesenchymal Interactions in the Origin of Limb Symmetry. In: R. Fleishnager and R. E. Billingham (eds.), *Epithelial–Mesenchymal Interactions*. Baltimore: Williams & Wilkins, 1968: p.78-97.
5. Viljoen DL, Kidson SH. Mirror polydactyly: Pathogenesis based on a morphogen gradient theory. *Am J Med Genet* 1990;35:229.
6. Hatchwell E, Dennis N. Mirror hands and feet: A further

case of Laurin-Sandrow syndrome. J Med Genet 1996;33:426.

7. Tsuyuguchi Y, Tada K, Yonenobu K. Mirror hand anomaly – reconstruction of the thumb, wrist, forearm and elbow. 1982;70(3):384-7.

8. Al-Qattan MM, Al-Thunayan A, De Cordier M, Nandagopal N, Pitkanen J. Classification of the mirror hand: Multiple hand spectrum. J Hand Surg (Br)

1998;23(4):534-36.

9. Irani Y, Salazard B, Jouve JL. Ulnar dimelia – management of a rare malformation. Rev Chir Orthop Reparatrice Appar Mot 2008;94(2):174-78.

10. Yang SS, Jackson L, Green DW, Weiland AJ. A rare variant of mirror hand – a case report. J Hand Surg (Am) 1996;21(6):1048-51.

**Author Information**

**Sari Rabah, MBBS, FRCS(C)**

Consultant, Department of Plastic & Reconstructive Surgery, King Fahad Medical City

**Sajad Salati, MBBS, MS, MRCS**

Assistant Consultant, Department of Plastic & Reconstructive Surgery, King Fahad Medical City

**Shabeer Wani, MBBS, MS, Mch**

Assistant Consultant, Department of Plastic & Reconstructive Surgery, King Fahad Medical City