

Primary Osteogenic Sarcoma of Skull Bone-A rare clinical presentation

S Gupta, S Chitra, D Singh

Citation

S Gupta, S Chitra, D Singh. *Primary Osteogenic Sarcoma of Skull Bone-A rare clinical presentation*. The Internet Journal of Oncology. 2008 Volume 6 Number 2.

Abstract

Primary osteogenic sarcoma of skull is a rare entity constituting 2% of all osteogenic sarcomas. These tumors develop most often in bones of the arms, legs, or pelvis. . It is rare during middle age, and is more common in males than females. We here present a rare case of skull bone osteogenic sarcoma. 19 year male presented with swelling left parietal region .Biopsy revealed osteogenic sarcoma. He underwent wide local excision and then received adjuvant chemotherapy, but had recurrence at same site. Patient was reoperated ,wide excision of temporoparietal bony mass and cranioplasty with methylacrylate was done. Post operatively he received adjuvant External beam Radiotherapy.

INTRODUCTION

Osteosarcoma (also called osteogenic sarcoma) is the most common primary bone cancer. It produces osteoid or bony matrix and usually affects metaphysis of long bones. It most often occurs in young people between the age of 10 and 30, but about 10% of osteosarcoma cases develop in people in their 60s and 70s. It is rare during middle age, and is more common in males than females. These tumors develop most often in bones of the arms, legs, or pelvis. It rarely affects skull, constituting 2% of all osteogenic sarcomas.

Most tumours are solitary, around 2% are multifocal (2 or more bones). It is known that osteosarcoma can be radiation induced. Osteosarcomas vary greatly in radiological and pathological features and therefore needs careful diagnosis to differentiate this from other bone tumours. Most are high grade intramedullary osteosarcomas, about 5% are low grade lesions, some are secondary osteosarcomas (for example those caused by radiation therapy).

As osteogenic sarcoma of skull are considered to be rare, we present a case of recurrent osteogenic sarcoma of left parietal bone.

CASE REPORT

A 19 year old male presented with complaints of swelling on left side head since 8 months and pain in swelling for 3 months. On local examination 8x10 cm, firm to

hard, tender, fixed swelling was present on left parieto-

occipital region without any neurological deficit.. Biopsy of the swelling showed osteogenic sarcoma with chondroid areas. CEMRI brain revealed a mass arising from left parietal bone with no intracranial extension. Bone scan revealed increased uptake in the left temporoparietal region.

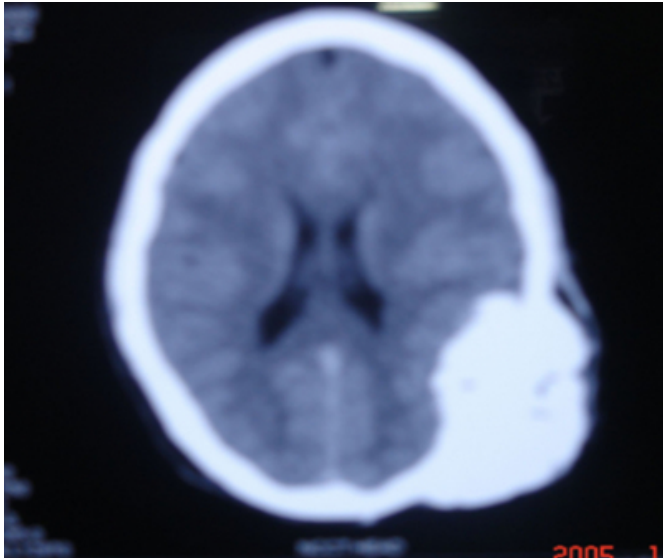
Removal of the mass was done by partial drilling of outer table of skull. Histopathology confirmed it to be osteogenic sarcoma with chondroid areas.

Postoperatively the patient was started on adjuvant chemotherapy (Cisplatin 150mg, Adriamycin 90mg). He received 4 cycles of chemotherapy .

There was reappearance of swelling at the same site (left parietal region) after fourth cycle of chemotherapy . CECT brain revealed a mass arising from left parietal bone without any intracranial extension (Fig:1)

Figure 1

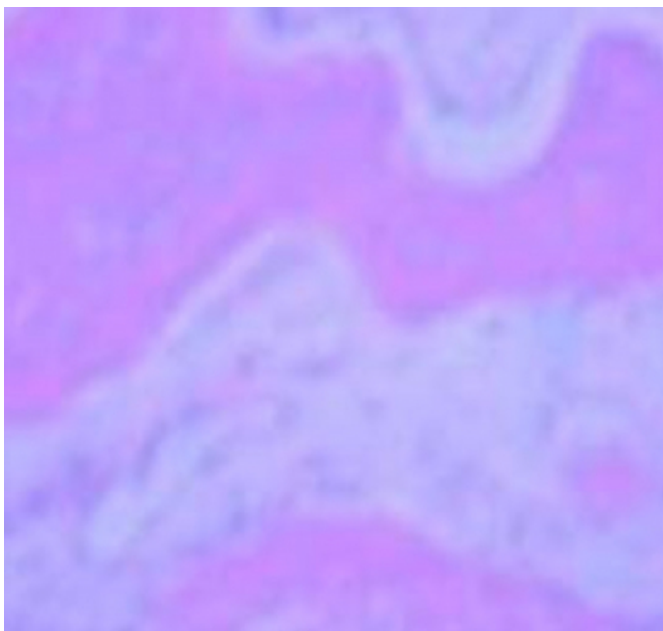
Figure 1:CECT Brain showing a mass arising from left parietal bone



The patient was reoperated ,wide excision of temporoparietal bony mass and cranioplasty with methylacrylate was done. HPE (Fig:2)showed osteogenic sarcoma left parietal bone, reaching up to one of the surgical margin.

Figure 2

Figure 2: Histopathologic slide showing new bone formation with osteoblast,consistent with osteogenic sarcoma



In view of histopathological findings the patient had received adjuvant External Radiotherapy 60Gy/30fr by tangential portals. It will be followed by adjuvant chemotherapy.

DISCUSSION

These tumours occur more commonly in older children and teenagers, and are very rarely seen in children under five. Osteogenic sarcoma is largely a disease of the young but about one-third occurs in patients over 40 years of age They are more common in boys than girls^[1]. It has predilection for the metaphyseal region of the long bones Any bone in the body can be affected, but the most common sites are the arms or legs, particularly around the knee joint^[2] The incidence of primary osteogenic sarcomas of the skull is about 1 to 2% of all skull tumors.^[3]

There are several different types of osteosarcoma.,such as parosteal^[4], periosteal telangiectatic, and small cell osteosarcoma. At the time of diagnosis 15-20% of patients have detectable metastases that have spread to the lungs or other bones. The exact cause of osteosarcoma is unknown and cannot be prevented because it is associated with random genetic mutations or changes of the bone forming cells (osteoblasts).. Risk Factors include prior irradiation or chemotherapy:, particularly alkylating agents, is also associated with secondary osteosarcomas, and may potentiate the effect of previous radiation.,Paget`s disease and other benign bone lesions such as osteochondroma, enchondroma, chronic osteomyelitis, multiple hereditary exostoses, fibrous dysplasia, sites of bone infarcts, and sites of metallic implants for benign conditions.^[5] Genetic conditions with a known predisposition to osteosarcoma include hereditary retinoblastoma, Li-Fraumeni syndrome, Rothmund-Thomson syndrome, and the related Bloom and Werner syndromes.

Clinical features are localized pain that frequently begins after an injury and waxes and wanes over time.. The most important finding on physical examination is a soft tissue mass, which is frequently large and tender to palpation. Laboratory evaluation is usually normal, except for elevations in alkaline phosphatase, lactate dehydrogenase, and erythrocyte sedimentation rate. At the time of presentation, between 10 and 20 percent of patients have demonstrable macrometastatic disease.

Radiological investigations include,MRI of the entire length of the involved long bone. -CT scans are best suited to evaluate the thorax for metastatic disease, Radionuclide bone scanning with technetium is the preferred method for evaluating the entire skeleton Although a PET scan may have greater utility for assessing the response to preoperative chemotherapy, at least one study suggests it is inferior to

radionuclide bone scanning for the detection of osseous metastases from osteosarcoma, and to spiral CT for detecting pulmonary metastases.

No radiographic finding is pathognomonic. Biopsy is required for definitive diagnosis.

Osteosarcoma treatment has progressed greatly over the past thirty years. The standard treatment for patients with conventional osteosarcoma consists of the combination of chemotherapy and surgery, and in some cases radiation^[6].

If a cure is to be achieved, surgical removal of all the tumor tissue at any site should always be attempted. Complete surgery is the treatment of choice for osteosarcoma^[7]. In selected cases, however, radiotherapy has proven helpful^[8]. In general, recommended dosages are:

- 56-62 Gy in 2 Gy fractions where margins are microscopically involved.
- 64-70 Gy where macroscopic tumor tissue is left behind
- 70 or more Gy for inoperable osteosarcoma

With current treatment regimens combining chemotherapy and surgery, osteosarcoma patients without detectable

metastases have a survival rate that approaches 70%. Factors that seem to negatively impact prognosis include, presence of metastases. Patients with lung metastases that are removable at diagnosis have about a 30-50% survival rate, large tumor size, poor response to chemotherapy.

Recurrence of osteosarcoma is the most common cause of treatment failure.

References

1. Huvos AG. Bone Tumours. Diagnosis. Treatment and Prognosis. Philadelphia: WB Saunders; 1991, pp 192-193.
2. Skubitz KM, D'Adamo D. Sarcoma. Mayo Clin Proc. 2007; pp1409-1432
3. L. Mascarenhas, A. Peteiro, C. A. Ribeiro, Z. Magalhães, H. Romão F. Magalhães, A. M. Reis, J. Resende Pereira, M. Honavar, M. Resende, A. Rocha Vaz, Skull osteosarcoma: illustrated review, Acta Neurochirurgica, Volume 146, Issue 11, Nov 2004, pp 1235 – 1239
4. R Kumar, RP Moser Jr, JE Madewell and J Edeiken, Parosteal osteogenic sarcoma arising in cranial bones: clinical and radiologic features in eight patients, American Journal of Roentgenology, 1990 Vol 155, pp113-117
5. Caroline Caramella, Thomas Roujeau, Jean-Luc Drapé, Krasimir Minkin, Claire Krainik, André Kahan and Yannick Allanore Joint Bone Spine, Volume 73, Issue 4, July 2006, pp 459-461
6. Fukunaga, Low-grade central osteosarcoma of the skull. Pathol Res Pract. 2005;201(2):131-5.
7. Primary osteogenic sarcoma of skull, Bikash Bose Surg Neurol. ;58 (3-4): 234-9; discussion 239-40
8. . Sunderasan N, Huvog AG, Rosen G. Combined modality treatment of osteogenic sarcoma of the skull. J Neurosurg 1980; 63:562-567

Author Information

Sweety Gupta, M.D.

Clinical Assistant, Department of Radiation Oncology, Galaxy Cancer Institute, Pushpanjali Crosslay Hospital Ghaziabad (U.P.)

S. Chitra, B.Sc, DRP

Chief Physicist, Department of Radiation Oncology, Galaxy Cancer Institute, Pushpanjali Crosslay Hospital Ghaziabad (U.P.)

Dinesh Singh, M.D.

Senior Consultant, Department of Radiation Oncology, Galaxy Cancer Institute, Pushpanjali Crosslay Hospital Ghaziabad (U.P.)