

Liposarcoma Of The Spermatic Cord: Report Of Two Cases And Review Of The Literature

B Maximilian, T Joachim, M Sebastian

Citation

B Maximilian, T Joachim, M Sebastian. *Liposarcoma Of The Spermatic Cord: Report Of Two Cases And Review Of The Literature*. The Internet Journal of Urology. 2004 Volume 3 Number 1.

Abstract

Liposarcoma of the spermatic cord is rare. We present two cases and review the literature. A 61 years old man presented with the clinical impression of an inguinal hernia; a 75 years old man presented with a painless scrotal mass. Histology revealed liposarcoma of the seminal cord in both cases.

INTRODUCTION

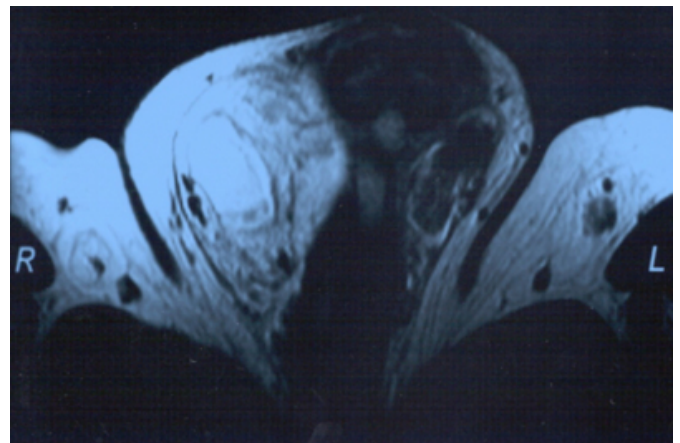
The liposarcoma of the spermatic cord is a rare condition, representing about 7% of paratesticular sarcomas^[1]. No studies containing greater numbers have been published on this issue. We report two cases and review the literature.

CASE 1

A 61 year old patient presented with the clinical impression of a right-sided inguinal hernia. Gradual enlargement of this painless scrotal mass during the previous three years was reported. On examination a painless scrotal mass adjacent to the external inguinal ring but separated from the normal testis and epididymis was palpated. On ultrasound examination this scrotal mass was hyperechogenic and inhomogeneous and separated from the testis and epididymis, which showed no pathological finding. MRI was performed and findings were interpreted as an inguinal hernia containing peritoneal fat protruding into the scrotum. No malignancy was suspected (fig. 1).

Figure 1

Figure 1: MRI interpreted as an inguinal hernia containing peritoneal fat.



However during surgery a lipomatous mass was found, that could not be separated from the right seminal cord. Frozen section revealed a malignant tumour. Wide excision and radical orchiectomy were performed. Definite histology revealed a sclerosing and partially dedifferentiated liposarcoma of the seminal cord (Coindre-grade II, WHO-grade III) with a diameter of ca. 14 cm. Due to close resection margins a wider local excision, inguinal lymphadenectomy and hemiscrotectomy were performed. Histology revealed small formations of the liposarcoma in the resected inguinal lipomatous tissue, the resection-margins and lymph- nodes were tumour- free.

Adjuvant radiotherapy was initiated and fractionated doses of 2 to 60 Gy were applied to the right inguinal region and the total scrotum. Radiation was tolerated well and after

eighteen months of follow- up no signs of tumour- progression are evident.

CASE 2

A 75 years old man presented with a painless scrotal mass, which reportedly had increased in size over the previous four months. On examination a solid mass measuring ca. 3 cm. in diameter of the left epididymal region was found. Ultrasound imaging showed a hyperechogenic and homogenous elliptic mass detached from the left epididymis of 3.5 cm. in diameter.

An inguinal exploration of the left testis was performed and intraoperative frozen section reported a sarcoma. Thus radical orchiectomy was performed. Final histological evaluation revealed a pleomorphic liposarcoma of the seminal cord (Coindre-grade II, WHO-grade III) with a max. diameter of 5 cm. A 0.5 cm wide pseudo- capsule consisting of benign stromal tissue surrounded the tumour. No infiltration into the testis or epididymis is noted. All resection margins were negative. Since a complete surgical resection of the liposarcoma with wide margins of 2 cm. was achieved, no adjuvant radiotherapy was necessary for this case. After 3 months of follow- up so far the patient does not show evidence of tumour-progression.

DISCUSSION

As paratesticular malignancies and sarcomas of the seminal cord are in general, liposarcomas of the seminal cord are rare. The first case of a spermatic cord sarcoma was reported in 1845 by Lesauvage[₂]. The vast majority, ca. 80%, of seminal cord tumors are benign and mostly derive from lipomatous tissue. Most paratesticular malignant tumours are sarcomas. Despite the fact, that lipomas are the predominant benign tumours found in the inguinal region, lipomatous tissue plays a minor role in seminal cord malignancies, comprising only approximately 5 % to 7 % of all spermatic cord sarcomas. It is hypothesised that a mesenchymal origin rather than malignant transformation of lipomatous cells lead to liposarcomas. There are only two series with small numbers reported in the literature[_{3,4}]. Thus therapeutical experience is fairly small and some issues remain unsolved.

Most patients present with a scrotal mass, that is usually not associated with any inguinal complaints and increases in size rather slowly over a period of months or years. Liposarcoma is a disease of the older age group[₅]. No specific diagnostic procedures for evaluating this scrotal mass have been recommended so far. In contrast to testicular masses,

ultrasonography provides little information on paratesticular sarcomas, as some are visualized as homogenous and isoechogenic, others as inhomogeneous and echo- density is quite variable. The use of CT- scans is not widely reported, but seems to be promising, as liposarcomas are of low density and can be well demarcated, but no pathognomonic features for the differentiation of benign versus malignant masses are defined[₆]. Use of MRI provides good information on the local situation, but an exact evaluation of any masses again cannot be obtained, as our case reported above is demonstrating.

According to the general guidelines of sarcoma therapy, a radical surgical excision of any tumour is necessary. The inguinal radical orchiectomy is the standard approach for sarcomas of the seminal cord in general with wide resection margins[₇]. However the anatomical features of the inguinal region sometimes make it difficult to achieve this goal, and negative resection margins are sometimes close to the tumour. Some authors favour a hemiscrotectomy in addition to the inguinal orchiectomy[₈]. Catton advises a second resection, if the margins are positive, with frozen section not being entirely reliable[₉]. Local radical excision alone seems to be insufficient for liposarcomas, since local recurrence is a major problem, occurring in up to 50 % of the patients[_{8,10,11}]. No sufficient data on the general risk factor for local recurrence is available. However it is established for liposarcomas of the extremities, that the level of differentiation and the histological sarcoma type, as well as the tumour- size have little influence on recurrence- rate. In contrast the resection status has an impact on local recurrence[₁₂]. Since a negative resection status can rarely be ensured in the inguinal region, some authors recommend adjuvant radiation[_{4,10,11}]. Due to the radiosensitivity of liposarcomas, this approach seems to be quite feasible[₃]. Radiation- dose should be 60 Gy over 6 weeks and the radiation- field should cover the internal inguinal ring[₄].

Due to their relative resistance against chemotherapy, a routine adjuvant systemic therapy is not justified in lipo- or any other seminal cord sarcoma[₉]. In contrast to other sarcomas of the seminal cord, metastatic disease of liposarcomas has not been reported[₃].

No specific outcome- data are available for liposarcoma patients due to the rareness of this disease. A series of 32 seminal cord sarcoma patients reports a 15 years overall survival rate of 52 %. The 10- years local control- rate for the 8 patients with liposarcoma included in this series was

44 %_[4].

As late recurrence can occur, follow-up examinations exceed 10 years_[10].

CONCLUSION

Liposarcomas of the seminal cord are rare. Therapy should include a radical surgical excision usually administered by radical inguinal orchiectomy, and mandatory second resection and hemiscrotectomy in cases of unclear resection margins is feasible. If the margin- status is in doubt, adjuvant radiation should be performed. Distant disease has not been reported, but local relapse is common and may occur several years after primary therapy. Thus follow-up periods have to be of sufficient duration.

References

1. Sogani PC, Grabstald H, Withmore WJ: Spermatic cord sarcoma in adults. *J Urol* 1978, 120:301
2. Hinman F, Gibson TE: Tumors of the epididymis, spermatic cord and testicular tunics: a review of literature and report of three new cases. *Arch Surg*, 1924;8: 100
3. Schwartz SL, Swierzewski SJ 3rd, Sondak, VK, Grossmann HB: Liposarcoma of the spermatic cord: report of 6 cases and review of the literature. *J Urol* 1995, 153:154-7
4. Ballo MT, Zagars GK, Pisters PW, Feig BW, Patel SR, von Eschenbach AC: Spermatic cord sarcoma: outcome, patterns of failure and management. *J Urol* 2001, 166:1306-10
5. Richie JP: Neoplasmas of the testis. In: Walsh PC, Retik AB, Stamey TA, Vaughan ED (eds.) *Campbell's Urology*, 7th edn., vol.2, Saunders, Philadelphia London Toronto. 1999: 2411-52
6. Cardenosa G, Papinicolaou W, Fung CY, Tung GA, Yoder IC, Althausen AF, Shipley WU: Spermatic cord sarcomas: sonographic and CT-features. *Urol Rad* 1990, 12:136
7. Wilson N, Davis A, Bell R, Wilson AN, Davis A, Bell RS, O'Sullivan B, Catton C, Madadi F, Kandel R, Fornasier VL: Local control of soft tissue sarcoma of the extremity: the experience of a multidisciplinary sarcoma group with definitive surgery and radiotherapy. *Eur J Cancer* 1994 , 30:746
8. Blitzer PH, Dosoretz DE, Proppe KH: Treatment of malignant tumors of the spermatic cord: a study of 10 cases and a review of the literature. *J Urol* 1981, 126:611-4
9. Catton C, Jewett M, O'Sullivan B, Kandel R. Paratesticular sarcoma: failure patterns and definitive local therapy: *J Urol* 1999, 161:1844-7
10. Fagundes MA, Zietman AL, Althausen AF: The management of spermatic cord sarcoma. *Cancer* 1996, 77:1873
11. Catton C, Cummings BJ, Fornasier V: Adult paratesticular sarcoma: a review of 21 cases. *J Urol* 1991, 146:342
12. Pisters PW, Leung DH, Woodruff J: Analysis of prognostic factors in 1.041 patients with localized soft-tissue sarcomas of the extremities. *J Clin Oncol* 1996,14:1679

Author Information

Burger Maximilian, M.D.

Dept. of Urology, University of Regensburg

Thüroff Joachim

Professor of Urology, Dept. of Urology, University of Mainz

Melchior Sebastian

Professor of Urology, Dept. of Urology, University of Mainz