

Management Of Left-sided Double Lumen Tube Placement Using A Video-optical Intubation Stylet

M Weiss, K Kern, A Gerber

Citation

M Weiss, K Kern, A Gerber. *Management Of Left-sided Double Lumen Tube Placement Using A Video-optical Intubation Stylet*. The Internet Journal of Anesthesiology. 1998 Volume 3 Number 3.

Abstract

We report the successful use of a video-optical intubation stylet for left-sided double-lumen tube placement in a 13 year old girl. An ultrathin video-optical intubation stylet has been inserted into the bronchial lumen of a left-sided 28 Ch double-lumen tube before starting anesthesia. The trachea was intubated under direct vision using conventional laryngoscopy and the video-view from the stylet tip was used to direct and to place the bronchial tube correctly in the left mainstem bronchus. Then the video-optical intubation stylet was inserted into the tracheal lumen to confirm and adjust the proximal margin of the bronchial cuff. During one-lung ventilation, the video-optical intubation stylet was reinserted into the tracheal lumen to monitor continuously the position of the endobronchial cuff.

The technique allowed visualized left-sided DLT insertion control in a simple and safe manner with correct DLT placement at the first attempt. Continuous visual subglottic airway monitoring was a valuable aid for maintaining correct double-lumen tube position during one-lung ventilation and may allows early detection and correction of tube dislocation. In addition, it provided an useful teaching and supervising tool.

Please check the Web Site of Video-Assisted Airway Management at <http://www.vaama.net>

INTRODUCTION

The most commonly used technique for lung isolation for thoracic surgery involves placement of a left-sided double lumen endobronchial tube (DLT). (1,2)

In the traditional, blind approach the tip of the DLT is placed through the larynx under direct vision, then the whole tube is rotated 90 degrees and advanced blindly into the left mainstem bronchus.(2,3) Classically, sequences of cuff inflations, alternate lumen clampings and auscultation are used to ensure correct placement of the DLT.(2,4)

Malpositioned double-lumen tubes have been reported to be found at bronchoscopy in 37-78 % of cases in which auscultatory findings suggested correct placement.(5,6) Therefore, routine use of the fiberoptic bronchoscope (FOB) to confirm correct double-lumen tube position has been strongly advocated.(5,7,8,9)

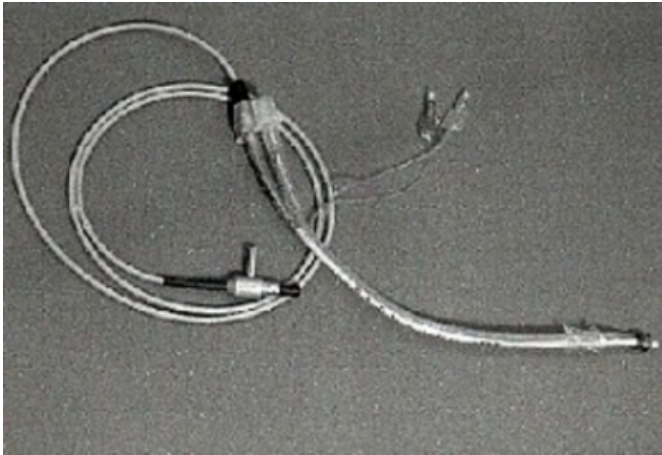
We describe a new method and it's successful use for visualized left-sided double-lumen tube placement using a video-optical intubation stylet (VOIS).(10)

TECHNIQUE

An ultrathin, pediatric video-optical intubation stylet is inserted into the bronchial lumen of a left-sided DLT and attached to a video-monitor system (Fig. 1).(11,12) It transmits the view from the bronchial tube tip directly onto the bedside video-monitor. Flowing oxygen at the stylet tip protects the lens against fogging and secretions and provides apnoic oxygenation during intubation.

Figure 1

Fig 1: Ultrathin video-optical intubation stylet inserted in the bronchial lumen of a left-sided double-lumen tube



Conventional laryngoscopy is performed as usual. The bronchial tip is placed through the larynx under direct vision (Fig 2A). Subglottic DLT position is confirmed on the monitor before further manipulations. Then the DLT is rotated 90 degrees and advanced down the trachea to the carina under visual control (Fig. 2B). At the level of the carina the bronchial tip is directed into the left mainstem bronchus and advanced the appropriate distance.

Figure 2

Fig. 2A

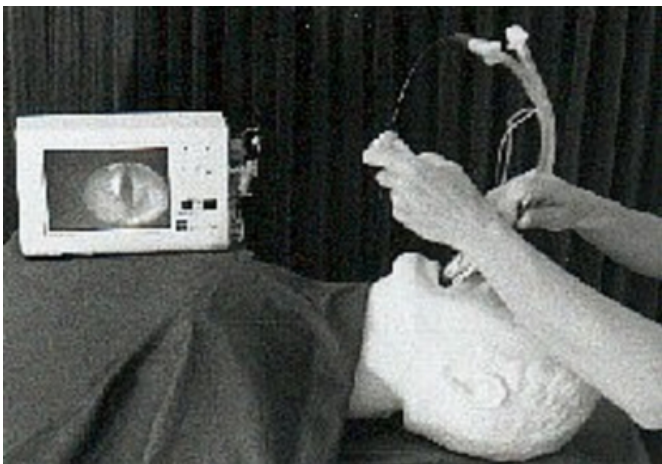

Figure 3

Fig. 2B

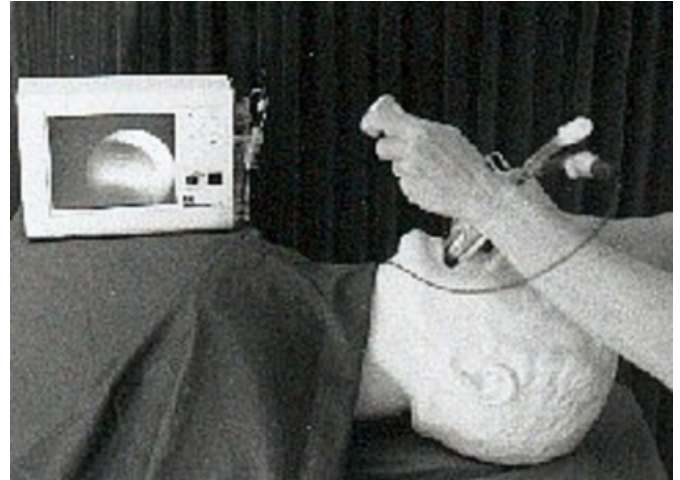

Fig. 2: The monitor display shows the video-view from the bronchial tube tip during conventional laryngoscopy (A) and during advancing the DLT down the trachea (B).

The VOIS is removed, the tracheal cuff inflated and the DLT connected to the anesthesia respirator. Then, the video-optical intubation stylet is inserted into the tracheal lumen and the bronchial cuff is inflated and controlled for proper position below the tracheal carina. During left-sided one-lung ventilation (OLV), the VOIS is left in the non-ventilated tracheal lumen to monitor continuously correct position of the bronchial cuff.

CASE REPORT

A 13-year-old, 32 kg girl was scheduled for right-sided thoracotomy and resection of the right lower lobe because of cystic malformation. Before starting anesthesia, an ultrathin video-optical intubation stylet (Volpi AG, Schlieren, Switzerland) attached to a video-monitor system had been inserted into the bronchial lumen of the 28 Ch left-sided PVC double-lumen tube ((Willy Ruesch AG, Germany).

After induction of anesthesia with thiopental, fentanyl and muscle paralysis with pancuronium, anesthesia was maintained with 2 % sevoflurane and 65 % nitrous oxide in oxygen. Conventional direct laryngoscopy was performed to insert the DLT through the vocal cords. Subglottic tracheal tube position was verified on the video-display and the DLT was rotated 90 degrees and advanced under video-optical control down the trachea. At the level of the tracheal carina, the tip of the bronchial lumen was directed into the left mainstem by an additional small rotation. The depth was noted when entering the left mainstem and the DLT was

advanced another 2.5 cm into the left bronchus.

The video-optical intubation stylet was removed, the tracheal cuff inflated and the DLT connected to the ventilator. The VOIS was inserted into the tracheal lumen to confirm and adjust the upper margin of the now inflated bronchial cuff just below the tracheal carina. The DLT was secured with tapes and the VOIS was removed.

After positioning the patient in the lateral position, the video-optical intubation stylet was reinserted into the tracheal lumen and the position of the bronchial cuff was checked. Intraoperatively, during left-sided one-lung ventilation, the VOIS was left in the non-ventilated tracheal lumen for continuous monitoring of the DLT position.

No problems were encountered with the DLT or with the VOIS intraoperatively. During the whole procedure, there was no need for an additional fiberoptic bronchoscope. The patient was successfully extubated after surgery and her postoperative course was uneventful.

DISCUSSION

Video-transmission of the view from the bronchial tube tip using a video-optical intubation stylet carries some potentially useful benefits for teaching, supervising and management of left-sided double-lumen tube.

Blind DLT insertion can cause trauma to the respiratory tract, incorrect tube position and inability to achieve adequate lung separation, particularly in case of extrinsic or intrinsic subglottic airway abnormalities.^(13,14,15,16,17,18,19,20,21,22) Thus, several reports have advocated the use of the fiber-optic bronchoscope as an “introducer” over which the double-lumen tube is advanced under direct vision.^(23,24,25,26,27) Using a video-optical intubation stylet, visualized DLT insertion can be performed in a simple and comfortable manner. The monitor view allows recognition of subglottic pathologies and incorrect tube placement during tube insertion before hypoventilation, overinflation, atelectasis and hypoxemia occur.

Maintenance of correct positioned DLT throughout the case is equally important as initial placement. Once in place, inadvertent relocation of the double-lumen tube during patient positioning, by surgical traction or during lung volume reduction surgery can lead to malfunctioning DLT and requires immediate diagnosis and correction.^(28,29,30,31)

The fact that the VOIS can be left in the non-ventilated DLT-lumen during the whole one-lung ventilation is a major

advantage. It allows early detection and immediately correction of dislocated DLT's. Additionally, flowing oxygen from the tip can be used to inflate the collapsed lung for better oxygenation if required.

The use of a video-optical intubation stylet for visualized DLT insertion has some potential advantages over a FOB as mentioned above. The double-lumen tube “loaded” with VOIS remains a light-weight and easily to handle tube. There is no interference with conventional laryngoscopy, no need for additional personal assistance and no change in insertion technique. Thus, this new technique would be suitable for routine visualized left-sided DLT insertion control. The costs of such an ultrathin video-optical intubation stylet and an appropriate video-monitor system are much lower than the costs of for a fiberoptic bronchoscope. Furthermore, the presented video-optical intubation stylet may be particularly helpful, when the FOB diameter is too large for pediatric DLT management. The FOB on the other hand can be used for suctioning and has a steerable tip.

CONCLUSIONS

The video-optical intubation stylet is a potentially useful tool for visualized double-lumen endotracheal tube management. It allows correct initial placement and continuous monitoring of correct position during one-lung ventilation. In addition, it provides an excellent opportunity for teaching and supervising.

References

1. Vaughan RS. Double Lumen tubes. *British J Anaesthesia* 1993;70:497
2. Benumof HL. Anesthesia for thoracic surgery: recent advances. *Can Anaesth Soc J* 1986;33:528-537
3. Vaughan RS. Endobronchial Intubation. In: *Difficulties in Tracheal Intubation*. Eds. Latta IP, Vaughan RS. Saunders London 1997, 328
4. Benumof JL. Anesthesia for thoracic surgery. Philadelphia, WB, Saunders 1987, pp230-236
5. Alliaume B, Coddens J, Deloof T. Reliability of auscultation in positioning of double-lumen endobronchial tubes. *Can J Anaesth* 1992;39:687-690
6. Smith GB, Hirsch NP, Ehrenwerth J. Placement of double-lumen endobronchial tubes : Correlation between clinical impressions and bronchoscopic findings. *British J Anaesth* 1986;58:1317-1320
7. Benumof JL. The position of a double-lumen tube should be routinely determined by fiberbronchoscopy. *J Cardiothorac Vasc Anesth* 1993;7:513-514
8. Klein U, Karzai W, Wohlfarth M, Gottschall R, Fritz H, Gugel M, Seifert A. Role of fiberoptic bronchoscopy in conjunction with the use of double-lumen tubes for thoracic anaesthesia. *Anesthesiology* 1998;88:246-250
9. Slinger PD. Fiberoptic Bronchoscopic Positioning of Double-Lumen Tubes. *J Cardiothorac Anesth* 1989;3:486-496 .

10. Weiss M. Video-intuboscopy. A new aid to routine and difficult tracheal intubation. *British Journal of Anaesthesia* 1998;80:525-527
11. Weiss M. The Pediatric Video-Optical Intubation Stylet. *The Internet Journal of Anesthesiology* 1998; Vol2N4:<http://www.ispub.com/journals/IJA/Vol2N4/vois.htm>
12. Gutstein HB. Use of the Bullard Laryngoscope and Lightwand in Pediatric Patients. *Anesthesiology Clinics of North America* 1998;16:795-812
13. Hurford WE, Alfille PH, Ballin MT, Behringer E, Cullen DJ, Haspel K, Wilson RS, Zapol WM. Placement and complications of double-lumen endobronchial tubes. *Anesth Analg* 1992;74:S141
14. Wagner DL, Gammaage GW, Wong MI. Tracheal rupture following insertion of a disposable double-lumen endotracheal tube. *Anesthesiology* 1985;63:698-700
15. Burton NA, Fall SM, Lyons T, Graeber GM. Rupture of the left mainstem bronchus with a polyvinylchloride double lumen tube. *Chest* 1983;83:928-929
16. Heiser M, Steinberg JJ, Mac Vaughn H, Klineberg PL. Bronchial rupture, a complication of use of the Roberstow double-lumen tube. *Anesthesiology* 1979;51:88
17. Stene R, Rose M, Weiniger MB, Benumof JL, Harrell J. Bronchial trifurcation at the carina complicating use of a double lumen tracheal tube. *Anesthesiology* 1994;80:1162-1164
18. Saito S, Dohi S, Tajima K. Failure of double-lumen endobronchial tube placement: Congenital tracheal stenosis in an adult. *Anesthesiology* 1987;66:83-85
19. Esener Z, Tülden B. Difficulty in endotracheal intubation due to congenital tracheal stenosis: A case report. *Anesthesiology* 1988;69:279-281
20. Bayes J, Slater EM, Hedberg PS, Lawson D. Obstruction of a double-lumen endotracheal tube by a saber-sheath trachea. *Anesth Analg* 1994;79:186-8
21. Takashi A. Torsion of a double-lumen tube in the left bronchus. *Anesthesiology* 1992;76:1064-1065
22. Van Dyck MJ, Astiz I. Kinking of a right-sided double lumen tube in the right upper lobe bronchus. *Anesthesiology* 1994;80:1410-1411
23. Shinnick JP, Freedmann AP. Bronchofiberscopic placement of a double-lumen endotracheal tube. *Critical Care Medicine* 1982;10:544-545
24. Mathew EB, Hirschmann RA. Placing double-lumen tubes with fiberoptic bronchoscope. *Anesthesiology* 1986;65:118-119
25. Boucek C, Freeman J, Landreaneau R, Bircher N, Klain M.A. Comparison of techniques for placement of left sided double lumen endobronchial tube. *Anesth Analg* 1996;82:S44
26. Ovassapian A. Fiberoptic bronchoscope and double-lumen tracheal tubes. *Anaesthesia* 1983;38:1104
27. Ovassapian A, Braunschweig R, Joshi CW. Endobronchial intubation using a flexible fiberoptic bronchoscope. *Anesthesiology* 1983;59:501
28. Saito S, Dohi S, Naito H. Alteration of double-lumen endobronchial tube position by flexion and extension. *Anesthesiology* 1985;62:696-697
29. Riley RH, Marples IL. Relocation of a double-lumen tube during patient positioning. *Anesth Analg* 1992;75:1071
30. Pscond DC, Fernandes JK. Inadvertent relocation of a double-lumen endotracheal tube by surgical traction. *Anaesth Intens Care* 1994;22:720-723
31. Sibell DM, Jaeger JM. Failure to ventilate through a double-lumen tube due to carinal shift during lung volume reduction surgery. *Anesth Analg* 1996;82:881-2

Author Information

M. Weiss, M.D.

Department of Anaesthesia, University Children's Hospital

K. Kern, M.D.

Department of Anaesthesia, University Children's Hospital

A Ch. Gerber, M.D.