

# Delayed Colonic Perforation after ESD in a Patient with Ulcerative Colitis: A Case Report and Review of the Literature

M Bechtold, N Szary, F Rashid, T Kilgore, S Puli, A Diaz-Arias, M Antillon

## Citation

M Bechtold, N Szary, F Rashid, T Kilgore, S Puli, A Diaz-Arias, M Antillon. *Delayed Colonic Perforation after ESD in a Patient with Ulcerative Colitis: A Case Report and Review of the Literature*. The Internet Journal of Gastroenterology. 2008 Volume 8 Number 2.

## Abstract

The efficacy and safety of endoscopic mucosal resection and submucosal dissection in the setting of ulcerative colitis has not been fully established. Potential complications, such as bowel perforations, may occur as a result of multiple issues. This case demonstrates a rare complication of delayed bowel perforation after an endoscopic submucosal dissection of a polyp in a patient with ulcerative colitis on chronic steroid therapy.

## INTRODUCTION

Endoscopic mucosal resection (EMR) and endoscopic submucosal resection (ESD) are procedures designed to endoscopically remove mucosal lesions, including intramucosal cancers from the gastrointestinal tract (1). EMR offers an alternative to surgery for many forms of lesions, including polypoid, protuberant, flat, ulcerated, as well as lateral spreading tumors (2). EMR is a snaring procedure which is limited in the size of lesions that may be removed in an en-bloc fashion. Piecemeal removal is associated with a high risk of local recurrence. ESD utilizes a specialized needle-knife to dissect mucosal and submucosal lesions, providing the ability for a greater en-bloc resection than EMR, especially for lesions larger than 2cm (3,4). Although EMR and ESD are recognized therapeutic alternatives to partial or complete colectomy for mucosal and submucosal lesions, complications may occur, especially if not performed by an experienced endoscopist. These complications include bleeding, perforation, and bacteremia (5-7). Certain conditions, such as ulcerative colitis in which EMR and ESD have not been well-studied, may lead to increased complications. This case demonstrates a rare incidence of delayed perforation and colonic bleeding after ESD in a patient with ulcerative colitis on chronic corticosteroid therapy.

## CASE

An 83 year-old male with history of ulcerative colitis and

chronic obstructive pulmonary disease presented to the outpatient endoscopy unit for endoscopic resection of a mass in the ascending colon after he had refused surgery. The procedure, performed under propofol, revealed a 4x8cm flat mass in the ascending colon. (Figure 1) The lesion was raised by injecting 250cc of a mixture of normal saline (500cc), epinephrine (1.5cc of 1:1000), and indigo carmine (2.5cc of 0.8%) into the submucosa. Using a conventional needle knife, dissection of the mass was performed. After 80% of the polyp was dissected, a snare was placed around lesion to expedite the final removal. However, the snare became embedded into the tissue and was unable to be dislodged. The handle was then cut, leaving the snare attached to the lesion. The scope was removed and reintroduced alongside the snare. The entire lesion was then removed with the needle knife. The patient subsequently developed a distended abdomen. Two small defects were noted, closed with seven resolution clips, and resolved by endoscopic visualization. The lesion and the embedded snare were recovered and removed. Soon after procedure, the patient became hypotensive, which quickly responded to intravenous fluids of normal saline. Patient was also given intravenous antibiotics (ampicillin-sulbactam and metronidazole). Due to his post-procedure condition and long-term COPD, the patient was kept intubated and transferred to medical ICU for further care.

Upon admission to ICU, the patient was placed on levofloxacin and metronidazole. Hydrocortisone IV was

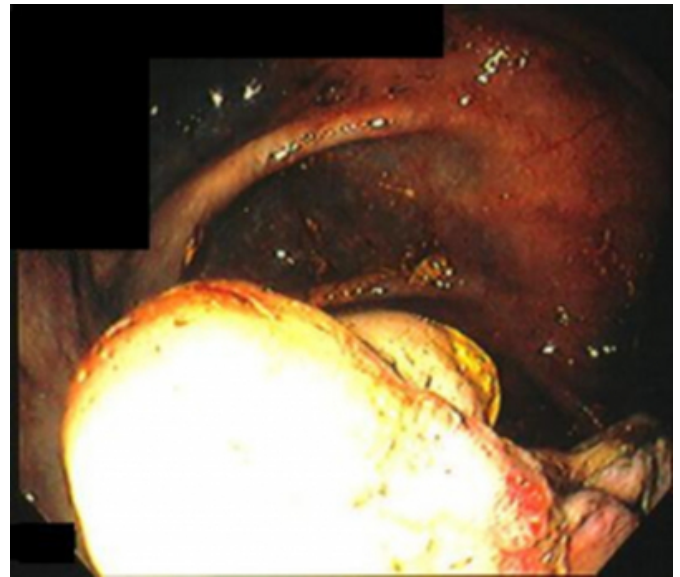
initiated since the patient had a history of chronic prednisone use and was given nothing-by-mouth. He was placed on heparin 5,000 units SQ every eight hours for deep vein thrombosis prophylaxis. The ESD specimen of the lesion revealed a tubulovillous adenoma with underlying cauterized submucosa. No muscularis propria was present. (Figure 2)

On hospital day #3, patient was significantly improved with softened abdomen, improved leukocytosis, minimal ventilation settings, and increased urine output. On hospital day #4, the patient continued to improve with decreased abdominal distention and pain in addition to passing flatus and was subsequently extubated.

On hospital day #5, the patient experienced respiratory distress, significantly increased abdominal distention, and hematochezia. Patient was emergently re-intubated and placed on mechanical ventilation. Laboratory data suggested acidosis and a decrease in hemoglobin. The patient emergently underwent exploratory laparotomy. During the procedure, a small opening was noted at the hepatic flexure with a large amount of bleeding and a small amount of soilage. A right hemicolectomy with diverting ileostomy was subsequently performed. Post-operatively, the patient was placed on intravenous piperacillin-tazobactam and metronidazole, intravenous fluids, and hydrocortisone taper. The resection specimen from surgery revealed seven metal clips with underlying full thickness necrosis with associated adjacent hemorrhage, cautery artifact involving the muscularis propria, and acute inflammation with dense inflammatory infiltrate extending to the subserosal fat with focal microabscesses. No cautery artifact was noted in adjacent muscularis propria. The perforation was noted 3.5cm from the clips but within the adjacent ESD site. (Figure 3) On hospital day #8, the patient was extubated. On hospital day #12, the patient was found to have an infra-renal abdominal aortic aneurysm measuring 10.5 x 8.4cm on a CT of the abdomen. The patient's hospital course was also complicated by intermittent atrial fibrillation. The patient is currently under the care of general surgery for anticipated AAA repair.

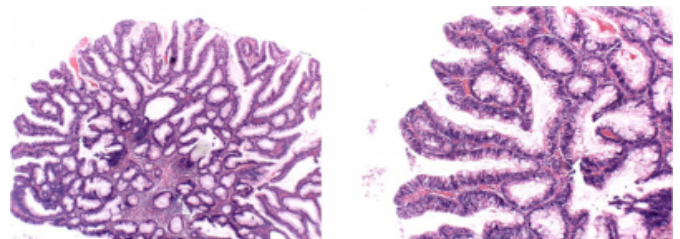
**Figure 1**

Figure 1: Ascending colon polyp



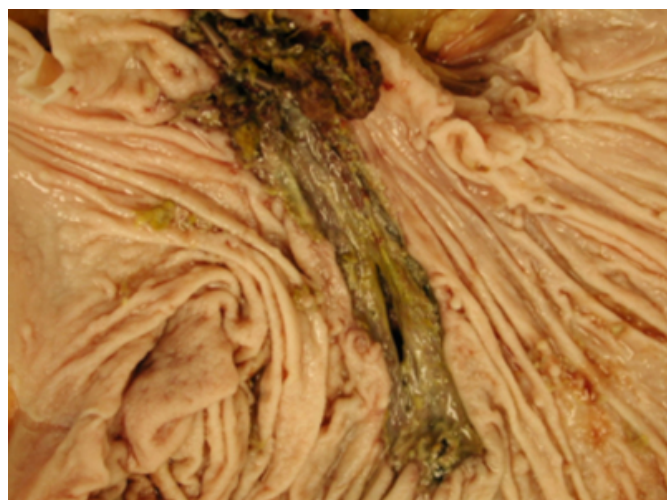**Figure 2**

Figure 2: Pathology of polyp revealing tubulovillous adenoma histology showing villous and glandular patterns with pseudostratification of the hyperchromatic nuclei and mucin depletion at 40X (LEFT) and at 100X (RIGHT).



### Figure 3

Figure 3: Gross pathology specimen showing colonic perforation 3.5cm from the clips.



### DISCUSSION

EMR and ESD have become common in Japan for the therapy of early gastric cancer. EMR and ESD are becoming more widely available, especially in Japan, and more recently in the United States and Europe, as an alternative to surgery for mucosal and submucosal colonic lesions that cannot be removed by traditional endoscopic practice. We have been performing ESD at our institution since 2006 with greater than 140 cases completed. As this new technology becomes more prevalent, new applications and possibly new complications may be identified.

Our case represents a delayed perforation after an ESD procedure in a patient with long-standing ulcerative colitis and chronic corticosteroid use. Although perforations after ESD have been described in the literature, a delayed perforation in this type of clinical setting has yet to be described. Since this is the first reported case, the causative etiology may only be hypothesized.

Chronic steroid use has been associated with an increase in bowel perforations in scattered case reports over the past 40 years (8-11). However, the consensus view has been that chronic steroid use does not result in an increase risk of colonic perforation. Although chronic corticosteroid use may have contributed to the overall outcome, it was unlikely the main causative factor.

Perforation of the bowel wall in this patient may have been multi-factorial. First, a missed micro-perforation secondary to ESD may have originally sealed only to reopen when bowel motility returned. Second, the ascending portion of

the colon is thinner and ESD may have decreased the wall thickness to unacceptable level, thereby causing perforation when intraluminal pressure returned to normal. Third, ischemia in the colonic segment from ESD and entrapment of the snare may have led to perforation due to inadequate healing mechanisms and necrosis causing disruption of tissue.

While all the potential mechanisms above are viable, the contribution of inflammatory bowel disease to the perforation must be emphasized. Patients with ulcerative colitis experience non-transmural colonic wall abnormalities which are limited to mucosa and submucosa (12). In fact, removal of mucosa and submucosa by ESD should have led to removal of inflamed tissue associated with ulcerative colitis. However, ulcerative colitis is a systemic disease with altered pro-inflammatory cytokine profile which may cause delayed wound healing by local tissue damage from reactive oxygen radicals and tissue-degrading enzymes (13). In turn, this may theoretically increase the chance of perforation or poor outcome. Furthermore, a larger question remains whether ESD should be performed in patients with inflammatory bowel disease (IBD). Theoretically, the pro-inflammatory state of IBD which leads to poor wound healing increases the risks of bowel perforation and rates of contaminant surgery (14). The large proportion of IBD patients with dysplasia-associated lesions or masses which could potentially be resected via ESD make this issue of great consequence to further ESD use in IBD.

This case demonstrates a rare adverse event of ESD in a patient with ulcerative colitis on chronic steroid therapy. Given the paucity of literature regarding this subject and expanding role of ESD, further prospective trials are needed to resolve this issue.

### References

1. Technology status report evaluation. Endoscopic mucosal resection. *Gastrointest Endosc* 2000;52(6):860-3.
2. Conio M, Ponchon T, Blanche S, Filiberti R. Endoscopic mucosal resection. *Am J Gastroenterol* 2006;101(3):653-63.
3. Ono H. Endoscopic submucosal dissection for early gastric cancer. *Chin J Dig Dis* 2005;6(3):119-21.
4. Fujishiro M, Yahagi N, Nakamura M, Kakushima N, Kodashima S, Ono S, Kobayashi K, Hashimoto T, Yamamichi N, Tateishi A, Shimizu Y, Oka M, Ogura K, Kawabe T, Ichinose M, Omata M. Successful outcomes of a novel endoscopic treatment for GI tumors: endoscopic submucosal dissection with a mixture of high-molecular-weight hyaluronic acid, glycerin, and sugar. *Gastrointest Endosc* 2006;63(2):243-9.
5. Ahmad NA, Kochman ML, Long WB, Furth EE, Ginsberg GG. Efficacy, safety, and clinical outcomes of endoscopic mucosal resection: a study of 101 cases.

Gastrointest Endosc 2002;55(3):390-6.

6. Yoshikane H, Hidano H, Sakakibara A, Mori S, Takahashi Y, Niwa Y, Goto H. Endoscopic resection of laterally spreading tumours of the large intestine using a distal attachment. Endoscopy 1999;31(6):426-30.

7. Lee TH, Hsueh PR, Yeh WC, Wang HP, Wang TH, Lin JT. Low frequency of bacteremia after endoscopic mucosal resection. Gastrointest Endosc 2000;52(2):223-5.

8. Katz S, Talansky A, Kahn E. Recurrent free perforation in gastroduodenal Crohn's disease. Am J Gastroenterol 1983;78(11):722-5.

9. Orringer RD, Collier JA, Veidenheimer MC. Spontaneous free perforation of the small intestine. Dis Colon Rectum 1983;26(5):323-6.

10. Warshaw AL, Welch JP, Ottinger LW. Acute perforation

of the colon associated with chronic corticosteroid therapy. Am J Surg 1976;131(4):442-6.

11. Demling RH, Salvatierra O Jr, Belzer FO. Intestinal necrosis and perforation after renal transplantation. Arch Surg 1975;110(3):251-3.

12. Ince MN, Elliott DE. Immunologic and molecular mechanisms in inflammatory bowel disease. Surg Clin North Am 2007;87(3):681-96.

13. Rieder F, Brenmoehl J, Leeb S, Schölmerich J, Rogler G. Wound healing and fibrosis in intestinal disease. Gut 2007;56(1):130-9.

14. O'Brien TS, Garrido MC, Dorudi S, Collin J. Delayed perforation of the colon following colonoscopic biopsy. Br J Surg 1993;80(9):1204.

**Author Information**

**Matthew L. Bechtold**

Division of Gastroenterology and Hepatology Department of Internal Medicine University of Missouri School of Medicine  
Columbia, Missouri, USA

**Nicholas M. Szary**

Division of Gastroenterology and Hepatology Department of Internal Medicine University of Missouri School of Medicine  
Columbia, Missouri, USA

**Farzana Rashid**

Division of Gastroenterology and Hepatology Department of Internal Medicine University of Missouri School of Medicine  
Columbia, Missouri, USA

**Todd W. Kilgore**

Division of Gastroenterology and Hepatology Department of Internal Medicine University of Missouri School of Medicine  
Columbia, Missouri, USA

**Srinivas R. Puli**

Division of Gastroenterology and Hepatology Department of Internal Medicine University of Missouri School of Medicine  
Columbia, Missouri, USA

**Alberto Diaz-Arias**

Department of Anatomical Pathology University of Missouri School of Medicine Columbia, Missouri, USA

**Mainor R. Antillon**

Division of Gastroenterology and Hepatology Department of Internal Medicine University of Missouri School of Medicine  
Columbia, Missouri, USA