

# Pneumatosis intestinalis with superior mesenteric and hepatic portal venous gas in sigmoid colonic cancer: CT findings.

G Di Salvo, G Zotto, P Spillare, G Schittullo, A Bruscaignin

## Citation

G Di Salvo, G Zotto, P Spillare, G Schittullo, A Bruscaignin. *Pneumatosis intestinalis with superior mesenteric and hepatic portal venous gas in sigmoid colonic cancer: CT findings.* The Internet Journal of Radiology. 2008 Volume 10 Number 2.

## Abstract

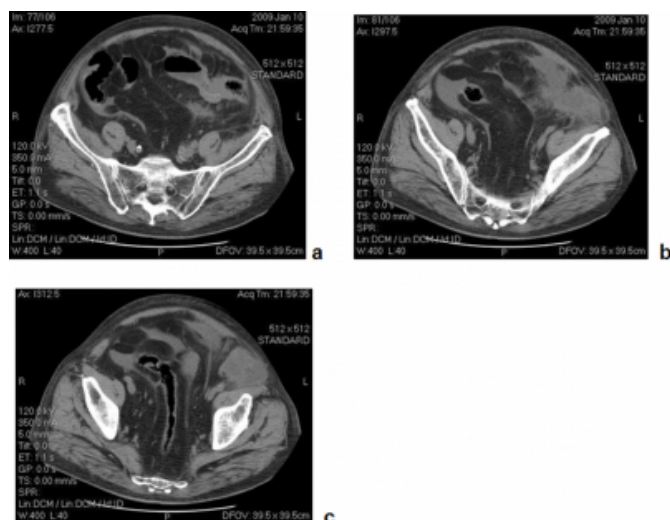
In this article we present a case of colonic cancer with pericolic abscess, complicated by pneumatosis of the small bowel with gas in inferior and superior mesenteric veins and hepatic portal veins, with emphasis on CT scanning and its diagnostic accuracy.

## CASE REPORT

A 83-year-old man was admitted at our Hospital with severe abdominal pain, fever, luminal obstruction, leukocytosis. Physical exam showed a not-tender abdomen and a “mass” in the left lower quadrant. A CT scan of the abdomen and pelvis was obtained without contrast media. CT revealed an irregular thickening of a segment of sigmoid colon, with luminal stenosis and inflammatory stranding with increased density of contiguous fat, associated with pericolic dense-fluid collection (figures 1a, 1b and 1c) and fluid in peritoneal spaces (figure 2).

## Figure 1

Figure 1 – Midpelvic CT scans without contrast media



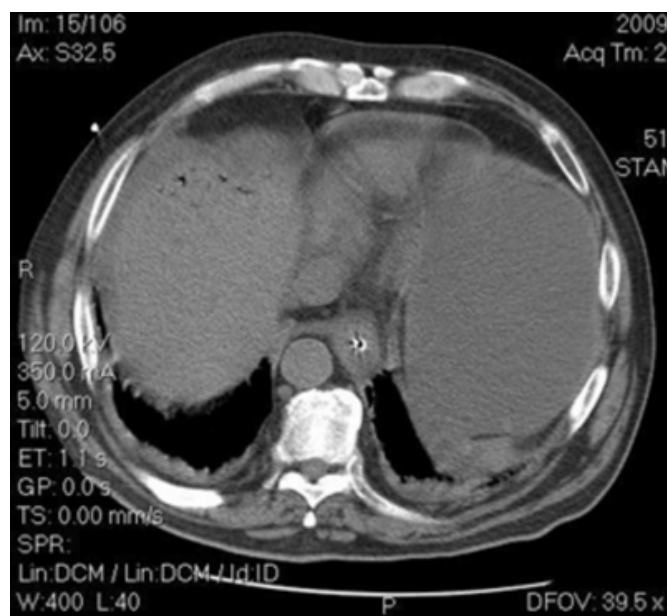
a-Thickening of sigmoid colon with stenosis.

b-Inflammatory pericolic stranding

c-Fluid collection lying in front of left ileo-psoas muscle.

## Figure 2

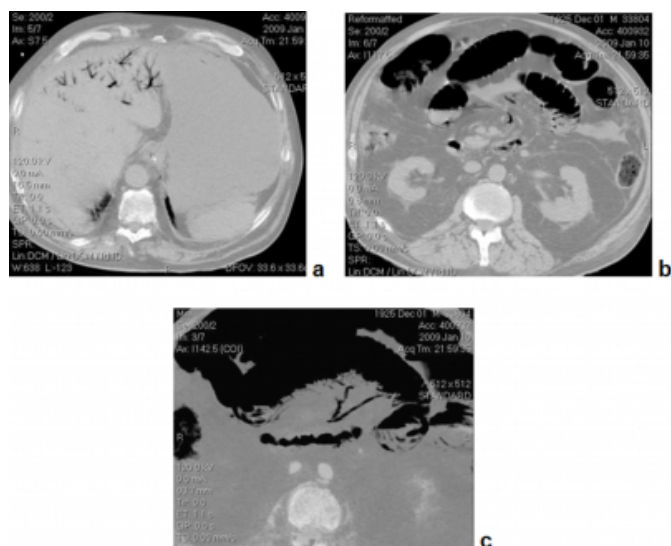
Figure 2 – CT scan of the upper abdomen, showing perihepatic fluid.



Pneumatosis of small bowel, mostly curvilinear, but also bubbly, and endoluminal gas in superior and inferior mesenteric and hepatic portal veins were also found (fig. 3a, 3b and 3c).

**Figure 3**

Figure 3 – CT scans: hepatic dome and root of mesentery



a-Gas in intrahepatic portal veins.

b-Gas in some branches of mesenteric veins.

c-MinIP reconstruction showing air-filled mesenteric veins and bowel pneumatosis.

On the basis of CT findings and patient's conditions, emergency surgery was performed, with partial colectomy, end colostomy and abscess drainage. The final diagnosis was colonic cancer with pericolic abscess. After surgery patient's condition worsened and ten days after the intervention patient died.

## DISCUSSION

The presence of gas within portal and mesenteric veins has been described by many Authors in the past and indicates a direct fistula with intestinal gas and/or the presence of gas-forming organisms in venous lumen: pneumatosis intestinalis, first described by DuVeroni in 1730, may be associated (1,2,3,7,8). Pneumatosis intestinalis represents a finding of equivocal importance, interesting anywhere the gastrointestinal tract (3). Its importance is related to underlying etiology: vascular occlusive diseases, necrotizing enterocolitis, inflammatory bowel diseases, bowel occlusion, acute phlegmonous gastritis, immunosuppressive therapy, AIDS, ingestion of toxins, chronic pulmonary obstructive disease, abdominal desmoid tumor, surgery and hip fracture (3,4,5,6).

Abdominal plain film can detect gas in the hepatic dome and also pneumatosis intestinalis, however in about half of the cases: it is also revealed on magnetic resonance and ultrasound imaging (9,10,11). In our case patient's conditions forced to CT examination, that easily depicted, even without contrast media, bowel occlusion and its etiology, represented by neoplastic stricture of sigmoid colon with ancillary pericolic abscess. Moreover, gas in mesenteric-portal veins and pneumatosis intestinalis were clearly seen in CT scans: even if these findings did not represent a diagnosis, nevertheless surgery became mandatory after CT examination.

CT imaging is the best exam to diagnose not only pneumatosis intestinalis, and the presence of gas within portal and mesenteric veins, but should be considered the imaging of choice in evaluating critical patients with severe abdominal pain, because it is by far more sensitive in delineating the etiology of pneumatosis intestinalis and portal gas than plain films or ultrasound.

## References

1. Molitch HI. Septic thrombophlebitis of the inferior mesenteric vein complicating sigmoid diverticulitis: CT findings. *AJR* 167:1014-1016, 1996
2. Graham GA, Bernstein RB, Groner AT. Gas in the porta and inferior mesenteric veins caused by diverticulitis of the sigmoid colon. *RADIOLOGY* 114:601-602, 1975
3. Pearl BL. Pneumatosis intestinalis: a review. *RADIOLOGY* 207:13-19, 1998
4. Baig MA, Rasheed J, Yu-Shia Lin, Smith PR. Necrotizing enterocolitis with Hepatic portal venous gas and pneumatosis intestinalis in a patient with AIDS. *The Internet Journal of Infectious Diseases* 2006, vol.5, n.1
5. Prat A, Peralta S, Cuéllar H, Ocana A. Hepatic pneumatosis as a complication of an abdominal desmoid tumor. *JCO* 25:897-896, 2007
6. Perry CW, Phillips BJ. Pneumatosis intestinalis: a fractured hip? *The Internet Journal of Gastroenterology* 2001, vol.1, n.2
7. Ito M, Horiguchi I, Miyakawa S. Pneumatosis intestinalis and hepatic portal venous gas. *Hepatobiliary Pancreat Surg* 15(3):334-337, 2008
8. See C, Elliott D. Pneumatosis intestinalis and portal venous gas. *N ENGL J MED* 350:4, 2004
9. Lerner HH, Gazin AI. Pneumatosis intestinalis: its roentgenologic diagnosis. *AJR* 56:464-469, 1945
10. Babushka LS, Kulman JE. Pneumatosis intestinalis: appearance on MR examination. *CLIN IMAGING* 18:258-261, 1994
11. Vernacchia FS, Jeffrey RB, Laing FC, Wing VW. Sonographic recognition of pneumatosis intestinalis. *AJR* 145:51-52, 1985

**Author Information**

**Giuseppe Di Salvo, MD**

Department of Radiology Ospedale Civile Chioggia, Italy

**Gianmaria Dal Zotto, MD**

Department of Radiology Ospedale Civile Chioggia, Italy

**Pietro Matteo Spillare, MD**

Department of Radiology Ospedale Civile Chioggia, Italy

**Giuseppe Schittullo, MD**

Department of Radiology Ospedale Civile Chioggia, Italy

**Andrea Bruscagnin, MD**

Chief of Department of Radiology Ospedale Civile Chioggia, Italy