

Agensis Of The Gallbladder: What To Do In Such A Rare Case? Presentation Of A Case And Review Of The Literature

V G, P E, P A.

Citation

V G, P E, P A.. *Agensis Of The Gallbladder: What To Do In Such A Rare Case? Presentation Of A Case And Review Of The Literature*. The Internet Journal of Surgery. 2010 Volume 26 Number 2.

Abstract

Agensis of gallbladder (AGB) is a very rare congenital abnormality that usually has no characteristic symptomatology and maybe associated to other system malformations. Many of these patients develop a typical symptomatology of cholelithiasis that leads them to operation theater. If an operative procedure is done, it is better to remain at the level of laparoscopy because further surgical investigation may lead to detrimental biliary tract injuries. Establishment of a preoperative diagnosis using noninvasive imaging modalities such as MRCP permits to avoid a risky surgical procedure. We present a case of AGB, discuss the manipulation problems and review the literature.

INTRODUCTION

Agensis of gallbladder (AGB) is a very rare anatomical abnormality first reported by Lemery in 1707 (1) or by Bergman in 1702 (2). The incidence in the general population is reported as 13-65 cases/100000 (3). In clinical series, the incidence is 0.007-0.0027%, while in autopsy series it is 0.04-0.13% (4). AGB may be associated with other system malformations as gastrointestinal, genitourinary, cardiovascular, musculoskeletal or some congenital syndromes (5). The patients may become symptomatic in 23-50% of cases presented mainly as a cholecystitis that leads to unnecessary surgery. Preoperative diagnosis includes imaging modalities that may be falsely interpreted (U/S, CT, ERCP, etc.). The main tool to establish pre- and postoperative diagnosis of AGB is MRCP. Once a surgeon meets such a situation, it is wiser to do nothing further in the operating theater and to try to establish the accurate diagnosis postoperatively mainly by using MRCP.

CASE REPORT

A 60-year-old female presented with clinical features of chronic cholecystitis with a shrunken gallbladder on the ultrasonic (U/S) report. Medical history consisted of dyspepsia and many episodes of mild pain in the right subcostal region for the last 9 months. All laboratory findings were within normal limits. Ultrasonic investigation revealed a bright echogenic streak in the gallbladder fossa

suggestive of a shrunken fibrotic gallbladder with a normal biliary tree. According to these findings, it was decided to perform a laparoscopic cholecystectomy. On laparoscopy, the gallbladder could not be visualized from the junction of the left and right hepatic ducts until it disappeared behind the second part of the duodenum. We did not find any evidence of a gallbladder, cystic duct or cystic artery (Fig. 1-4). In order to prevent any incidental injury, we decided to stop the operation here, remaining at the level of a simple laparoscopy. On the 1st postoperative day, a new U/S did not reveal any evidence of orthotopic or ectopic gallbladder. The biliary tree was normal but a large cyst of the right kidney was revealed (Fig. 5-6). The patient had an improvement in symptomatology after the procedure and 4 years later she is still free of symptoms.

Figure 1

Fig. 1: Empty gallbladder fossa

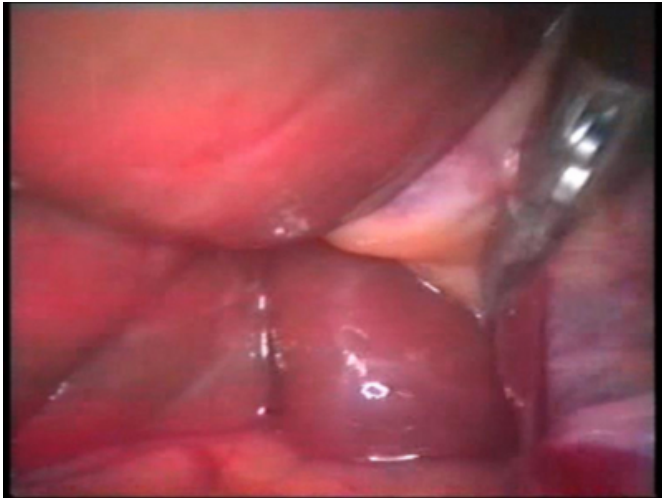


Figure 3

Fig. 3: Free porta hepatis

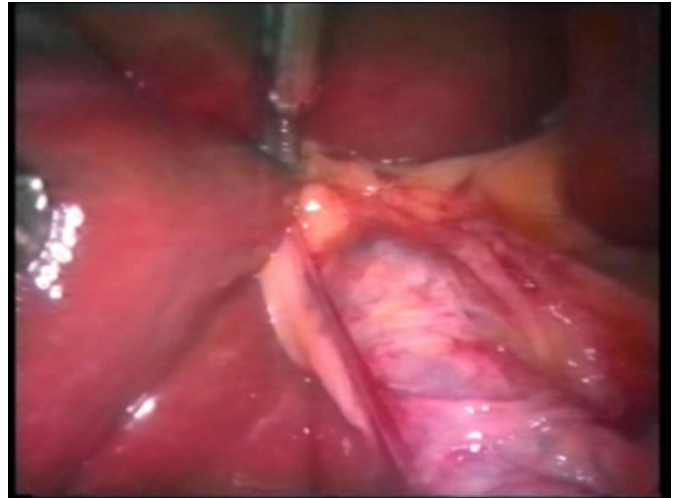


Figure 2

Fig. 2: No cystic duct remnant

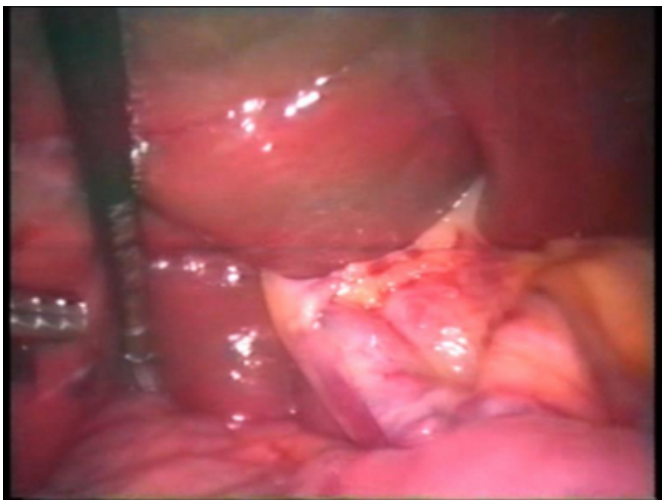


Figure 4

Fig. 4: No gallbladder on left liver lobe

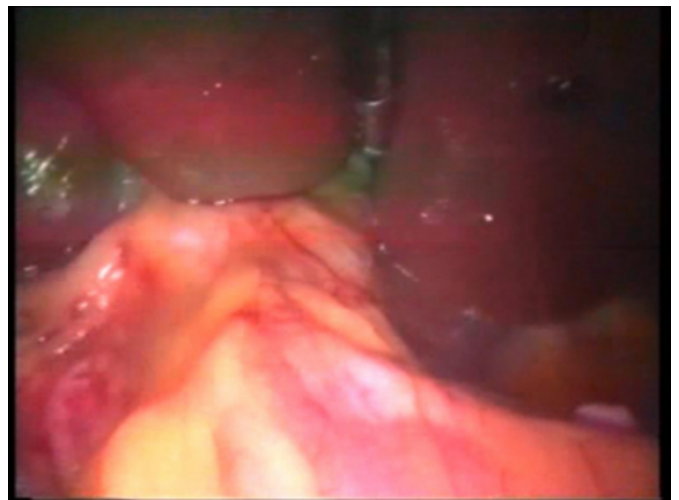


Figure 5

Fig. 5: Normal biliary tree - no ectopic gallbladder

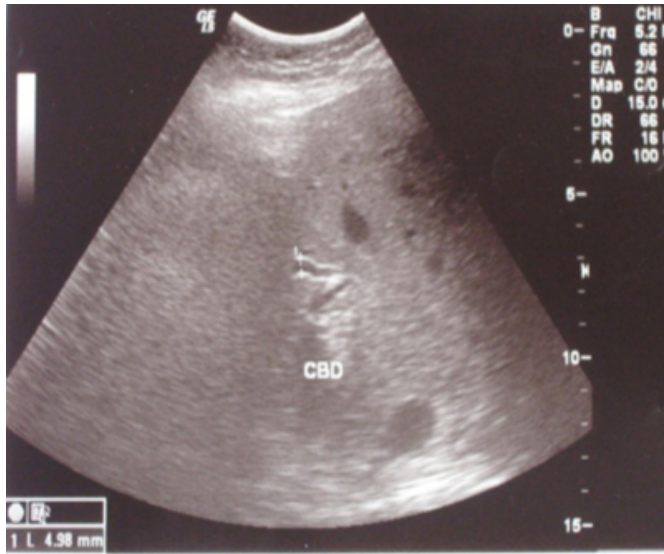
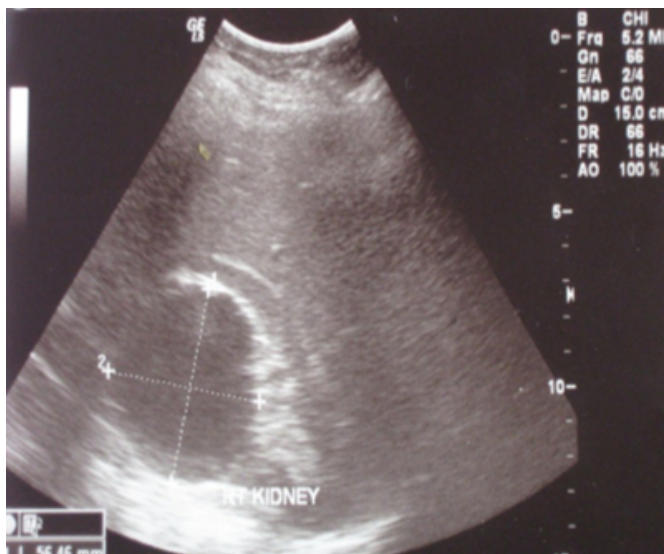
Figure 6

Fig. 6: Large cyst of the right kidney



DISCUSSION

Agenesis of the gallbladder (AGB) is a very rare congenital anomaly. Till July 2010, a total of 413 cases have been reported in the literature (6).

The gallbladder develops from the caudal part of the hepatic diverticulum in the fourth week of embryonic life. There are two theories regarding non-development of the gallbladder. According to one theory, the hepatic diverticular bud of the foregut fails to develop properly into gallbladder and cystic duct. The other theory holds that, following solid-phase development, there is a failure of recanalization of cystic

duct and gallbladder. Isolated AGB results when the cystic bud does not develop (7-10).

AGB is associated with other malformations in several systems in 40-65% (11,12). In a review of autopsies in 29 cases, 13 had malformations in the genitourinary/reproductive system, 8 had cardiovascular and skeletal system malformations, 5 had abnormalities in the anterior abdominal wall and in the remaining 3 cases the AGB was alone (13). There have been reported clinical triades such as AGB, annular pancreas, lumbar hernia (14), or AGB, annular pancreas and portal anomaly (15). There may be a familial tendency. The AGB is associated with congenital syndromes as cerebrotendinous xanthomatosis (16) and the G-syndrome (13), Klippel-Feil syndrome (42) and trisomy 18 (43). Some authors reported AGB as a result of thalidomide therapy (44). AGB may be inherited with a non-sex-linked heredity, with several familial cases observed, including across two generations (1,4,17-19).

AGB itself has no characteristic symptomatology (9). Clinically, 3 groups of AGB presentation were reported by Bennion et al. in 1988 (20): 1) Multiple foetal anomalies (15-16%): These patients invariably die in the perinatal period due to associated anomalies and AGB was only recognized at autopsy. Most frequently encountered were cardiovascular, gastrointestinal, genitourinary, anterior abdominal wall, and central nervous system anomalies. In this group, AGB is only a trivial anomaly. 2) Asymptomatic group (35%): AGB was discovered either at autopsy, at laparotomy for unrelated diagnosis or by screening the family members of patients known to have AGB. These patients do not have symptoms of the biliary tract. 3) Symptomatic group (50%): This major group presents in the 4th or 5th decades and this is usually an isolated anomaly. In the symptomatic group, common signs are chronic right upper quadrant pain (90%), dyspepsia (30%), nausea and vomiting (66%), fatty food intolerance (37%), and jaundice (35%) (21). The possible mechanisms of symptoms include primary duct stone, biliary dyskinesia or non-biliary disorders. Biliary dyskinesia may be due to a spasm of the Oddi sphincter and is associated with increased pressure in the common bile duct (4). Possible causes of the pain in AGB include biliary dyskinesia, adhesions in the gallbladder fossa, or periportal adhesions. The lysis of these adhesions at operation is the main cause that this pain is resolved postoperatively (22).

AGB may coexist with stones in the remnant of the cystic

duct or choledocholithiasis (23). There are two main expressions: 1) AGB without cystic duct remnant (24) and 2) AGB with cystic remnant (25).

If the diagnosis of AGB is made during operation, the surgeon must prove AGB by thorough investigation of the most common sites for ectopic gallbladders, which are intrahepatic, retrohepatic, on the left side or within the leaves of the lesser omentum or within the falciform ligament and retroperitoneal (7,10). Some surgeons even report the need to convert to open access, in order to establish an accurate diagnosis of AGB (26). Excessive dissection is required to fulfill Frey's criteria (27) for AGB, and because of great danger of injuries in the hepatobiliary tract, this procedure must be avoided. It is not wise to convert a laparoscopic to an open-access procedure. It is better to remain at the level of a simple laparoscopy and to establish the accurate diagnosis of AGB postoperatively by imaging modalities, mainly by MRCP (9,28,29,30).

The use of imaging modalities in order to diagnose AGB has some advantages and disadvantages that should be kept in mind:

U/S (ultrasonography) is the method of choice for the diagnosis of cholelithiasis or common bile duct stones with a sensitivity of 95-98%. Shadowy opacities misdiagnosed as stones can be due to intestinal gas artifacts or duodenum (10), subhepatic peritoneal folds (20,21), or periportal tissue (22). Sometimes, in the place of an absent gallbladder, there may be a liver hemangioma (31), a great lipoma (32) or migrated liver tissue in the fossa of the gallbladder (33) that creates diagnostic problems not only on U/S but also in the interpretation of other imaging modalities such as CT.

ERCP (Endoscopic Retrograde CholangioPancreatography) has little contribution in diagnosis of AGB because non-visualization of gallbladder is regularly interpreted as an occlusion of the cystic duct, leading to false diagnosis (2,4,10,28,34-37).

MRCP (Magnetic Resonance CholangioPancreatography) is a noninvasive and well demonstrated imaging method in the evaluation of the biliary tract (38,39). As it does not require contrast material to visualize the bile, it is not compromised by biliary stasis. It can then demonstrate an excluded and/or ectopic gallbladder (4). Preoperative MRCP should be considered in cases in which ultrasound suggests non-visualization of the gallbladder before any decision to operate (37). In one case, MRCP was interpreted wrongly

with the comment that "the gallbladder was difficult to identify but appeared to be contracted", but there was a large liver hemangioma in the gallbladder fossa (31).

Cholangioscintigraphy, intraoperative U/S and selective arteriography may be useful but are not always available (4).

There are some cases reported in which AGB was diagnosed preoperatively and the operation was avoided (10,28,40,41)

CONCLUSIONS

Agenesis of gallbladder is a very rare condition with no specific symptoms. It is associated with malformations of other systems and it seems that there is a "familiar tendency". The patients without gallbladder are usually operated because a "false" interpretation of U/S. When U/S reveals a "scleroatrophic" gallbladder or in cases of non-visualization in other imaging modalities, the need of further preoperative investigation must be in the surgeon's mind.

It seems that MRCP is the most accurate non-invasive diagnostic tool to establish the diagnosis of AGB and to avoid unnecessary and detrimental risky surgery. When laparoscopic surgery is done, further surgical procedures should be abandoned in order to prevent injuries and the patients must undergo postoperative investigation. The correct preoperative diagnosis of AGB is fundamental to avoid unnecessary surgical exploration which might be dangerous to patients.

References

1. Nadeau LA, Cloutier WA, Konecki JT, Morin G, Taylor RW: Hereditary gallbladder agenesis: twelve cases in the same family. *J Maine Med Assoc*; 1972; 63: 1-4.
2. Toufeeq Khan TF, Baqai FU: Agenesis of the gallbladder with duplication cysts of the hepatic flexure – A case report and literature review. *Singapore Med J*; 1991; 34: 181-2.
3. Richards RJ, Taubin H, Wasson D: Agenesis of the gallbladder in symptomatic adults. A case and review of the literature. *J Clin Gastroenterol*; 1993; 16(3): 231-3.
4. Peloponissios N, Gillet M, Cavin R, Halkic N: Agenesis of the gallbladder: A dangerously misdiagnosed malformation. *World J Gastroenterol*; 2005; 11(39): 6228-6231.
5. Weisberg J, Pinto PE Jr., Gusson PR, Fasano PR, De Goody AC: Agenesis of the gallbladder and cystic duct. *Sao Paulo Medical J*; 2002; 120(6): 192-194.
6. Beuran M, Paun S, Negoii I, Ganescu R, Runcaru A, Avram M, Chiotoroiu AL: Laparoscopic approach in gallbladder agenesis - an intraoperative surprise. *Chirurgia (bucur)*; 2010; 105(4): 531-6.
7. Gotohda N, Itano S, Horiki S, et al.: Gallbladder agenesis with no other biliary tract abnormality: report of a case and review of the literature. *J Hepatobiliary Pancreat Surg* 2000; 7(3): 327-330.
8. Gilbert Scott F: *Developmental Biology*. 5th Ed. Sunderland (MA): Sinauer Associates Inc 1997; 9: 382-3.

9. Bani-Hani KE: Agenesis of the gallbladder: Difficulties in management. *J Gastroenterol Hepatol*; 2005; 20: 671-675.
10. Fiaschetti V, Catabrese G, Viarani S, Bazzocchi G, Simonetti G: Gallbladder agenesis and cystic duct absence in an adult patient diagnosed by Magnetic Resonance Cholangiography: Report of a case and review of the literature. Case report in *Medicine* published online in February 2010.
11. Monroe SF, Ragen FJ: Congenital absence of the gallbladder. *California Medicine*; 1956; 85: 422-423.
12. Haughton V, Lewicki AW: Agenesis of the gallbladder. Is preoperative diagnosis possible? *Radiology*; 1973 ; 106: 305-306.
13. Turkel SB, Swanson V, Chandrasoma P: Manifestations associated with congenital absence of the gallbladder. *J Med Genet*; 1983; 20: 445-449.
14. Gupta N: Gallbladder and cystic duct agenesis diagnosed laparoscopically. *Hepatobiliary and Pancreatic Diseases International* 2010.
15. Martinoli S, Schmitt HE, Allgower M: An unusual triad: gallbladder agenesis, annular pancreas and portal anomaly. *Helv Chir Acta* 1980; 46(5-6): 767-770.
16. Winter RB, Baraitser M: Multiple congenital anomalies. A diagnostic compendium. First Ed Cambridge: Chapman and Hall Medical 1991; 109.
17. Wilson JE, Deitrick JE: Agenesis of the gallbladder: case report and familial investigation. *Surgery*; 1986; 99: 106-109.
18. Sterchi JM, Baine RW, Myers RT: Agenesis of the gallbladder - an inherited defect? *South Med J*; 1977; 70: 498-499.
19. Becker TW, Mastroni PP: Congenital absence of the gallbladder with a family history. *Am Surg*; 1979; 45: 541-542.
20. Bennion RS, Thompson IE, Tompkins RK: Agenesis of the gallbladder without extrahepatic biliary atresia. *Arch Surg* 1988; 123: 1257-1260.
21. Vijay K, Hemant T, Kocher H, et al.: Agenesis of gallbladder - A diagnostic dilemma. *J of Postgrad Med* 1996; 42(3): 80-82.
22. Hershman MJ, Southern SJ, Rosin RD: Gallbladder agenesis diagnosed at laparoscopy. *J R Soc Med*; 1992; 85: 702-703.
23. Ishida M, Egawa S, Takahashi Y, Kohari M, Ohwada Y, Uhno M: Gallbladder agenesis with a stone in the cystic duct bud. *J Hepatobiliary Pancreat Surg*; 2008; 15(2): 220-223.
24. Kwon AH, Yanagimoto H, Matsui Y, Imamura A: Agenesis of the gallbladder with hypoplastic cystic duct diagnosed at laparoscopy. *Surg Laprosc Endosc Percutan Tech*; 2006; 16(4): 251-254.
25. Azmat N, Francis KR, Mandava N, Pizzi WF: Agenesis of the gallbladder revisited laparoscopically. *Am J Gastroenterol*; 1993; 88: 1269-1270.
26. Owen RP, Botros M, Uzair S: Two cases of gallbladder agenesis diagnosed at planned cholecystectomy - lessons learned. *The Internet Journal of Surgery*; 2011; 26(1).
27. Frey C, Bizer L, Ernst C: Agenesis of the gallbladder. *Am J Surg*; 1967; 114: 917-926.
28. Grandhi TM, El-Rabaa SM: Agenesis of the gallbladder and cystic duct: laparoscopic diagnosis. *The Internet J of Gastroenterology*; 2005; 4: 1.
29. Balakrishnan S, Singhal T, Grandy-Smith S, El-Hasani S: Agenesis of the gallbladder: Lessons to learn. *JSLS*; 2006; (10): 517-519.
30. Laopodis V, Liasis L, Stephanidis P, Ntourakis D, Kadjianis F, Tzardis P: Congenital agenesis of the gallbladder: An update surprise during laparoscopic cholecystectomy. *Hellenic J of Surgery*; 2010; 82:6: 378-380.
31. Stephenson JA, Norwood M, Al-Leswas D, Al Taan O, Beable R, Lloyd D, Dennison A: Hepatic haemangioma masquerading as the gallbladder in a case of gallbladder agenesis: A case report and literature review. *HPB Surgery*; 2010; pii: 971609.
32. ZhengXY, Shen GL, Sun XD, Huang DS: Agenesis of the gallbladder with adipose tissue in the gallbladder fossa. *Hepatogastroenterology*; 2010; 57(98): 212-214.
33. Shaher Z: Gallbladder anomalies; agenesis, hourglass and liver tissue migration: A multimedia article. *The Internet Journal of Surgery*; 2005; 7: 1.
34. Muguruma N, Okamura S, Ishikawa S, et al.: Asymptomatic case of congenital absence of gallbladder. *J Med Invest*; 2001; 48: 118-121.
35. Cabayo CM, Martin del Olmo JC, Blanco AJ, Atienza SR: Gallbladder and cystic duct absence. An infrequent malformation in laparoscopic surgery. *Surg Endosc*; 1997; 11: 483-484.
36. Smadi SI, Naasan WA, Alkaabneh AB, Haddad JS: Agenesis of gallbladder. A case report. *JRMS*; 2005; 12(2): 63-65.
37. Malde S: Gallbladder agenesis diagnosed intra-operatively: a case report. *J Medical Case Reports*; 2010; 4: 265.
38. Vanbeckevoort D, Van HL, Ponette E, Marchal G, Bosmans H, De CB: Imaging of gallbladder and biliary tract before laparoscopic cholecystectomy: comparison of intravenous cholangiography and the combined use of HASTE and single-shot RARE MR imaging. *J Belge Radiol*; 1997; 80: 6-8.
39. Chan FL, Chan JK, Leong LL: Modern imaging in the evaluation of hepatolithiasis. *Hepatogastroenterology*; 1997; 44: 358-369.
40. Venuta A, Laudizi L, Miceli F, Pantusa M, Laudizi Z: Agenesis of the gallbladder. Description of 2 cases in 2 siblings. *Pediatr Med Chir*; 1989; 11: 465-466.
41. O'Sullivan J, O'Brien PA, MacFeely L, Whelton MJ: Congenital absence of the gallbladder and cystic duct: nonoperative diagnosis. *Am J Gastroenterol*; 1987; 82: 1190-1192.

Author Information

Velimezis G

Surgical Ward, Western Attica General Hospital

Perrakis E

Surgical Ward, Western Attica General Hospital

Perrakis A.

Surgical Ward, Western Attica General Hospital