

Pneumatosis Intestinalis: A Fractured Hip?

C Perry, B Phillips

Citation

C Perry, B Phillips. *Pneumatosis Intestinalis: A Fractured Hip?*. The Internet Journal of Gastroenterology. 2000 Volume 1 Number 2.

Abstract

Pneumatosis intestinalis (PI) is characterized by the presence of air within the bowel wall, which can occur at any point along the gastrointestinal tract. The actual significance of PI is related to the associated disease state or underlying condition. Presented is a brief report demonstrating pneumatosis intestinalis in a traumatized patient.

CASE REPORT

A fifty three year old white female with alcoholic liver disease (Child's Class C - ascities, bilirubin 6.4, PT 16.4, albumen 2.9) was admitted with a femoral neck fracture and a urinary tract infection. Her lower extremity was placed in traction and intravenous antibiotic therapy was initiated. On the eighth hospital day she developed acute abdominal pain. Abdominal radiographs revealed an ileus pattern. [Figures 1 & 2]

Figure 1

Figure 1: Flat-plate Abdomen

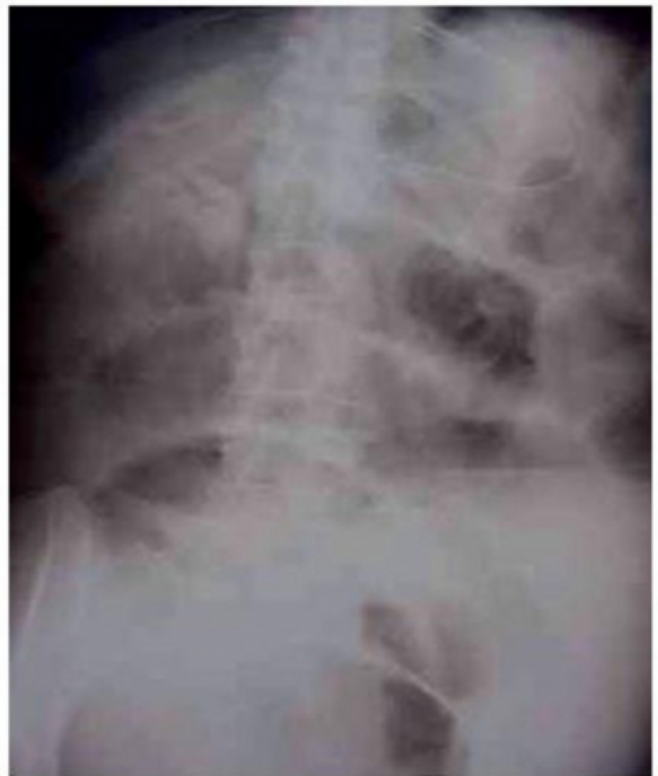
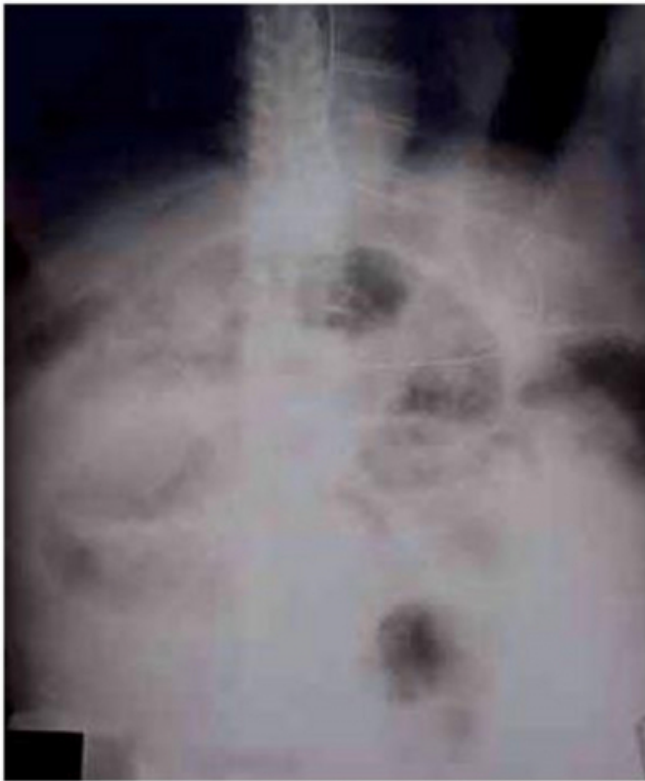
Figure 2

Figure 2: Upright Abdomen



With an associated fever of 38.5° C an abdominal computed tomography scan was obtained. [Figures 3 & 4]

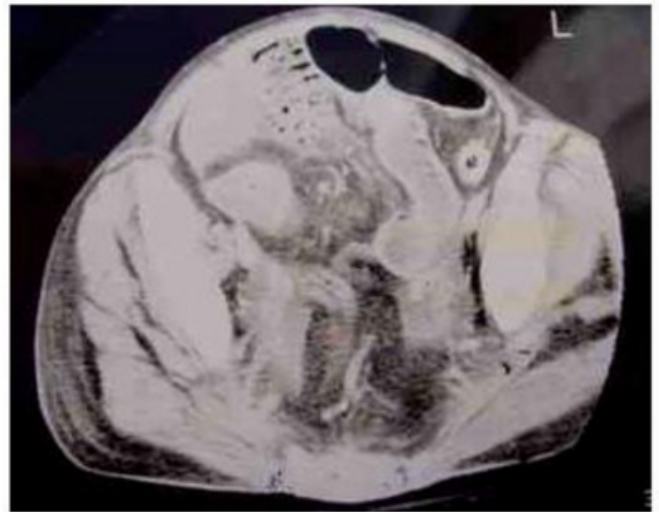
Figure 3

Figure 3: C.T. Scan Abdomen

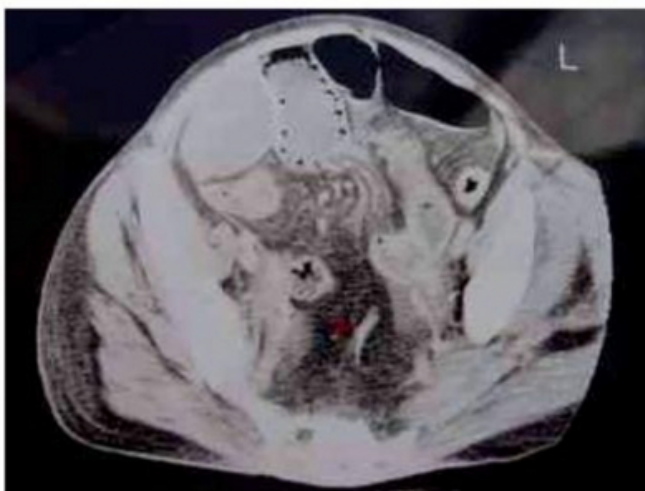

Figure 4

Figure 4: C.T. Scan, Abdomen



Pneumatosis intestinalis of unknown etiology was diagnosed. Life threatening conditions could not be identified and non-operative management with oxygen, antibiotics, and gastric decompression was initiated. Her abdominal pain subsequently resolved and she was discharged to a nursing home facility on hospital day fifteen. Her follow up has been unremarkable to date.

DISCUSSION

Characterized in 1730 as the presence of air within the bowel wall, pneumatosis intestinalis (PI) can occur anywhere in the gastrointestinal tract from the esophagus to the rectum. Pneumatosis intestinalis, a finding of equivocal importance, is diagnosed through radiography, endoscopy or pathological examination. The significance of PI is related to the underlying etiology. Symptoms may include diarrhea, hematochezia, melena, abdominal pain, distention, constipation, weight loss, and tenesmus. Disease processes associated with pneumatosis include necrotizing enterocolitis, chronic obstructive pulmonary disease, acute phlegmonous gastritis, ingestion of toxins, vascular occlusive disease, bowel obstruction, bowel infarction, inflammatory bowel disease, infections, immunosuppressive therapy, and bypass surgery.

While barium enema and computerized tomography are more sensitive in delineating the etiology of PI, the diagnosis through plain films will occur in half of all cases. Treatment is disease specific; asymptomatic patients may not require therapeutic intervention. Therapeutic options reduce gas formation within the bowel by raising the systemic partial pressure of oxygen, “sterilizing” the bowel,

and utilizing an elemental diet. Theoretically, increasing the arteriolar partial pressure of oxygen, allows cystic gases to diffuse and deflation to occur. Antibiotic therapy and elemental diets reduce intestinal bacterial fermentation, hydrogen formation, and PI formation. Although non-operative therapy is often associated with relapses, surgery is rarely necessary. Indications for surgery include unresolved obstruction, portal venous gas, metabolic acidosis of unknown origin, and hyperamylasemia; all are nonspecific signs associated with necrotic bowel. Treatment should always be tailored to the individual and as this case

demonstrates, the significance of pneumatosis intestinalis relates to the underlying disease state.

References

1. Heng Y, Schuffler M, and Haggitt R. Pneumatosis Intestinalis: A Review. *The American Journal of Gastroenterology*. 90(10):1747-58, 1995.
2. Boerner R, Fried D, Warshauer D, and Isaacs K. Pneumatosis: Two Case Reports and a Retrospective Review of the Literature from 1985-1995. *Digestive Diseases and Sciences*. 40(11):2272-2285, 1996.
3. Knechtle S, Davidoff A, and Rice R. Pneumatosis Intestinalis: Surgical Management and Clinical Outcome. *Annals of Surgery*. 212(2):160-165, 1990.

Author Information

Charles W. Perry, M.D.

Dept. of Surgery, University of Arizona

B. J Phillips, MD

Department of Surgery , Kaiser Permanente