

Neglected Telangiectatic Osteosarcoma of the Clavicle in a Child

S Khan, N Gogi, R Anwar, N Khan

Citation

S Khan, N Gogi, R Anwar, N Khan. *Neglected Telangiectatic Osteosarcoma of the Clavicle in a Child*. The Internet Journal of Third World Medicine. 2005 Volume 3 Number 2.

Abstract

We present a case of telangiectatic osteosarcoma of the clavicle in a ten-year-old female child. The tumor was neglected for more than six months and no treatment was taken. The case report highlights the neglect of bone tumors in developing countries to a stage where they become untreatable. The malignant nature of the lesion with limited treatment modalities at hand makes the management of these tumors extremely difficult with poor outcome.

INTRODUCTION

Clavicle is an unusual site for any primary bone tumor, including osteogenic sarcoma. Although a rare site of affection, most clavicular tumors tend to be malignant. We present here the case of a ten-year-old girl with a huge telangiectatic osteosarcoma of the clavicle. The tumor was neglected for more than six months and no treatment was taken.

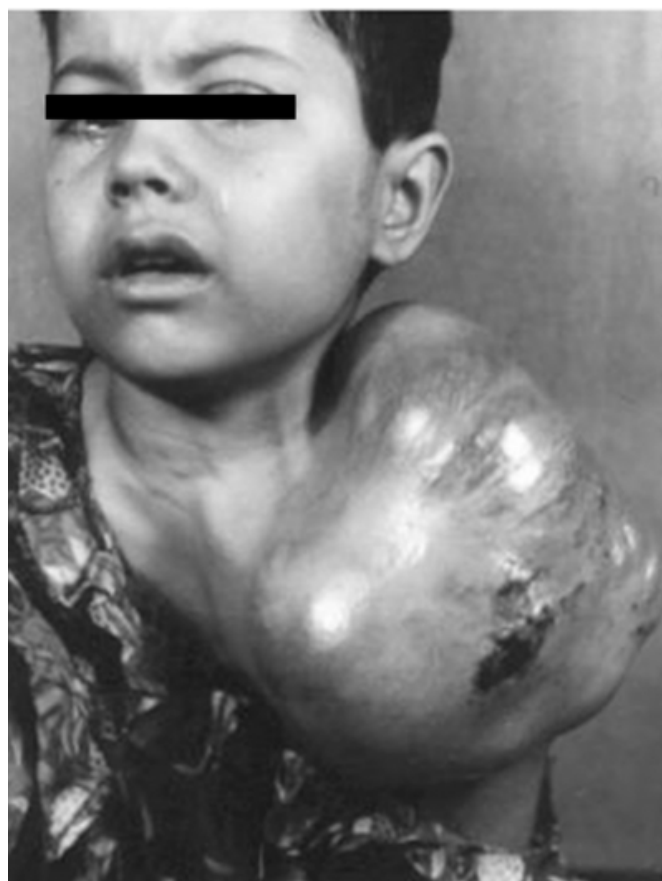CASE REPORT

A ten-year-old female child presented with a huge swelling of the left clavicle for the last six months. The swelling was gradual in onset and had grown rapidly over the last couple of months. No treatment was taken till this stage except for some herbal medicines by a village osteopath.

On examination there was a 10cm x 15cm-ulcerated growth overlying the left clavicle (Fig.1).

Figure 1

Figure 1: Clinical photograph of the patient



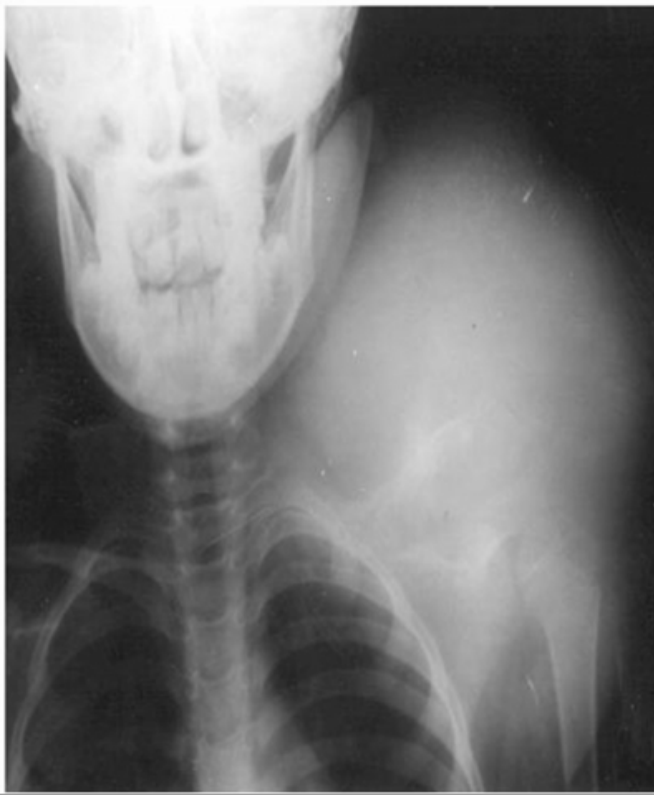The tumor had a variegated consistency and the overlying skin was ulcerated and fixed. The neck was displaced onto the opposite side. The tumor was tender to touch and the underlying clavicle and the acromio-clavicular joint were not

palpable distinctly. Axillary artery to the left upper limb was sluggish but there was no distal neurological deficit. All shoulder movements were restricted due to pain. There were palpable homolateral hard axillary lymph nodes. There were no other systemic findings.

Routine blood investigations revealed hemoglobin of 8-gram percent. Other blood investigations were non-contributory. Radiogram of the left clavicle showed a massive osteolytic lesion arising from the clavicle with near total destruction of the underlying bone (Fig.2).

Figure 2

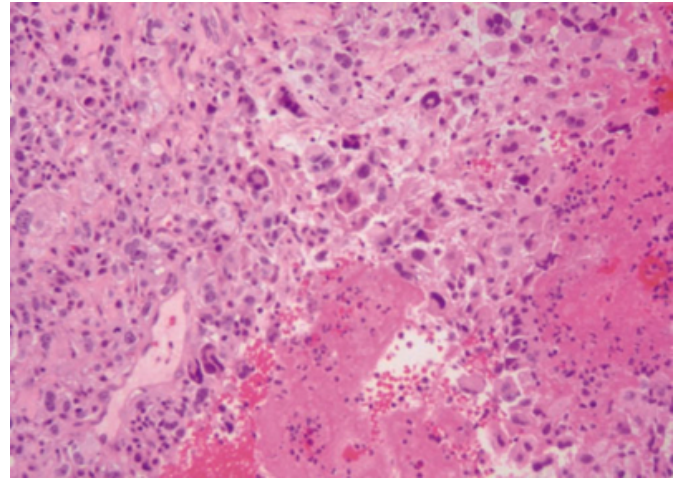
Figure 2: Radiograph of the patient showing the expansile lesion of the left clavicle



CT Scan of the chest revealed two subpulmonic metastatic nodes. A core biopsy from the lesion revealed histopathology compatible with a telangiectatic osteosarcoma (Fig.3).

Figure 3

Figure 3: Photomicrograph of the specimen (40X) showing malignant osteoid seams with intervening vascular spaces



Three cycles of chemotherapy using the St. Jude's protocol were given to the patient. This was followed by a forequarter amputation with resection of the whole clavicle. Post-operative recovery was uneventful, The child was given three more cycles of chemotherapy, but the child died 4 months after surgery following the development of new metastasis in the chest.

DISCUSSION

The clavicle is an unusual site for all primary bone tumors. Though extremely rare, primary tumors of the clavicle are more likely to be malignant than benign (3). The occurrence of osteosarcoma in the clavicle has been infrequently reported in world literature (1, 2, 3). In a series of 711 primary bone tumors of the shoulder and proximal humerus, Link et al have reported 19 tumors in the clavicle. Of these, none was a telangiectatic osteosarcoma. In one of the largest and most exhaustive series, spread over more than 50 years, fifty-eight patients with different malignant lesions of the clavicle have been reported by the authors (3). Osteosarcoma was the second commonest lesion next to plasmacytoma in the series.

Paucity of data in the literature on this type of lesion makes clear understanding of the optimal treatment difficult. Osteosarcomas of the clavicle are known to have a more malignant course when compared to peripheral osteosarcomas (1). Given its anatomical location, the lesion requires a multidisciplinary approach for optimal care, with each member of the health care team being important for maintaining and prolonging the quality of life for a patient (2). We have found no report of long-term survival on a

patient with this lesion. The case report highlights the amount of neglect of bone tumors prevalent in the developing countries, which can lead to loss of limb and life.

CORRESPONDENCE TO

Dr. Shah Alam Khan Assistant Professor, Department of Orthopaedics All India Institute of Medical Sciences Ansari Nagar, New Delhi –29, India E-mail: shahalamkhan@rediffmail.com

References

1. Browne RF, Torreggiani WC, Munk PL: Telangiectatic osteosarcoma of the clavicle: case report. *Can Assoc Radiol J.* 2003 Jun;54(3):174-6.
2. Byrd T, Gleis GE, Johnson JR: Primary osteogenic sarcoma of the clavicle. A case report. *Orthopedics.* 1986 Dec;9(12):1717-20.
3. Oda Y, Hashimoto H, Tsuneyoshi M, Masuda S. Periosteal osteosarcoma of the clavicle Case report 793. *Skeletal Radiol.* 1993;22(5):375-7.
4. Paderni S, Trentani P, Trentani F, Stagni C, Bertoni F: Primary osteogenic sarcoma of the clavicle. Case report. *Chir Organi Mov.* 2002 Jan-Mar;87(1):63-6.
5. Smith J, Yuppa F, Watson RC: Primary tumors and tumor-like lesions of the clavicle. *Skeletal Radiol.* 1988;17(4):235-46.

Author Information

Shah Alam Khan, MS Ortho., DNB Orth., MRCS Ed, M.Ch.Orth (Liverpool)

Assistant Professor, Department of Orthopaedics, All India Institute of Medical Sciences

Nitish Gogi, MS Ortho, MRCS (Ed)

Specialist Registrars, Department of Orthopaedics & Trauma, Birmingham City Hospital

Rahij Anwar, MS Ortho, MRCS(Ed),M.Sc.Orth (Birmingham)

Specialist Registrars, Department of Orthopaedics & Trauma, Birmingham City Hospital

Nadeem Khan, FRCS

Specialist Registrars, Department of Orthopaedics & Trauma, Birmingham City Hospital