

# Laptop artifact during electroencephalography

N Sethi, N Schaul, D Kolesnik, D Labar, P Sethi

## Citation

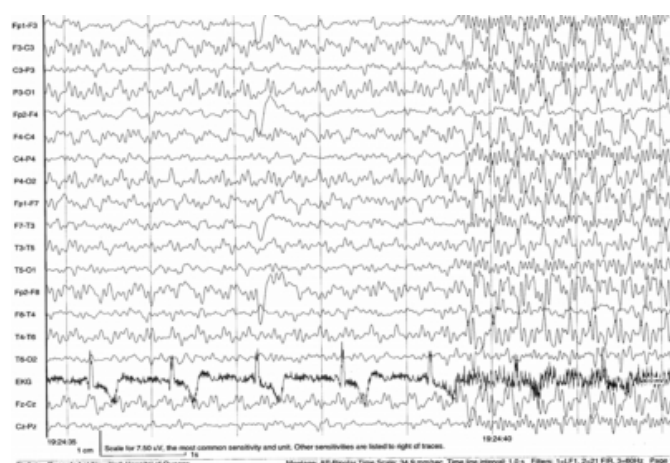
N Sethi, N Schaul, D Kolesnik, D Labar, P Sethi. *Laptop artifact during electroencephalography*. The Internet Journal of Neuromonitoring. 2006 Volume 5 Number 2.

## Abstract

Artifacts are signals recorded on the electroencephalogram (EEG) that are not cerebral in origin and can be divided into physiological and non-physiological artifacts. Physiological artifacts are generated from the patient itself and include cardiac, glossokinetic, muscle, eye movement, respiratory and pulse artifact among many others. Numerous non-physiological artifacts generated from the immediate patient surroundings can contaminate EEG recordings. Common non-physiological artifacts include those generated by monitoring devices, infusion pumps, suctioning devices and chest physiotherapy <sup>1</sup>. Lately artifacts generated by electronic devices like mobile phones have been reported <sup>2</sup>. During inpatient video EEG recording of a patient, rhythmic highly sharply contoured 14-16 Hz waveforms were visualized in all the leads (Fig 1,2).

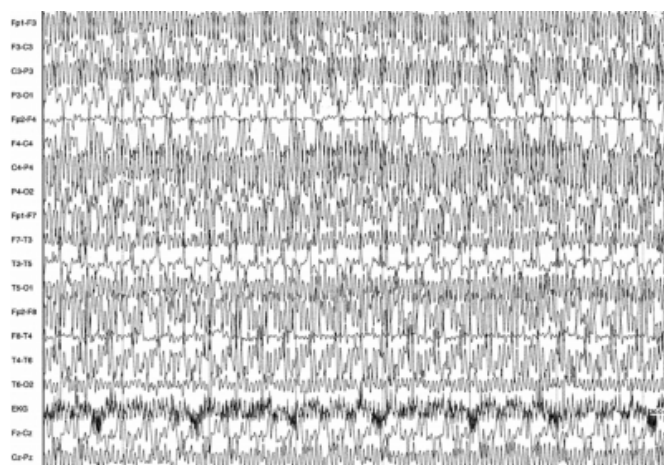
## Figure 1

Figure 1: EEG record showing onset of 14-16 cycles per second rhythmic highly sharply contoured waveforms in all leads.



## Figure 2

Figure 2: EEG record showing 14-16 cycles per second rhythmic highly sharply contoured waveforms. This artifact occurred whenever the patient touched the laptop pad.



Upon viewing the video images, this sharply contoured discharge was noted to occur whenever the patient touched the laptop pad in front of her. We tried to cross and uncross the wire of the laptop AC adaptor with the EEG head box but were unable to isolate what exactly generated these waveforms. The patient was using a wireless PC card to access the Internet. Recognition of non-physiological artifacts like these is important to avoid misinterpretation of the EEG and erroneous treatment decisions. It also highlights the point that medical devices may fail to operate correctly due to interference from various emitters of radiofrequency energy.

## CORRESPONDENCE TO

NK Sethi, MD Department of Neurology Comprehensive Epilepsy Center NYP-Weill Cornell Medical Center 525 East, 68<sup>th</sup> Street New York, NY 10021(U.S.A.) E-mail: sethinitinmd@hotmail.com

**References**

1. Sethi NK, Torgovnick J, Sethi PK. Chest percussion artifact. Clin Neurophysiol. 2007; 118 (2): 475-6.
2. Sethi PK, Sethi NK, Torgovnick J. Mobile phone artifact. Clin Neurophysiol. 2006; 117(8): 1876-8.

**Author Information**

**N.K. Sethi**

Department of Neurology, Comprehensive Epilepsy Center, NYP-Weill Cornell Medical Center

**N. Schaul**

Department of Neurology, Comprehensive Epilepsy Center, New York Hospital

**D. Kolesnik**

Department of Neurology, Comprehensive Epilepsy Center, New York Hospital

**D. Labar**

Department of Neurology, Comprehensive Epilepsy Center, NYP-Weill Cornell Medical Center

**P.K. Sethi**

Department of Neurology, Sir Ganga Ram Hospital