

Non-Hodgkin lymphoma of the descending colon in a child with obstruction; a case report and review of literature

P Srivastava, A Gangopadhyay, D Gupta, V Upadhyaya, S Sharma

Citation

P Srivastava, A Gangopadhyay, D Gupta, V Upadhyaya, S Sharma. *Non-Hodgkin lymphoma of the descending colon in a child with obstruction; a case report and review of literature*. The Internet Journal of Surgery. 2008 Volume 21 Number 2.

Abstract

Primary gastrointestinal non-Hodgkin lymphoma (NHL) accounts for 13-18% of all malignant tumours of small bowel and only 1% of large bowel tumours. The most common site of non-Hodgkin lymphoma of the intestinal tract in children is the terminal ileum and the ileocecal region. The non-Hodgkin lymphoma (NHL) of descending colon is extremely rare in children. We report non-Hodgkin lymphoma of the descending colon in an 8-year-old child with features of large bowel obstruction due to a large intraluminal single polyp. The diagnosis revealed non-Hodgkin lymphoma. Early diagnosis is mandatory and multimodality treatment is required to prevent complications and prolong survival.

BACKGROUND

Primary alimentary tract malignancies, including primary gastrointestinal non-Hodgkin lymphoma (NHL), are rare in children [1]. The incidence of primary colorectal lymphomas is rare, comprising 10-20% of cases of non-Hodgkin lymphoma with limited stage and high-grade disease [2]. Colorectal involvement accounts for between 10% and 20% of the cases in most studies of gastrointestinal tract lymphoma. Primary lymphomas of the descending and sigmoid colon are extremely rare in children [3]. When NHL involves gastrointestinal disease, it usually arises in the submucosal lymphoid tissue of the ileocecal region, with transmural extension and extensive local involvement of mesenteric lymph nodes, forming a bulky abdominal mass. The ileocecal valve is most frequently involved (35.8%), followed by the small bowel (31.3%), large bowel (19.4%) and multiple gastrointestinal involvements (13.4%) [4]. Surgery is an important treatment modality for primary colorectal NHL because it is localized, and supplemented by systemic chemotherapy in the form of CHOP regime.

CASE REPORT

An 8-year-old boy presented to us with a history of left lower abdominal pain for 15 days. There was off-and-on fever for ten days but the symptom did not subside with medication. Then, after 2-3 days, he had an episode of vomiting and distension of the abdomen associated with blood in stool. Per-rectal examination was not significant. Abdominal ultrasonography [figure-1] showed a single

homogeneous solid mass measuring 5.6×4.8 cm located in the descending colon. Colonoscopy showed a single polypoidal mass that occluded the entire lumen of the descending colon [figure-2]. CT scan of the abdomen was done to confirm the site and extent of the lesion [figure-3]. The results of all routine blood tests were within normal limits. Explorative laparotomy was done and there was the intraluminal polypoidal mass present in the descending colon. It was resected along with the bowel segment with end-to-end colonic anastomosis. Histological examination revealed the diagnosis of B-cell lymphoma, diffuse large cell type, which was positive for pan-B cell marker CD20. After the patient recovered from surgery, chemotherapy (six cycles) in the form of cyclophosphamide, vincristine, doxorubicin and prednisolone (CHOP) was administered. He remains well and free of disease symptoms after 2 years.

Figure 1

Figure-1: Ultrasonography of the abdomen shows a mass in the descending colon

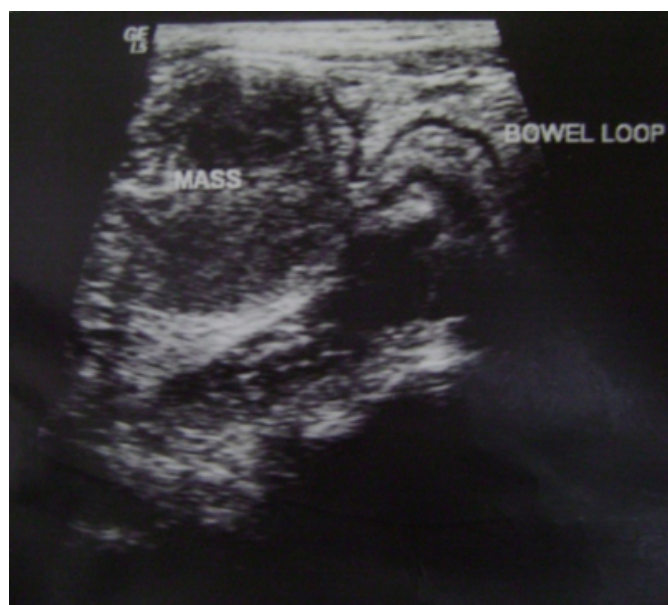

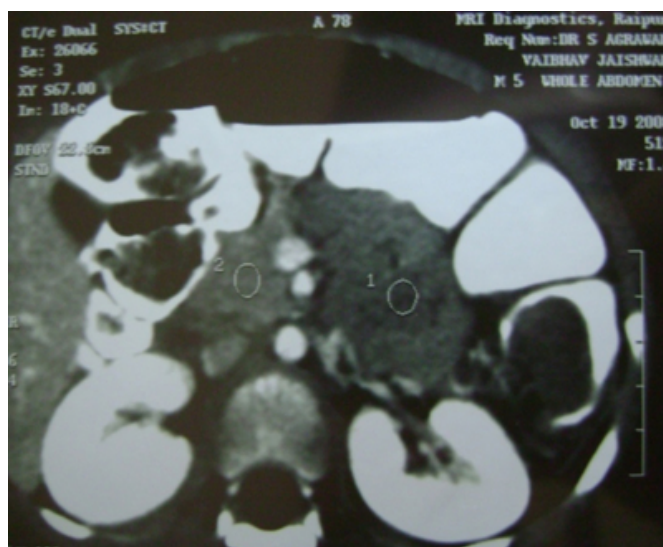
Figure 2

Figure-2: Colonoscopy shows a polypoidal mass in the descending colon

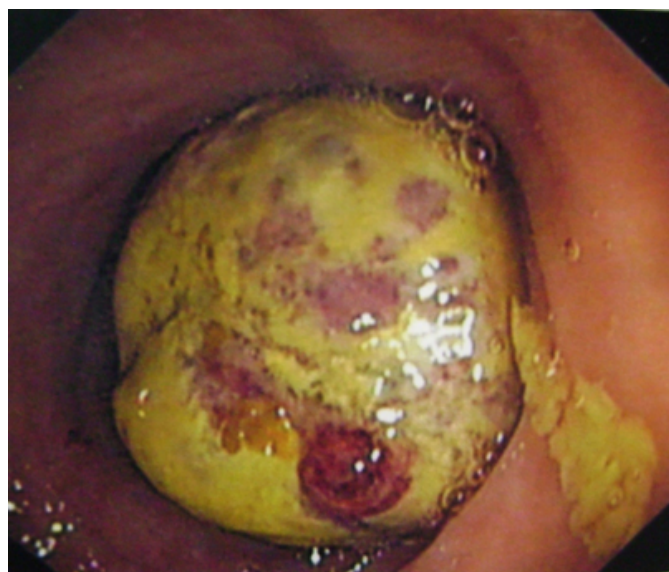

Figure 3

Figure-3: CT scan of the abdomen shows a colonic mass (33 x 21 x 35mm) in the descending colon



DISCUSSION

Non-Hodgkin lymphoma is the third most common malignancy in childhood. Along with Hodgkin lymphoma it constitutes 15% of all malignancies in childhood [5]. Non-Hodgkin lymphoma is more common than Hodgkin lymphoma in this age groups and it occurs in the abdomen in approximately 35% of cases. Children with certain immunodeficiency syndromes are known to have predisposing factors for development of Non-Hodgkin lymphoma [6]. In children, the most common gastrointestinal lymphoma is located in the ileocecal junction as compared with adults in which the most common site is stomach. Descending colon and sigmoid colon are very uncommon sites for involvement of Non-Hodgkin lymphoma and only one case in a child has been described in world literature [7]. Boys are 5 to 10 times more frequently affected than girls and the peak incidence is between 5 and 8 years of age [7]. Mucosa-associated lymphoid tissue (MALT) lymphoma is the most frequent colonic lymphoma [8] and usually appears as an isolated polyp [9]. Although a causal effect has been identified in adults as to the development of a mucosa-associated lymphoid tissue (MALT) lymphoma from infection with *H. pylori*, no formal causation has been proven in children. With surgery or chemotherapy, the prognosis generally is good. Surgical treatment before chemotherapy is indicated in cases where MALT lymphoma affects only a short segment of the colon [10]. EUS is helpful and may demonstrate extension of the colonic lymphoma, including involvement of adjacent lymph

nodes [10]. Multiplicity of colonic polyps is typical of multiple lymphomatous polyposis, a mantle-cell lymphoma. The GI tract is affected in 20% of cases of mantle-cell lymphoma. Characterized by dysregulation of the cell cycle by upregulation of cyclin D1, the prognosis for patients with mantle-cell lymphoma is worse than that for patients with MALT lymphoma [11]. Thus, the differential diagnosis of multiple colonic polyps should include both multiple lymphomatous polyposis and MALT lymphoma with multiple polypoid lesions.

The most common presentations of symptoms are abdominal pain and abdominal mass but bowel obstruction, intussusceptions, perforation, and/or bleeding can be present in the form of complications. Imaging tests can not detect lesions in early stages and tests are often nonspecific but ultrasound of the abdomen can detect the mass-like lesion. The correct preoperative diagnosis is obtained only by colonoscopic biopsy or excisional biopsy of the lesion by laparotomy.

Surgery is an important treatment modality for primary intestinal NHL because resection can reduce tumor burden and prevent hemorrhage, perforation, and secondary infection caused by chemotherapy-induced tumor necrosis [12]. The early diagnosis is important in all cases of children with bleeding per rectum and colonoscopy with biopsy, supplemented by imaging study, should be done to confirm the lesion and prolong survival by surgery and chemotherapy.

References

1. LaQuaglia MP, Stolar CJ, Kralio M, et al. The role of surgery in abdominal non-Hodgkin's lymphoma: experience from the Children's Cancer Study Group. *J Pediatr Surg* 1992; 27: 230-235.
2. Wong MTC, Eu KW. Primary colorectal lymphomas. *Colorectal Disease* 2006; 8: 586-591.
3. Bethel CA, Bhattacharyya N, Hutchinson C, et al. Alimentary tract malignancies in children. *J Pediatr Surg* 1991; 32: 1004-1009.
4. Lee J, Kim WS, Kim K, et al. Intestinal lymphoma: exploration of the prognostic factors and the optimal treatment. *Leuk Lymphoma* 2004; 45: 339-44.
5. Poplock DG, Cassafy JR, Pizzo PA. Leukemia and lymphoma of childhood, *Cancer: Principle and Practice of Oncology*. Eds.: de Vita VT, Hellman S, Rosenberg GA, Philadelphia, JB Lippincott; 1985.
6. Frizzera G, Rosai J, Denher LP et al. Lymphoreticular disorder in primary immunodeficiencies; new finding based on up to date histologic classification of 35 cases. *Cancer* 1982; 49: 1135-41.
7. Sigmund G, Wimmer B, Zimmerhackl LB, Waninger J, Böhm N. Non-Hodgkin's lymphoma of the descending colon in a 6-year-old girl. *Monatsschr Kinderheilkd* 1989; 137: 787-90.
8. Shepherd NA, Hall PA, Coates PJ, Levison DA. Primary malignant lymphoma of the colon and rectum. A histopathological and immunohistochemical analysis of 45 cases with clinicopathological correlations. *Histopathology* 1988; 12: 235-252.
9. Schmid C, Vazquez JJ, Diss TC, Isaacson PG. Primary B-cell mucosa-associated lymphoid tissue lymphoma presenting as a solitary colorectal polyp. *Histopathology* 1994; 24: 357-362.
10. Yoshimura D, Maruoka A, Maekawa S, Yao T, Harada N, Nawata H. Transverse colonic MALT lymphoma with nodal metastasis. *Gastrointest Endosc* 2002; 55: 238-239.
11. Yatabe Y, Nakamura S, Nakamura T, Seto M, Ogura M, Kimura M, et al. Multiple polypoid lesions of primary mucosa-associated lymphoid-tissue lymphoma of colon. *Histopathology* 1998; 32: 116-125.
12. Pandey M, Kothari KC, Wadhwa MK, et al. Primary malignant large bowel lymphoma. *Am Surg* 2002; 68: 121-126.

Author Information

Punit Srivastava

Senior Resident, 1. Department of Pediatric Surgery IMS

A. N. Gangopadhyay

Prof., 1. Department of Pediatric Surgery IMS

D. K. Gupta

Prof., 1. Department of Pediatric Surgery IMS

Vijay D. Upadhyaya

Pool Officer, 1. Department of Pediatric Surgery IMS

S P Sharma

Reader, 1. Department of Pediatric Surgery IMS