

# CD34-positive Fibroma of the Lip

J Wang, D Sarma

## Citation

J Wang, D Sarma. *CD34-positive Fibroma of the Lip*. The Internet Journal of Dermatology. 2007 Volume 6 Number 2.

## Abstract

We are reporting a case of CD34-positive fibroma of the lip. English literature is briefly reviewed.

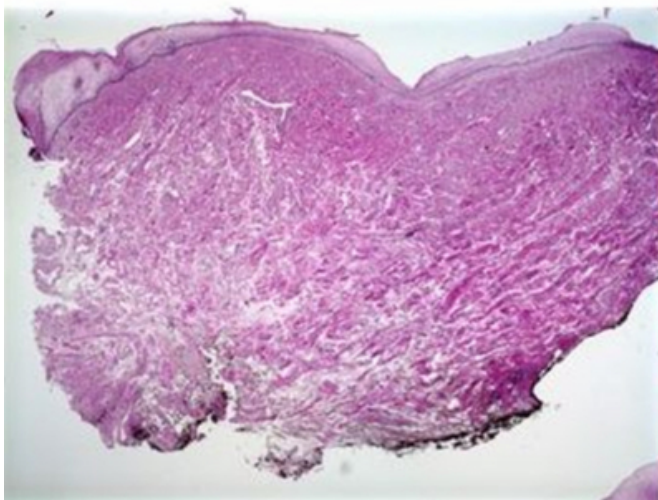
## CASE REPORT

A 56-year-old female presented with a slightly raised nodule on the lower lip measuring 0.7 x 0.7 cm. This lesion was noted by the patient for about a month. There was no history of trauma or previous biopsy at this site. An excisional biopsy was performed.

Microscopically, the lesion showed a dermal benign fibrotic and hyalinized nodule with overlying normal epidermis (Figure 1A). The hyalinized lesion was composed of acellular fibrocollagenous tissue with few stellate fibroblastic cells containing small dark spindle-shaped nuclei (Figure 1B). The stellate fibroblastic cells were strongly positive for CD34 (Figure 2B) and Vimentin (Figure 2B) but were negative for S-100 protein, SMA, and CD31.

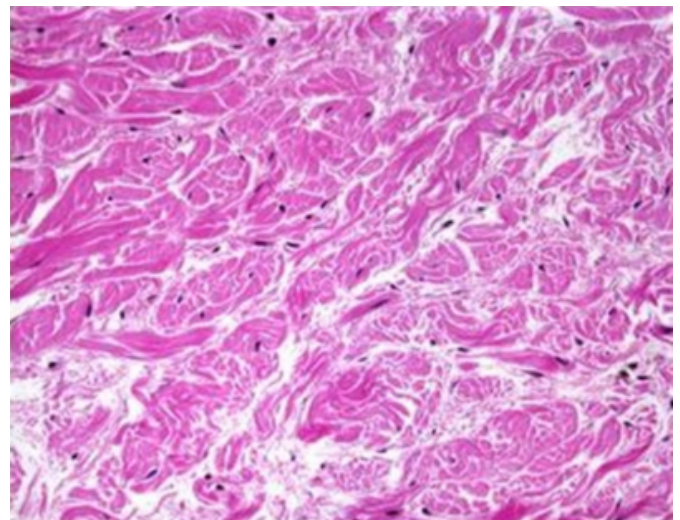
## Figure 1

Figure 1A: Normal epidermis, dermal nodule.



## Figure 2

Figure 1B: Dermal tumor



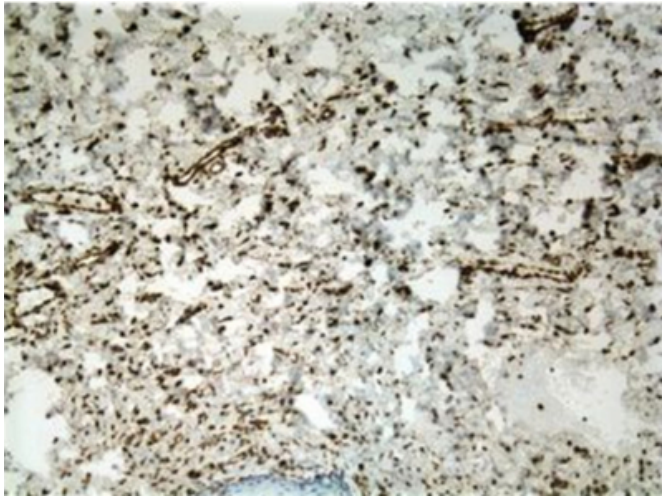
## Figure 3

Figure 2A: CD34 positive.



**Figure 4**

Figure 2B: Vimentin positive



**COMMENT**

Fibromas occur in any area of the oral mucosa but are most often located on the palate, tongue, cheek, or lip. They typically appear as pink or white elevated submucosal nodules. When such lesions are traumatized, they may appear reddish or blue. They tend to have a smooth surface and may be round, oval or elliptical in shape. The size of a fibroma can vary from a few millimeters to about 2 centimeters. A CD34-positive fibroma is a rare entity. Such a tumor may cause a diagnostic confusion with other CD34-

positive cutaneous tumors including sclerotic fibroma [1], solitary fibrous tumor, eruptive CD34-positive fibroma [2], pleomorphic fibroma [3], dermatofibrosarcoma protuberans [4], and Kaposi's sarcoma. Most of these lesions can be excluded by the clinical finding, histologic appearance and results of immunohistochemical stains. CD34-positive fibroma is considered a benign, non-recurrent dermal neoplasm, a subset of cutaneous or mucosal fibromas.

**CORRESPONDENCE TO**

Deba P Sarma, M.D. Department of Pathology Creighton University Medical School Omaha, NE 68131  
debasarma@creighton.edu

**References**

1. Alawi F, Freedman PD. Sporadic sclerotic fibroma of the oral soft tissues. *Am J Dermatopathol* 2004; 26:182-187.
2. Pursley HG, Williford PM, Groben PA, White WL. CD34-positive eruptive fibroma. *J Cutan Pathol* 1998; 25:122.
3. Rudolph P, Schubert C, Zelger B, Parwaresch R. Differential expression of CD34 and Ki-M1p in pleomorphic fibroma and dermatofibroma with monster cells. *Am J Dermatopathol* 1999; 21:414.
4. McNiff JM, Subtil A, Cowper SE, Lazova R, Glusac EJ. Cellular digital fibromas: distinctive CD34-positive lesions that may mimic dermatofibrosarcoma protuberans. *J Cutan pathol* 2005; 32:413-418.

**Author Information**

**Jeff Wang, M.D.**

Resident of Pathology, Creighton University Medical Center

**Deba P. Sarma, M.D.**

Professor of Pathology, Creighton University Medical Center