

Demonstration Of Loculated Spinal CSF Leak By Radionuclide Cisternogram And MRI

V Vijayakumar, M Anderson

Citation

V Vijayakumar, M Anderson. *Demonstration Of Loculated Spinal CSF Leak By Radionuclide Cisternogram And MRI*. The Internet Journal of Nuclear Medicine. 2004 Volume 2 Number 1.

Abstract

Trauma is a common cause of spinal CSF leak. Other causes that are associated with spinal CSF leak include spinal injury due to fracture or stab wound, epidural anesthesia, lumbar puncture, spontaneous, bronchopleural fistula due to bronchogenic carcinoma. Traumatic CSF leaks are more common in the cervicothoracic and the thoracic spinal area. Spinal CSF leak can lead to infection, intracranial hypotension and headache. Radionuclide cisternogram plays an important role in the localization of spinal CSF leaks.

CASE REPORT

The patient is a 63-year-old male with H/o Cervical stenosis and radiculopathy underwent C3-C6 decompression and instrumentation. The patient developed postoperative spinal CSF leak which was surgically repaired. He presented with recurrent spinal CSF leak. An MRI and radionuclide cisternogram were obtained to localize the leak.

Figure 1

Figure 1: Radionuclide cisternogram using In-111 DTPA demonstrating spinal CSF collection at the cervicothoracic level (arrow).

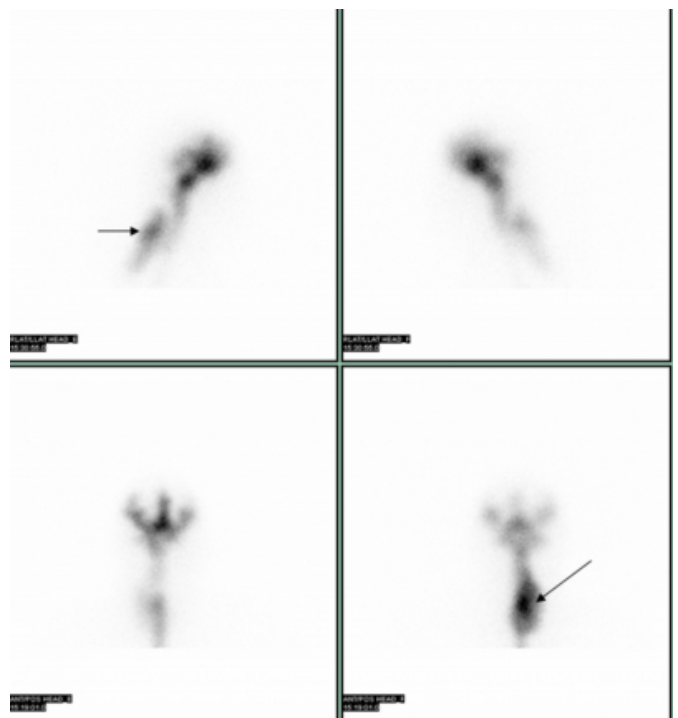
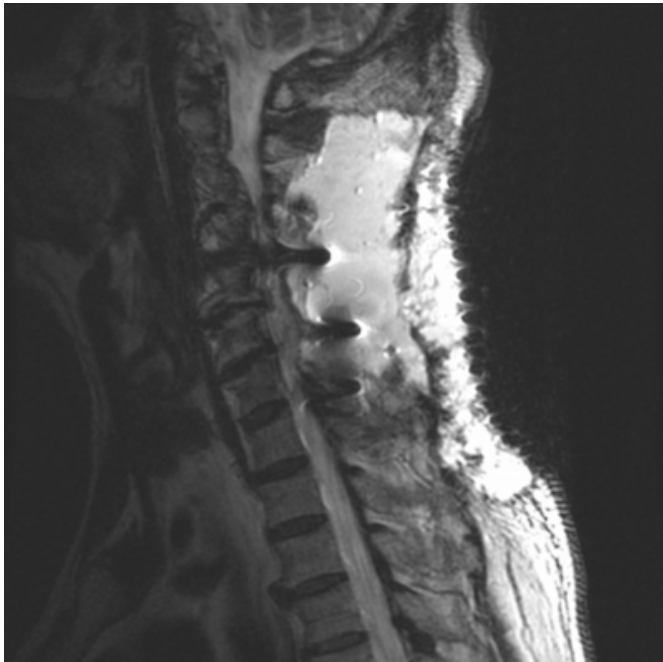

Figure 2

Figure 2: Sagittal MRI demonstrating post operative changes from C2 thru C7 and fluid collection within the posterior soft tissues spanning C2 thru T2.



DISCUSSION

Radionuclide cisternogram is usually performed in confirming the diagnosis of normal pressure hydrocephalus and CSF otorrhea or rhinorrhea in basal skull fractures. However, it has been shown to be of great value as demonstrated in our case and complimentary to MRI in

characterizing the spinal CSF leaks and defining exact location. Spinal trauma from several causes lead to spinal CSF leak (^{1,2,3,4,5,6}). Some times CT myelography may falsely localize the site of leak which is causing spontaneous intracranial hypotension (6). Radionuclide cisternogram is helpful in those circumstances. Spinal CSF leaks are mostly self-limiting. Persistent leaks with symptoms and associated complications require surgical repair.

CORRESPONDENCE TO

Vani Vijayakumar, MD Clinical Science Bldg, Rm 2.474
301 University Blvd. Galveston, TX 77555-0793 Tel:
409-772-8016 Fax: 409-747-2860 Email:
vavijaya@utmb.edu

References

1. Ali SA, Cesani F, Zukermann JA, et al: Spinal-cerebrospinal fluid leak demonstrated by radiopharmaceutical cisternography. Clin Nucl Med. Mar 1998;23:152-5.
2. Harrington H, Tyler HR, Welch K: Surgical treatment of post-lumbar puncture dural CSF leak causing chronic headache. J Neurosurg. Nov 1982;57:703-7.
3. Agrillo U, Simonetti G, Martino V: Postoperative CSF problems after spinal and lumbar surgery. J Neurosurg Sci. Apr-Jun 1991;35:93-5.
4. Bai J, Yokoyama K, Kinuya S, et al: Radionuclide cisternography in intracranial hypotension syndrome. Ann Nucl Med. Feb 2002;16:75-8.
5. Chan BO, Paech MJ: Persistent cerebrospinal fluid leak: a complication of the combined spinal-epidural technique- Anesth Analg 2004 98 828-30
6. Schievink WI, Maya MM, Tourje J: False localizing sign of C1-2 cerebrospinal fluid leak in spontaneous intracranial hypotension .J Neurosurg 2004 100: 639-44

Author Information

Vani Vijayakumar, M.D.

Nuclear Medicine Section, Department of Radiology, UTMB

Matthew E. Anderson, M.D.

Nuclear Medicine Section, Department of Radiology, UTMB