

# Cake kidney associated with uterine anomaly

? Kenan, C Birsen

## Citation

? Kenan, C Birsen. *Cake kidney associated with uterine anomaly*. The Internet Journal of Urology. 2006 Volume 5 Number 1.

## Abstract

Cake kidney associated with uterine anomaly is extremely rare genito-urinary anomaly. A 31-year-old female who has cake kidney with uterine anomaly(uterus bicornis unicollis) were presented. Ultrasonography, intravenous urography, computed tomography, magnetic resonance imaging and renal scintigraphy were used for diagnosis. Uterine anomaly was diagnosed with magnetic resonance imaging and histerosalphingography. Surgical intervention was not required due to no complications. Long-term follow-up was recommended to patient to determine future complications such as obstruction, infection, or calculi.

## INTRODUCTION

Cake kidney is one of the rarest urinary system anomaly. Only a few more than twenty cases of cake kidney have been described to date in the english literature. It can be diagnosed at any age of group, from childhood to the eightieth decade of life[<sub>1</sub>]. Most cases of renal ectopia remain asymptomatic during life and are diagnosed incidentally. Renal ectopia can be associated with other congenital anomalies including genitourinary, musculoskeletal, gastrointestinal and cardiovascular systems[<sub>2</sub>]. However, the association of cake kidney and uterine anomaly( uterus bicornis unicollis) has not been reported in the english literature. In this report, we present a case who has a cake kidney associated with uterine anomaly.

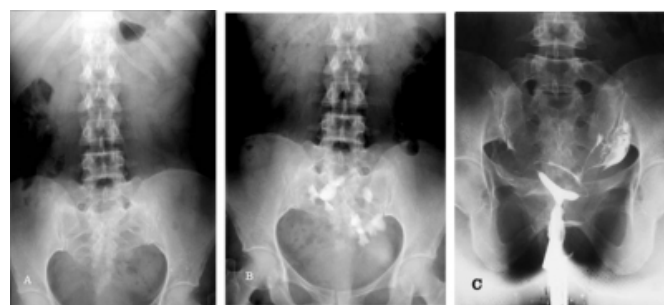
## CASE REPORT

A 41-year-old female presented with abdominal pain, dysuria and pollacuria. There was a previous history of ureteral stone. Physical examination revealed slight tenderness on the pelvic region. Laboratory studies including blood count, blood chemistry were normal. Urine samples showed microscopic haematuria and pyuria; however, urine culture yielded no significant colonization. The ultrasound of the abdomen(US) and pelvis failed to locate the kidneys in their normal position instead these were found in the pelvis beyond the bladder as one single mass of renal tissue. Intravenous urography( IVU )(Fig.1A, B), magnetic resonance imaging(MRI) and computed tomography (CT) (Fig.2A,B) were performed for further classification of the sonographic findings and these too demonstrated a single pelvic cake kidney with mild dilated collecting system. The

bladder and rest of the abdominal viscera were normal. MRI was diagnosed uterine anomaly(uterus bicornis unicollis) and this diagnosis was confirmed by histerosalphingography(HSG)(Fig.1C). Echocardiography was normal. Immediate and delayed images of Tc- 99m DMSA showed kidney with well functioning. Although a minimal radiopharmaceutical stasis was demonstrated in the kidney, this activity disappeared after diuretic administration(Fig. 3).

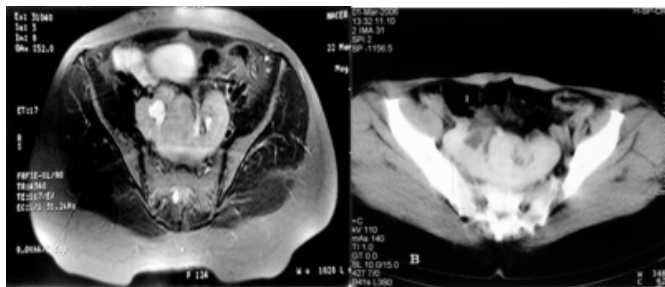
## Figure 1

Figure 1: IVU is showing pelvic cake kidney and HSG is demonstrating uterus bicornis unicollis



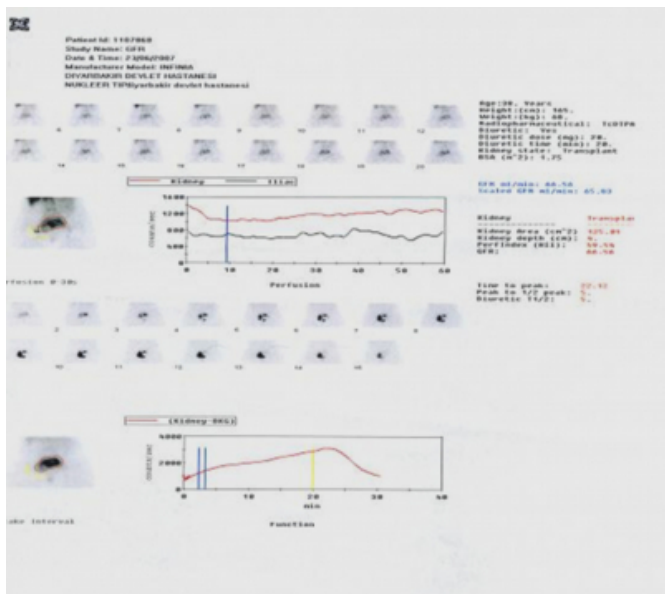
**Figure 2**

Figure 2: MRI is showing cake kidney



**Figure 3**

Figure 3: Tc- 99m DMSA scintigraphy is demonstrating cake kidney with well functioning kidney.



## DISCUSSION

The synonymous term cake kidney, fused pelvic kidney or lump kidney is defined as an anomaly in which 'the entire renal substance is fused into one mass, lying in the pelvis, and giving rise to two separate ureters which enter the bladder in normal relationship'. It takes its blood supply from adjacent vessels, and its ureter is short<sup>[3]</sup>. Rarely, It may be drained by a single ureter<sup>[1,3]</sup>. Urinary tract diseases such as vesicoureteral reflux, urinary infections, ureterocele, renal calculi, and renovascular hypertension can be associated with ectopic kidneys, which are likely to be complicated by ureteropelvic junction obstruction because of their frequent abnormal shape, malrotation and aberrant vasculature<sup>[4]</sup>. Cake kidney anomaly occurs at an early phase in the embryological development. During the formation of a cake kidney, the nephrogenic blastemas would be compressed between the umbilical arteries at the

beginning of the cranial migration of the ureteral buds, and this would leads to their fusion Fused kidneys, such as the cake kidney, are prevented from ascending and remain in an ectopic pelvic position<sup>[5]</sup>.

From 20% to 66% of women with renal ectopia have abnormalities of either the uterus (unicornuate with or without rudimentary horn, bicornuate, or absent uterus), vagina (atresia of the proximal or distal vagina, vaginal duplication, or absence of vagina), or both<sup>[6]</sup>. Uterine anomalies are consistent with anomalies of fusion of the paramesonephric ducts. Lack of fusion of the paramesonephric ducts in a localized area or along the length of the ducts cause different types of uterine malformations. Fusion is usually completed by the eighteenth week of fetal life. Total or partial failure of mullerian duct fusion represents approximately 75% of uterine anomalies. A partial or complete failure of the lower parts of the two paramesonephric ducts (Müller) to fuse or an incomplete development (atresia) of one of two paramesonephric ducts is responsible for the formation of a uterus bicornis uni- or bicornis with or without doubling of the vagina. The uterus bicornis unicollis is characterised by: single vagina, single cervix, double, single-horned uteruses which are partially fused<sup>[7]</sup>.

Imaging plays an important role in the diagnosis of this condition. US is the preferred radiologic modality for detecting the condition because it is noninvasive, involves no ionizing radiation, usually is readily available, and is less expensive than either CT or MRI. However, on US, overlying abdominal gas may obscure a portion of the fused kidneys or other anomalies making precise diagnosis difficult. IVU shows the true position of the kidneys. CT and MRI can be performed to further classification of the ultrasonographic findings. MRI can help evaluate the urinary tract for concomitant anomalies. It provides high-resolution images of the uterine body, fundus, and internal structure<sup>[4,7]</sup>. Renal scintigraphy can show the location of functioning kidneys, and placing the patient in multiple position during scintigraphy has been used to differentiate between fused and unfused forms of ectopic kidney<sup>[3,4]</sup>.

No intervention is required, except in cases of associated vesicoureteric reflux, for which possible ureteral reimplantation may be performed. In cases involving obstruction, pyeloplasty is possible in the treatment of ureteropelvic junction obstruction<sup>[6]</sup>.

In this case, the diagnosis was made by ultrasonography and

intravenous urography, and the diagnosis was confirmed by MRI and renal scintigraphy. Patient was investigated for other anomalies associated with cake kidneys. Uterine anomaly was diagnosed by MRI and histerosalphingography(HSG). Surgical intervention was not required. Long-term follow-up was recommended to the patient because of future complications such as obstruction, infection, or calculi.

## **CONCLUSIONS**

Cake kidney associated with uterine anomaly is extremely rare genito-urinary anomaly. US, IVU, CT, MRI and renal scintigraphy and HSG are the imaging methods used for diagnosis. When a cake kidney was determined, associated anomalies with cake kidney should be investigated. No treatment is required unless there are other complications or superimposed pathologies. Follow-up is important to determine future complications.

## **CORRESPONDENCE TO**

Kenan isen Ofis cami sok. Ayyıldız Apt.,kat: 5 no:15  
Diyarbakır, TR-21100, TURKEY Tel:+90.532.6180293 E-mail: kenanisen@hotmail.com

## **References**

1. Calado AA, Macedo A, Srougi M: Cake kidney drained by single ureter. *Int Braz J Urol* 2004; 30: 321-322.
2. Nursal GN and Buyukdereli G: Unfused renal ectopia: a rare form of congenital renal anomaly. *Annals of Nuclear Medicine* 2005; 19: 507-510.
3. Martínez-Lázaro R and Cortés-Blanco A: Cake kidney drained by single ureter: MAG3 renogram for diagnosis and function follow-up. *Nephrol Dial Transplant* 2000; 15: 1700-1701.
4. Felzenberg J, Nasrallah P: Crossed renal ectopia without fusion associated with hydronephrosis in an infant. *Urology* 1991; 38: 450-452
5. Brock JW 3rd, Braren V, Phillips K, Winfield AC: Caudal regression with cake kidney and a single ureter: a case report. *J Urol* 1983; 130: 535-536.
6. Bauer SB: Anomalies of the kidney and uretero-pelvic junction; in Walsh PC, Retik AB, Vaughan ED Jr, Wein AJ (eds): *Campbell's urology*. Philadelphia, Saunders, 1998, pp 1708 -1755.
7. Weissleder R, Rieumont MJ, and Wittenberg J: *Primer of Diagnostic Imaging*, ed 2, Mosby, St. Louis, 1997.

**Author Information**

**?sen Kenan, M.D.**

Clinic of Urology, State Hospital of Diyarbakır

**Cihan Birsen, M.D.**

Clinic of Radiology, State Hospital of Diyarbakır