

Light aneurismal coiling with satisfactory obliteration on follow up, a case report, is it a matter of full compaction or flow dynamic changes?

O Mansour, M Khalil, J Weber, M Schumacher

Citation

O Mansour, M Khalil, J Weber, M Schumacher. *Light aneurismal coiling with satisfactory obliteration on follow up, a case report, is it a matter of full compaction or flow dynamic changes?*. The Internet Journal of Interventional Medicine. 2009 Volume 1 Number 1.

Abstract

Aims: The demonstration of aneurysm lumen thrombosis and with satisfactory diversion of flow hemodynamics with the use of a minimum number of coils in the treatment of hemorrhagic cerebral aneurysms. Hence attracting the attention to the importance of flow dynamic changes as predictor of successful aneurysm obliteration. . However I would not suggest partial coiling of aneurysms as a preferred treatment modality for these malignant lesions.

Case: We present a 59-year-old male teacher who underwent endovascular treatment for acute subarachnoid haemorrhage due to a giant basilar tip aneurysm (BTA) and left ophthalmic aneurysm. Following deployment of two of the longest available coils, the procedure was terminated due to a sudden change of jet flow within the aneurysm and unsustainable coil positions in spite of further attempts. Post-procedural follow-up angiograms in day 30 revealed an approximately total occlusion of the giant basilar tip aneurysm. **Imaging/ Discussion:** Significant change in flow dynamics by minimum number of coils can achieve significant flow reduction and near complete thrombosis and occlusion of a giant basilar tip aneurysm.

INTRODUCTION

The degree of stress to which an aneurysm wall is subjected is related to the aneurysm volume. For elastic material Laplace's law defines the relationship between wall tension (eg, in a balloon), internal fluid pressure, and radius or volume. That is, without fluid pressure changes there will be no changes in wall tension. In an aneurysm an acute volume increase and stretching of the aneurysm wall can of course occur as a result of overpacking an aneurysm with solid material or creation of separated compartment with increase inflow pressure .

CASE

A 59-year-old male was referred to our institution due to diffuse subarachnoid haemorrhage with blood in the interpeduncular and prepontine cisterns and at the level of foramen magnum. There was no evidence of intraventricular blood or hydrocephalus. CT angiogram (fig.1) and preoperative digital subtraction angiogram (DSA) (fig.2) confirmed a 25 mm basilar tip aneurysm (BTA) showing a small daughter distally. The origins of both posterior cerebral arteries were incorporated in the neck of the basilar

tip aneurysm (BTA). There was also a 5mm left carotico-ophthalmic aneurysm. It was decided that both aneurysms should be coiled. Following standard heparinising and micro catheter navigation of the basilar tip aneurysm, an GDC-18 360° Standard 18x24 mm x40 cm and an 18x 18 mm x 30 cm Guglielmi detachable coil (GDC) was deployed within the aneurysm lumen. However, in spite of attempts to deploy further coils (microsphere), a change in tip stability of the microcatheter within the sac combined with high flow turbulence prevented stable further coil positioning (fig.2) . Meanwhile jet flow within the aneurysm lumen was dramatically reduced (fig. 2). As a result further coiling of this aneurysm was abandoned and three coils deployed into the left carotico-ophthalmic aneurysm. The patient woke up with no significant deficit. The patient underwent MRI examinations (fig.4) on post-operative day one and in the second week and a DSA on day 30 post operatively (fig. 3). The basilar tip aneurysm had approximately 90% occlusion with a small neck remnant and both posterior cerebral arteries were preserved (. 18 month follow up MRA shows further thrombosis and reduction in the size of neck remnant. The patient will continue to undergo annual monitoring for

evidence of recurrence for the next few years.

Figure 1

Figure 1: This is the initial CT angiogram showing axial, and sagittal images of the 25 mm basilar tip aneurysm.

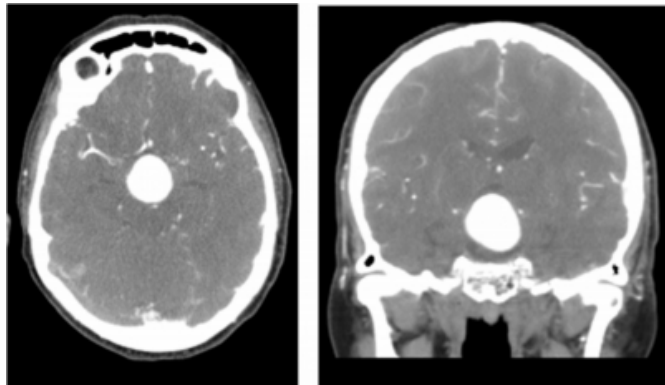
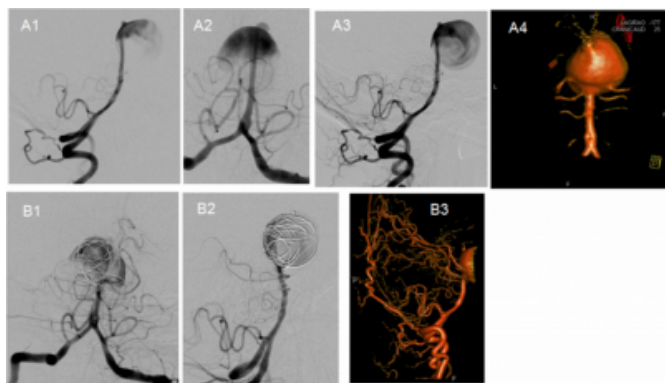


Figure 2

Figure 2

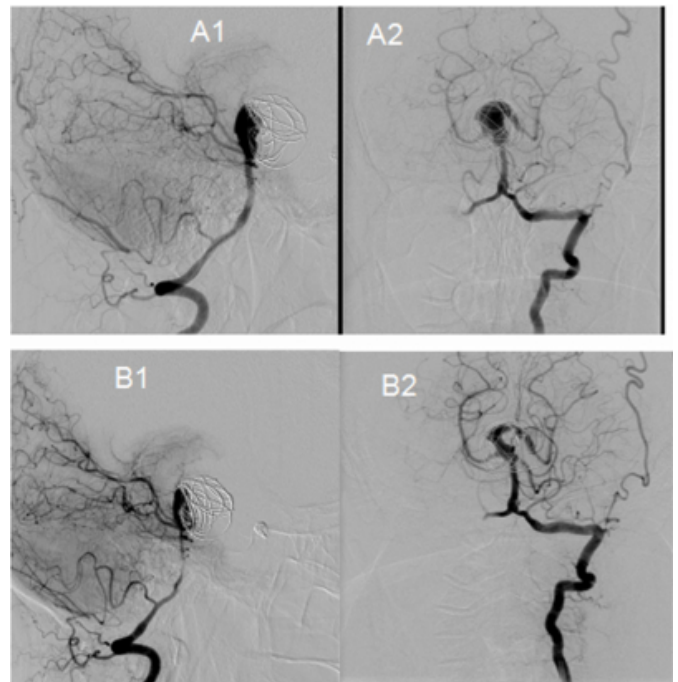


Pre coiling images: (A1) (lateral) and (A2) (AP) show the jet into the aneurysm pre –coiling. (A3) Shows the vortex within the aneurysm pre-coiling. (A4) 3D DSA shows the origins of the posterior cerebral arteries (PCA) from the aneurysm sac and the superior cerebellar arteries (SCA) from the neck of the aneurysm.

Post-coiling images: (B1) (AP) and (B2) (lateral) show two coils within the aneurysm sac and continued filling. The inflow jet is partly disrupted. (B3) shows continued PCA and SCA flow.

Figure 3

Figure 3

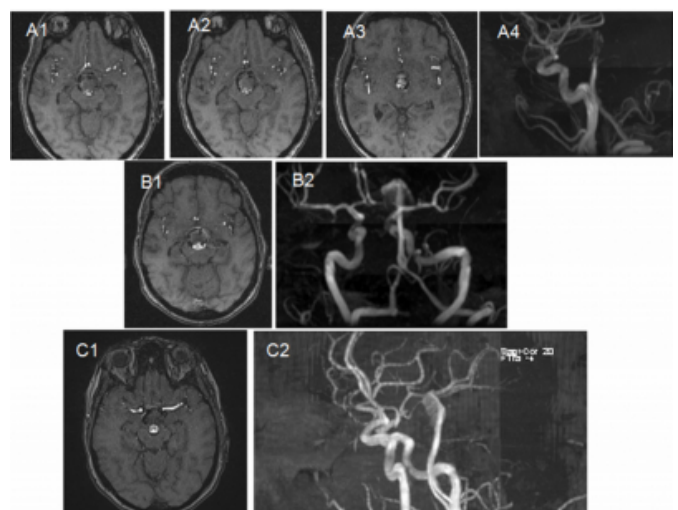


A1 & 2: DSA at four weeks post embolization. It shows increasing thrombosis of the aneurysm

B1 & 2 DSA – at three months shows there has been further thrombosis in the aneurysm neck.

Figure 4

Figure 4



A 3D TOF MRI: One day post procedure MRI. A1-A3 show the aneurysm from inferior to superior and demonstrates continued but reduced flow into the aneurysm. The aneurysm is partially obliterated . A4 shows the major areas of filling on 3D TOF.

B: 3D TOF MRI: One month post-procedure shows reduced filling of the aneurysm compared to A1-4.

C: 3D TOF MRI: eighteen months post procedure. This shows decreased filling of the remnant of the aneurysm compared to the previous imaging as the aneurysm continues to thrombose.

DISCUSSION

The formation of aneurysms is related to haemodynamically induced vascular injury which is especially likely to happen in large intracranial vessels at bifurcations where there are large shear stresses (Renowden and Molyneux 1995). Atherosclerosis also has a role to play in the formation of fusiform aneurysms.

Very large and giant cerebral aneurysms have a poor natural history with a high risk of sub-arachnoid haemorrhage, progressive symptoms due to mass effect and compromise of the critical vessels that arise from this region. Giant vertebrobasilar tip aneurysms are especially difficult to treat surgically and are often considered inoperable. The natural history of giant aneurysms has been reported to be ominous (Wiebers, Whisnant et al. 2003). In patients with advanced age and history of rupture, surgical morbidity of bypass, need for general anesthesia and postsurgical recovery are all important considerations. Endovascular techniques for treatment of giant aneurysms are evolving due to the increase in understanding of flow dynamics and parent vessel-aneurysm biology, advancements in technology and an increase in experience of the operator. Hence, endovascular interventions have become the treatment of choice in many situations (Horie, Kitagawa et al. 2007).

Shortly after the introduction of coils it was obvious why to believe thrombus formation started within the deployed coil and propagated through the aneurysm. This was believed to depend on complete obstruction of the inflow zone, displacement of the inflow zone and complete luminal filling.

However, this concept has changed with both the empirical demonstration of reduction of the inflow jet and thrombus formation distant to the coil and computer fluid dynamic models showing how the introduction of a coil can induce stasis within an aneurysm. The concept of flow diversion as an important adjunct to the thrombogenic nature of the coil has become equally critical in the mechanism of aneurysm thrombosis.

On contrary and to support our postulation the hypothesis made by (Hauck EF et al. 2010) who although they achieved excellent obliteration of this aneurysm in the first instance with the endovascular waffle-cone technique which go in agreement with others experiences (Gruber, Ogilvy et al. 2010; Sychra, Klisch et al. 2010), however delayed follow-up clearly demonstrated a large recurrence where they postulated that waffle-cone treatment is not an optimal option selected which catalyzed the hemodynamics at play, particularly in patients with a strong inflow jet at the aneurysm neck. The authors concluded that the waffle-cone technique probably supports the dangerous hemodynamics that cause growth of such aneurysms and has a high chance of coil compaction at follow-up due to the water-hammer effect. With increasing realization of the concept of diverting flow away from the aneurysm neck to reconstruct the parent vessel and thus achieve aneurysm obliteration, the concept of using the waffle-cone technique is counterintuitive and probably has a high chance of recurrence and failure (Hauck EF et al. 2010).

In current case report, we could achieve significant thrombosis of this giant aneurysm (>25mm) with only two coils. These two coils presumably acted to divert flow and change the aneurysm dynamics resulting in thrombosis in a relatively short time period and at same time impacted on the procedure. Regarding the later flow dynamics induced changes, the tip of the microcatheter within the aneurysm became unstable resulting in an inability to place coils in the distal aspect of the aneurysm with the precision required to prevent protrusion from the wide-neck or occlusion of the critical vessels arising from the basilar artery aneurysm. Sub-complete thrombosis of the aneurysm spared the both SCA and PCA arising from the basilar aneurysm.

I would not suggest partial coiling of aneurysms as a preferred treatment modality for these malignant lesions. Indeed, residual aneurysms after coil embolization are also known to rerupture. That this lesion has not yet reruptured is fortuitous for the patient but also precarious for that patient's future health.

There is a significant quantity of work at present to understand how coiling effects aneurysm flow. Much of this work is going to try and plan for coiling prior to the procedure by predicting how coil placement will affect the aneurysm. This case report shows that significant thrombosis of a giant aneurysm can be achieved with partial coil embolization (Mitsos, Kakalis et al. 2008).

References

- r-0. Gruber, T. J., C. S. Ogilvy, et al. (2010). "Endovascular treatment of a large aneurysm arising from a basilar trunk fenestration using the waffle-cone technique." *Neurosurgery* 67(3 Suppl Operative): 140-144; discussion 144.
- r-1. Horie, N., N. Kitagawa, et al. (2007). "Giant thrombosed fusiform aneurysm at the basilar trunk successfully treated with endovascular coil occlusion following bypass surgery: a case report and review of the literature." *Neurol Res* 29(8): 842-846.
- r-2. Hauck EF, Natarajan SK, Hopkins LN, et al. (2010). "Salvage Neuroform stent-assisted coiling for recurrent giant aneurysm after waffle-cone treatment." *J NeuroIntervent Surg* (2010). doi:10.1136/jnis.2010.002931
- r-4. Mitsos, A. P., N. M. Kakalis, et al. (2008). "Haemodynamic simulation of aneurysm coiling in an anatomically accurate computational fluid dynamics model: technical note." *Neuroradiology* 50(4): 341-347.
- r-5. Renowden, S. A. and A. J. Molyneux (1995). "Thrombosis in giant basilar tip aneurysms during coil embolization." *AJNR Am J Neuroradiol* 16(4 Suppl): 866-871.
- r-6. Sychra, V., J. Klisch, et al. (2010). "Waffle-cone technique with Solitaire AB Remodeling Device: endovascular treatment of highly selected complex cerebral aneurysms." *Neuroradiology*.
- r-7. Wiebers, D. O., J. P. Whisnant, et al. (2003). "Unruptured intracranial aneurysms: natural history, clinical outcome, and risks of surgical and endovascular treatment." *Lancet* 362(9378): 103-110.

Author Information

Ossama Mansour, MD

Freiburg Uniklinik , Neuroradiology department , Germany

Mohamed Khalil

Tanta Neuro-endovascular center , Neurology Depart. , Tanta University , Egypt

J. Weber

Neuroradiology und Interventional Neuroradiology department Institut für Radiologie, Kantonsspital St.Gallen , Switzerland

M. Schumacher, MD

Freiburg Uniklinik , Neuroradiology department , Germany