

A patient complaining of hoarseness with an aneurysm of the aortic arch (Ortner's syndrome) and a left intrathoracic goiter

L Llerena, Y Marcos-Gutiérrez, V Mendoza-Rodríguez, E Olivares-Aquiles

Citation

L Llerena, Y Marcos-Gutiérrez, V Mendoza-Rodríguez, E Olivares-Aquiles. *A patient complaining of hoarseness with an aneurysm of the aortic arch (Ortner's syndrome) and a left intrathoracic goiter*. The Internet Journal of Radiology. 2008 Volume 9 Number 2.

Abstract

A male patient 51 years old was operated 5 years ago of prostate cancer with good results. Now he complains of hoarseness in the last 3 years and since one week of atypical chest pain. In an enhanced chest multidetector computed tomography, an aneurysm of the aortic arch and a left intrathoracic goiter were detected. It is not common the coincidence of an aneurysm of the aortic arch and a left intrathoracic goiter. Both are different expanding structures compressing the recurrent laryngeal nerve and each of them may explain hoarseness.

INTRODUCTION

The recurrent laryngeal nerve supplies almost all the muscles acting on the left vocal cord. The left vagus nerve descends into the superior mediastinum between the left common carotid and subclavian arteries. At the level of the aortic arch it gives rise to the left recurrent laryngeal nerve which course around the ligamentum arteriosum and ascends in the angle between the esophagus and trachea ¹.

If the nerve is compressed and/or stretched by an expanding structure during its trajectory, a paralysis of the left-sided vocal cord may develop and patient manifest clinically as hoarseness.

Hoarseness due to left-sided vocal cord paralysis as a result of a cardiovascular disease was first described by Ortner in 1897 ². Ortner's syndrome is also known as cardiovocal syndrome ³.

The Ortner's or cardiovocal syndrome is not frequent and it is related to different anomalous cardiovascular structures as aneurysms of the aortic arch ^{2,3,4}, aortic arch dissection ⁵, aneurysm of the ductus arteriosus ⁶ and dilatation of the left atrium ⁷.

Posterior intrathoracic goiters extending outside the thyroid bed are rare, making up 7% of all intrathoracic goiters. A small subset of them involving the left thyroid lobe may be found on the left mediastinal side compressing the trachea.

This type of goiter developing as downward extensions of the thyroid tissue is classified as secondary and also called substernal, particularly when more than 50% of the mass is below the suprasternal notch ^{8,9,10}. In opposition, primary intrathoracic goiters also referred to as aberrant or ectopic goiters arise as a result of abnormal embryologic migration of thyroid anlagen associated with the aortic sac. Primary intrathoracic goiters are exceedingly rare ¹¹. In this article we report a patient with an Ortner's syndrome due to an aortic arch aneurysm and in addition, he has a left side intrathoracic goiter.

CASE REPORT

A 51 years old man was operated 5 years previously of prostate cancer with good results and evolution. Now he complains of hoarseness in the last 3 years and since one week of atypical chest pain. At the beginning, a paralysis of the left vocal cord was diagnosed and on a chest X-Ray film a mild widening of the left border of the mediastinum with slight displacement of the trachea to the right was detected, but at that time he refused other studies.

Now he comes to our Institute complaining of atypical chest pain since one week. Hoarseness and paralysis of the left vocal cord persists with same characteristics. Physical examination was unremarkable including urological system. On a new chest X-Ray, widening of mediastinum has mildly increased. The ECG and transthoracic Echo were also

unremarkable.

An enhanced chest multidetector computed tomography (64 slices Somatom Sensation, Forchheim Siemens) demonstrates an aneurysm of the aortic arch (6.5 x 7.14 x 10.15 cm) with compression of the main pulmonary artery and its branches. A transthoracic goiter (2.69 x 5.37 x 4.33 cm) originating in the neck and extending through the left, with mild compression and displacement of the trachea was also detected. The goiter slightly compresses the aneurysm (Fig 1). Patient refused intervention. He was advised about risks and symptomatic treatment indicated.

Figure 1

Figure 1A) Axial projection at the level of aortic pulmonary window. B and C, sagittal projection. ANE: Aneurysm; G: Goiter

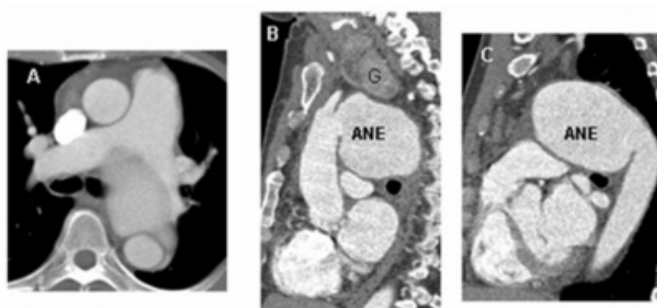
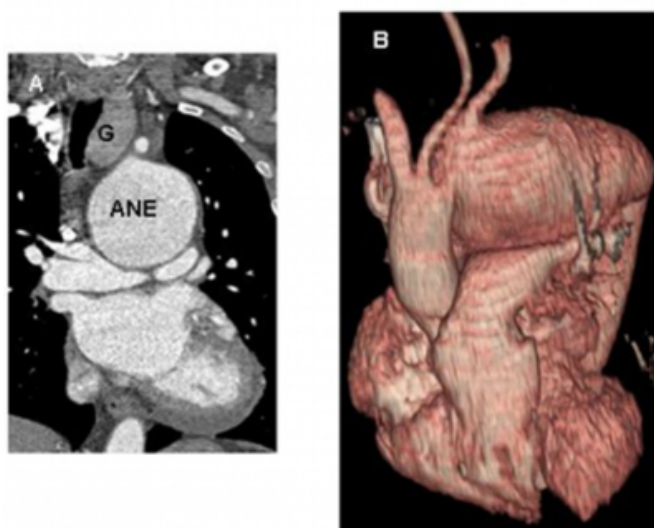


Figure 2

Figure 2A) Coronal projection. ANE: aneurism; G: goiter. B) Volume rendering technique



The space between the aortic arch and the main pulmonary artery and its branches is obliterated by the aneurysm. The trachea is displaced to the right by the goiter (Figure 2)..

DISCUSSION

The cardiovocal syndrome of our patient is easily explained by the aortic arch aneurysm that occupies the space between the aortic arch and the main pulmonary artery and its branches compressing the anatomical structures in that space as the left recurrent laryngeal nerve. Contrast enhanced thoracic computed tomography also disclosed the presence of a left mediastinal mass extending from the thoracic outlet, merging from the left thyroid lobe. Mediastinal masses with these characteristics may also compress the trachea and the left recurrent nerve producing hoarseness by paralysis of the left vocal cord. Upper respiratory symptoms are also frequently present ⁸¹⁰¹²¹³¹⁴.

Usually the diagnosis of a thoracic goiter is not difficult because the attenuation value of the unenhanced thyroid tissue is higher than surrounding structures and the mass appears homogeneous, radiopaque, smooth contoured and frequently separated by fat planes from neighbors structures. In addition after contrast administration, goiter is early and prolonged enhanced.

The association of aortic aneurysms and secondary substernal goiters is very rare in the literature ¹⁵¹⁶. In this patient two entities might contribute to produce the same symptom.

An embryologic explanation would be plausible in cases of primary goiters and aortic aneurysms due to the relation of thyroid anlagen and the aortic sac ¹¹

We conclude that the presence of an aneurysm of the aortic arch and a secondary goiter is an infrequent coincidence and both can explain the hoarseness of our patient.

CORRESPONDENCE TO

Prof. Luis Roberto Llerena. Instituto de Cardiología y Cirugía Cardiovascular. Calle 17 No. 702, El Vedado, Plaza, C. Habana, CUBA. 11400 Telephone: 8383845 e-mail: hemorx@infomed.sld.cu

References

1. Testut L, Latarjet A. Tratado de Anatomía Humana. 9th ed. Barcelona, Salvat; 1949 Tomo 3 p. 970-972.
2. Bickle IC, Kelly B E, Brooker DS. Case Report.Ortner's syndrome: a radiological diagnosis The Ulster Medical Journal 2002; 71:55-56.
3. Chan P, Lee CP, Ko JT, Hung JS. Cardiovascular (Ortner's) syndrome left recurrent laryngeal nerve palsy associated with cardiovascular disease. Eur J Med 1992; 1:492-495
4. Lydakakis C, Thalassinos E, Apostolakis S, Athousakis E, Michou E, Kontopoulou E. Hoarseness as imminent

symptom of aortic aneurysm rupture Ortner's syndrome. *Int Angiol.* 2006;25:231-233.

5. Matsumura N I, Yamamoto K, Takenaka H, Sumito Cho S. Hoarseness and Aortic Arch Dissection. *Inter Med.* 2008;47:473.

6. Kokotsakis J, Misthos P, Athanassiou T, Skouteli E, Rontogianni D, Lioulis A. Acute Ortner's Syndrome Arising from Ductus Arteriosus Aneurysm *Texas Heart Institute Journal* 2008; 35:216-217

7. Gulel O, Koprulu D, Kucuksu Z, Yazici M, Cengel S. Cardiovascular Syndrome Associated With Huge Left Atrium. *Circulation* 2007;115:e318-e319.

8. Chin SC, Rice H, Som PM. Spread of Goiters Outside the Thyroid Bed

A Review of 190 Cases and an Analysis of the Incidence of the Various Extensions. *Arch Otolaryngol Head Neck Surg.* 2003;129:1198-1202.

9. Al-Mufarrej F, Margolis M, Tempesta B, Strother e, Gharagozloo F. Novel thoracoscopic approach to posterior mediastinal goiters: report of two cases. *Journal of Cardiothoracic Surgery* 2008,

3:55doi:10.1186/1749-8090-3-55

10. Buckley JA, Stark P. Pictorial essay. Intrathoracic Mediastinal Thyroid Goiter: Imaging Manifestations. *AJR* 1999;173:471-475

11. Mack E. Management of patients with substernal goiters. *Surg Clin North Am* 1995;75:377-394

12. Shen WT, Kebebew E, Duh OY, Clarck OH. Predictors of airway complications after thyroidectomy for substernal goiter. *Arch Surg* 2004;139:650-660.

13. Vadasz P, Kotsis L. Surgical aspects of 175 mediastinal goiters. *Eur J Cardio-thoracic Surg* 1998;14:353-357.

14. Özpolat B, Büyükaşık O, Osmanoğlu CG, Doğan S, Kargıcı H. Is cervicotomy enough for removal of retrosternal goiters? *Turk J Med Sci* 2008; 38: 561-565

15. Matsuzaki K, Sakai K, Sugawara H, Okamoto F, Matano J, Nakanishi K, Narita Y. A case of ascending aortic aneurysm with intrathoracic goiter. *Kyobu Geka.* 2000;53:500-502 (Abstract).

16. Banker MC, Sambol J, Raina S. Management of an ascending aortic aneurysm with coronary artery disease and tracheal compression from a substernal goiter. *J Card Surg.* 2005;20:177-179.

Author Information

Luis Roberto Llerena, MD, PhD

Consultant Professor of Radiology, Institute of Cardiology and Cardiovascular Surgery

Yamilé Marcos-Gutiérrez, MD

Radiologist, Institute of Cardiology and Cardiovascular Surgery

Vladimir Mendoza-Rodríguez, MD

Cardiologist, Institute of Cardiology and Cardiovascular Surgery

Eddy W. Olivares-Aquiles, MD

Cardiologist, Institute of Cardiology and Cardiovascular Surgery