

Brevundimonas Vesicularis Bacteremia Following Allogeneic Bone Marrow Transplantation

B Vahid

Citation

B Vahid. *Brevundimonas Vesicularis Bacteremia Following Allogeneic Bone Marrow Transplantation*. The Internet Journal of Infectious Diseases. 2005 Volume 5 Number 1.

Abstract

Bacterial infection and sepsis is a major cause of morbidity and mortality after hematopoietic stem cell transplantation. We report a case of *Brevundimonas vesicularis* bacteremia in a patient following mismatched related donor peripheral blood stem cell transplantation (PBSCT).

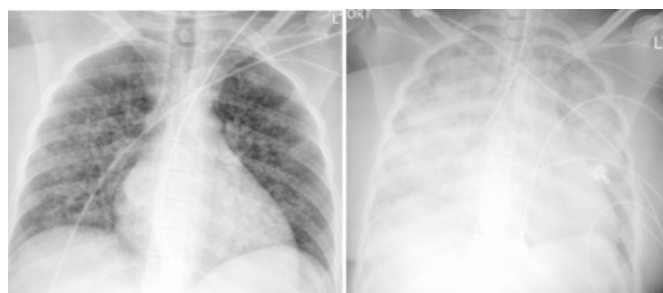
CASE REPORT

The patient was a 36 year-old African American woman with a two year history of acute myelogenous leukemia (AML). She was initially treated with an induction chemotherapy regimen of Idarubicin and Ara-C with only a partial response. She required a second course of chemotherapy with the same agents to achieve a complete remission. She received two additional courses of consolidation chemotherapy with high dose Ara-C after achieving full remission to maintain her in remission for 7 months. At that point a bone marrow biopsy with flow cytometry revealed evidence of recurrent disease. Autologous PBSCT was considered due to lack of an allogeneic marrow donor. Autologous PBSCT was performed following standard conditioning with Busulfan and Cytosan. Recurrence of AML was detected 6 months after autologous PBSCT and she underwent salvage chemotherapy with Etoposide and Mitoxantrone. One month later, she was in morphological remission but the cytogenetic analysis of the bone marrow was positive. Mismatched related donor PBSCT was performed. After her pancytopenia resolved she was discharged home. She was readmitted 45 days post transplant for evaluation of fever and cough of one day duration. On examination she was in respiratory distress with a respiratory rate of 30/min, temperature of 103°F, heart rate of 120 beats/min and a blood pressure of 75/40 mm Hg. Chest auscultation revealed bilateral diffuse crackles. Cardiac, abdominal and neurological examination was unremarkable. There were no indwelling intravascular devices. Two sets of blood cultures were obtained and she was started on empiric broad spectrum antimicrobial coverage including Vancomycin,

Meropenem, Amikacin, Amphotericin B and Gancyclovir. The initial chest radiograph showed bilateral diffuse bilateral air-space opacities (Figure 1a). She developed severe hypoxemic respiratory failure requiring intubation and mechanical ventilation. She required vasopressor therapy for hypotension unresponsive to fluid resuscitation. A diagnosis of Septic Shock and Acute Respiratory Distress Syndrome (ARDS) was made. Repeat chest radiograph showed progression of her bilateral parenchymal infiltrates (Figure 1b).

Figure 1

Figure 1: a) Chest radiograph on presentation showing bilateral patchy air-space disease. b) Chest radiograph five hours later showing rapid progression of air-space disease. Also note that the endotracheal tube is in the right main bronchus.



Unfortunately the patient died less than 24 hours after presentation. Sputum and tracheal aspirate cultures grew only normal flora. The two aerobic blood cultures grew a gram-negative rod after 5 days of incubation. The organism was oxidase positive, fermented only glucose and esculin, and produced yellow pigment on blood agar. *Brevundimonas vesicularis* was identified by MicroScan NBPC30 system,

which was resistant to Amikacin, Aztreonam, Cefepime, Ceftazidime, Ceftriaxone, Meropenem, Piperacillin-tazobactam, and Tobramycin. Intermediate activity was noted with Imipenem and Gentamicin. The organism was susceptible only to Ciprofloxacin and Ticarcillin-Clavulanate. We believe this case represents a case of *B vesicularis* bacteremia resulted in septic shock and ARDS. Although chest radiograph on admission showed patchy infiltrates consistence with pneumonia, we did not isolate the organism from sputum or tracheal aspirates. The source of bacteremia could not be identified.

DISCUSSION

Brevundimonas vesicularis was formerly classified as a member of group IV of the genus *Pseudomonas*, and was called *Pseudomonas vesicularis* (1). This organism is a slender, motile, aerobic, non-sporulating non-fermenting gram-negative rod (1, 2). The organism was first described in 1954, when Busing et al cultured it from the seminal vesicle of a leech (3). *Brevundimonas vesicularis* has been isolated from specimens obtained from various environmental sources including shower hoses (4), hydrotherapy pools (5), bottled non-carbonated mineral water (6), soil (7), and reprocessed dialyzers (8). Interestingly, *Brevundimonas* species has been isolated from the Russian space laboratory Mir (9). The organism has also been isolated from human specimens. Otto et al in 1978 found five strains of *B vesicularis*, isolated from cervical cultures of patients with cervicitis. The Centers for Disease Control in 1984 reported a collection of clinical isolates of *B vesicularis* from blood, cerebrospinal fluid, urine, eye, wound, and vaginal cultures (10). Human infection with *B vesicularis* is rare and only a few cases have been reported in literature (Table 1) (1,2,3, 7, 11,12,13). There are also two reports of *B vesicularis* bacteremia outbreaks due to use of formaldehyde-reprocessed dialyzers (8). To our best of knowledge, this is the first report of *B vesicularis* Bacteremia after peripheral blood stem cell transplantation.

In conclusion, *B vesicularis* bacteremia can present as fulminant septic shock. This is the first reported case of *B vesicularis* that is resistant to both Meropenem and Piperacillin-tazobactam. Although *B vesicularis* was resistant to ciprofloxacin in previously reported cases, in this case *B vesicularis* was susceptible to ciprofloxacin. Since extensive data on antibiotic sensitivity of *B vesicularis* is lacking, until more information is available ciprofloxacin should be considered in the antibiotic regimen in treatment of *B vesicularis* bacteremia while awaiting antibiotic

susceptibility results.

Figure 2

Table 1: Summary of clinical description of reported cases of *Brevundimonas vesicularis* infections in humans

Year/Reference	Age/Sex	Source	Underlying conditions	Clinical syndrome	Susceptibility
1992(2)	54/F	Blood	SLE, Autoimmune hepatitis	Cellulitis Septic shock	S: ampicillin, cefazolin, cefotaxim, cefotaxime, ceftriaxone, gentamicin, tobramycin, amikacin, doxycycline, cotrimoxazole R: piperacillin, ceftazidime
1994(3)	5/M	Blood	Sickle cell disease (hemoglobin SS)	Pneumonia	R: not reported S: ciprofloxacin, gentamicin, ceftazidime, ceftriaxone, carbenicillin, mezlocillin, piperacillin
1996(11)	60/M	Skin	Trauma	Botryomycosis	
1997 (12)a	L	Pericardial effusion	Immunosuppressed patient	Pericarditis	
2000(7)	42/F	Blood	Mitral valve replacement	Septicemia	R: ampicillin, Cefuroxime, ceftriaxone, ceftazidime, ciprofloxacin, aztreonam S: mezlocillin, piperacillin, aminoglycoside, cotrimoxazole, amoxicillin-clavunate, piperacillin-tazobactam, imipenem.
2004(13)b	F	Blood	Aplastic Anemia	Bacteremia	
2004(1)	38/M	Blood	None	Acute tonsillitis	R: ampicillin, aztreonam, cefazolin, ceftazidime, gentamicin, tobramycin, ciprofloxacin S: amoxicillin-clavunate, cefoperazone

a. Article is in Chinese, only abstract is available in English.

b. Article is in French, only abstract is available in English.

CORRESPONDENCE TO

Bobbak Vahid, MD Thomas Jefferson University 1015 Chestnut Street, Suite M-100 Philadelphia, PA 19107 Tel: 215 955-6591 Fax: 215 955-0830
Bobbak.vahid@mail.tju.edu

References

- Chi C, Fung C, Wong W, et al. *Brevundimonas* bacteremia: Two case reports and literature review. *Scand J Infect Dis* 2004; 36:59-77
- Planes AM, Ramirez A, Fernandez F, et al. *Pseudomonas vesicularis* bacteraemia. *Infection* 1992; 20:367-368
- Oberhelman RA, Humbert JR, Santorelli FW. *Pseudomonas vesicularis* causing bacteremia in a child with sickle cell anemia. *Southern Med J* 1994; 87: 821-822
- Koide M, Miyata T, Nukina M, et al. A strain of *Pseudomonas vesicularis* isolated from shower hose which supports the multiplication of *Legionella*. *J Japanese Asso Infect Dis* 1989; 63: 1160-1164
- Aspinall ST, Graham R. Two sources of contamination of a hydrotherapy pool by environmental organisms. *Journal of Hospital Infection* 1989; 14: 285-92
- Jayasekara N.Y., Heard G.M., Cox J.M., et al. Populations of *Pseudomonas* and related bacteria associated with bottled non-carbonated mineral water. *Food Microbiol* 1998; 15: 167-176
- Gilad J, Borer A, Peled N, et al. Hospital-acquired *Brevundimonas vesicularis* septicemia following open-heart surgery: case report and literature review. *Scand J Infect*

2000; 32: 90-91

8. Vanholder R, Vanhaecke E, Ringoir S. Pseudomonas septicemia due to deficient disinfectant mixing during reuse. Int J Artif Organs 1992; 15: 19-24

9. Li Y, Kawamura Y, Fujiwara N, et al. Sphingomonas yabuuchiae sp.nov. and Brevundimonas nasdae sp.nov, isolated from the Russian space laboratory Mir. Int J Sys Evol Microbiol 2004; 54:819-825

10. Otto LA, Deboo BS, Capers EL, et al. Pseudomonas vesicularis from cervical specimens J Clin Microbiol 1978;

7: 341-345

11. Calegari L, Gezuele E, Torres E, et al. Botryomycosis caused by Pseudomonas vesicularis. Int J of Dermatol 1996: 35:817-818

12. Wang J, Zhang L, Liu Z. The identification and isolation for Pseudomonas vesicularis. 1997; 37: 301-3

13. Sève S, Mohammadi I, Martin O, et al. Brevundimonas vesicularis bacteremia in a patient in aplasia. Presse Med 2004; 33: 172

Author Information

Bobbak Vahid, M.D.

Department of Pulmonary and Critical Care Medicine, Thomas Jefferson University